


Cite this article as: Mosbahi S, Heinisch P-P, Schoenhoff FS, Berger DC. COVID-19-associated aortic arch thrombus. Eur J Cardiothorac Surg 2020; doi:10.1093/ejcts/ezaa304.

COVID-19-associated aortic arch thrombus

Selim Mosbahi^{a,b}, Paul-Philipp Heinisch ^a, Florian S. Schoenhoff^{a,*} and David C. Berger^b

^a Department of Cardiovascular Surgery, Inselspital University Hospital Bern, Bern, Switzerland

^b Department of Intensive Care Medicine, Inselspital University Hospital Bern, Bern, Switzerland

* Corresponding author. Department of Cardiovascular Surgery, Inselspital University Hospital Bern, Freiburgstrasse 18, 3010 Bern, Switzerland. Tel: +41-31-6322111; fax: +41-31-6324443; e-mail: florian.schoenhoff@insel.ch (F.S. Schoenhoff).

Received 9 May 2020; received in revised form 13 July 2020; accepted 18 July 2020

Keywords: COVID-19 • Hypercoagulability • Aortic disease • Thrombus • Aortic arch

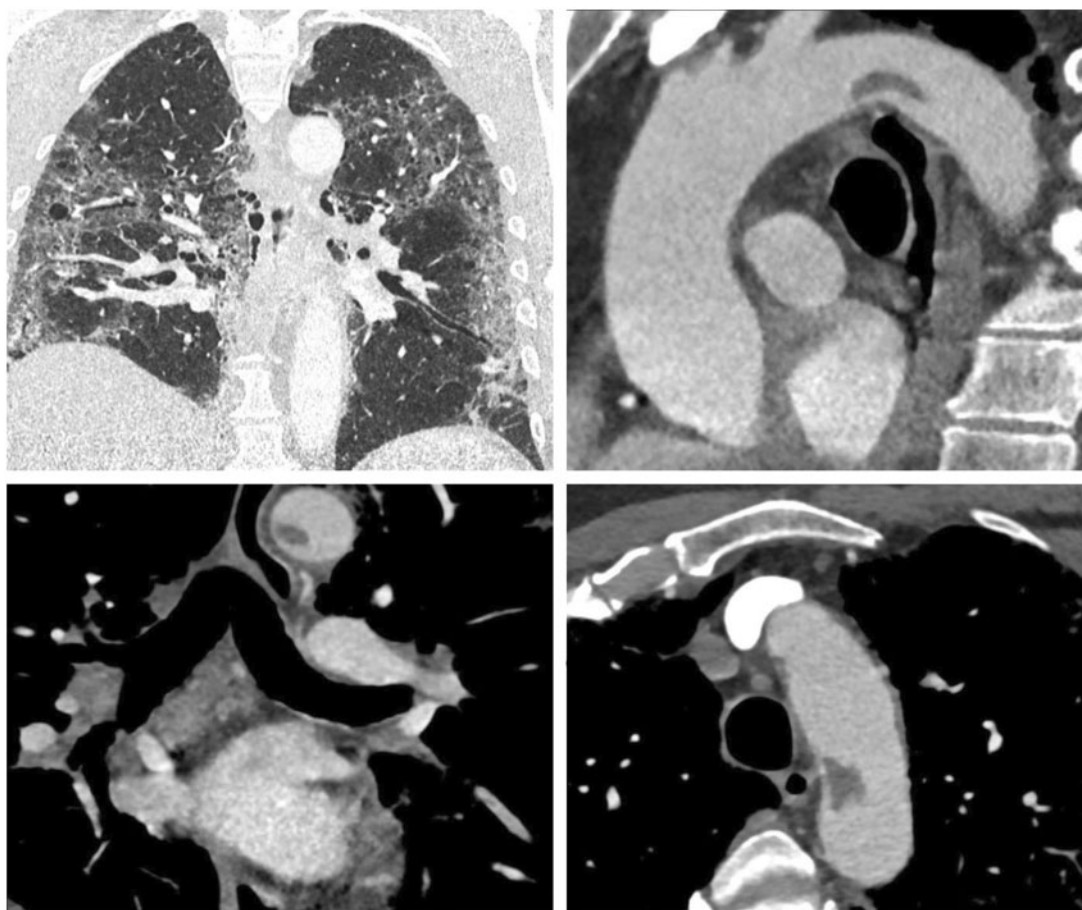


Figure 1: Aortic thrombosis is a rare event that can occur in hypercoagulable state as found in patients with COVID-19. A 58-year-old man presented with COVID-19 respiratory failure and elevated D-dimers (4063 $\mu\text{g/l}$). Computed tomography scanning showed a floating thrombus in the aortic arch. Thrombophilia screening was negative and the aorta free of atherosclerosis. SARS-CoV-2 infection was considered the most likely aetiology.

Reviewer information

European Journal of Cardio-Thoracic Surgery thanks the anonymous reviewers for their contribution to the peer review process of this article.