

MULTIPLE SACCULAR ANEURYSMS OF THE ABDOMINAL AORTA: A CASE REPORT AND SHORT REVIEW OF RISK FACTORS FOR RUPTURE ON CT SCAN

M.S. Durojaye¹, T.O. Adeniyi², and O.A. Alagbe²

1. Department of Radiology, Union Diagnostics & Clinical Services Plc, Lagos, Nigeria.
2. Department of Radiology, LAUTECH Teaching Hospital, Osogbo, Nigeria.

Correspondence:

Dr. O. Alagbe

LAUTECH Teaching Hospital,
Osogbo, Osun State,
Nigeria.

Email: yemalad@yahoo.com
senorrodrigez00@gmail.com
tinudee4life@gmail.com

ABSTRACT

Introduction: Saccular abdominal aortic aneurysms (SAAA) are rare types of abdominal aortic aneurysm. It has a higher risk of rupture, hence must be repaired at smaller diameter. Mortality from rupture of an abdominal aortic aneurysm is high and has been reported to be about 90%.

Case presentation: This is the case of a 37-year-old woman with chronic waist pain and abdominal discomfort. Clinical examinations revealed a pulsating abdominal mass. Doppler ultrasound and abdominopelvic contrast enhanced CT scan showed multiple saccular aneurysms of the infrarenal abdominal aorta. This patient had no identified predisposing factor. She was being worked up for surgery, but eventually died of rupture, the most dreaded complication 3 days prior to surgical repair.

Conclusion: The risk factors for rupture found in this patient were the size and type (saccular) of the aneurysm, intraluminal thrombus in addition to the multiplicity of the aneurysm as well as their adjacent positions; that probably led to arterial wall stress.

Keywords: Saccular abdominal aortic aneurysm, Rupture, Risk factor.

INTRODUCTION

Abdominal aortic aneurysms are focal dilatation of the abdominal aorta greater than 3cm in maximum diameter¹. Aneurysms can be further categorized into fusiform and saccular types. The fusiform and the commoner type often arises in the setting of wall degeneration secondary to atherosclerotic disease. Saccular aneurysms, which are rarely encountered, have a more varied etiology, including aortic infection, degeneration of a penetrating atherosclerotic ulcer, trauma and previous aortic surgery.^{2,3} Generally, risk factors like male gender, advanced age, hypertension, smoking, peripheral artery disease and hypercholesterolemia have been associated with abdominal aortic aneurysms.^{4,5}

emia have been associated with abdominal aortic aneurysms.^{4,5}

Case Report

A 37-year-old woman presented on account of a chronic waist and back pain and abdominal discomfort, which persisted despite the use of analgesics. There was no previous history of trauma or aortic surgery. She is not a known diabetic or hypertensive and has never smoked cigarette. There is no family history of aortic aneurysms. Clinical examination revealed a pulsating mass at the left

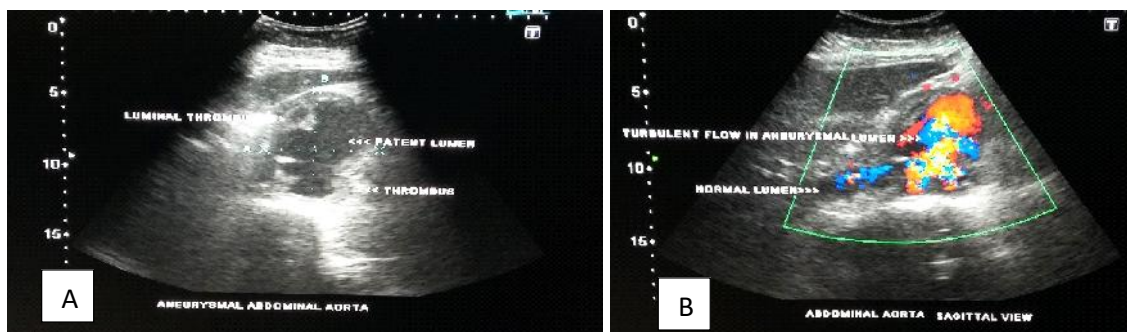


Figure 1: A) 2-dimensional ultrasound image of the abdomen of a 52-year-old female showing the largest aneurysm with a multiple eccentrically located intraluminal thrombi. B) Doppler examination shows the blood flow within the normal lumen of the aorta and turbulent flow in the aneurysmal lumen.

lumbar region. The lipid profile of the patient (total cholesterol, triglycerides, HDL, and LDL) was within normal limits.

Abdominal ultrasound was the first radiological investigation done for the patient being a cost-effective initial imaging modality. This showed multiple aneurysmal pouches that communicated with the lumen of the abdominal aorta below the origin of the renal arteries. Blood flow was demonstrated within the normal lumen and turbulent flow within the aneurysmal lumen on Doppler interrogation (Fig. 1).

Abdominopelvic contrast enhanced CT scan revealed multiple saccular aneurysms of the infrarenal abdominal aorta. Three aneurysms were identified, the largest measuring 66.3mm in diameter, is seen as an out pouch from the anterior wall 2.9cm below the origin of the renal artery and thrombus with a thickness of 22.5mm eccentrically located within the lumen. Two other adjacent but smaller saccular aneurysms measuring 22.4mm and 29.4mm in diameter are on the posterior wall. The IVC is compressed by the aneurysm (Fig. 2).

abdominal aortic aneurysms.⁶ They are commoner in males with a ratio 4:1, seen mostly in the elderly and in settings of atherosclerosis.¹⁷ Aortic aneurysms are uncommon before the sixth decade as Satish reported a prevalence of 0.4% in patients below 51 years.⁸ This index case is a young woman with normal lipid profile and no features of atherosclerosis on imaging. No risk or causative factor was identified in this patient.

Imaging plays a vital role in the diagnosis and follow up of patients with aortic aneurysms. It can also give a clue to the risk or causative factors. US is usually the cost-effective initial imaging modality used in diagnosis of aneurysms as seen in this patient, it is safe and widely available.⁹ Cross sectional images like CT and MRI are integral component in the diagnosis, follow up and management of AAA.¹ In this patient, US was able to demonstrate the aneurysms, the intraluminal thrombus and turbulent flow on Doppler interrogation. The abdominopelvic CT done, better demonstrated the aneurysms as regards their exact locations, proximity to each other and size measurements. It also helped to rule out atherosclerosis in this patient, however, the

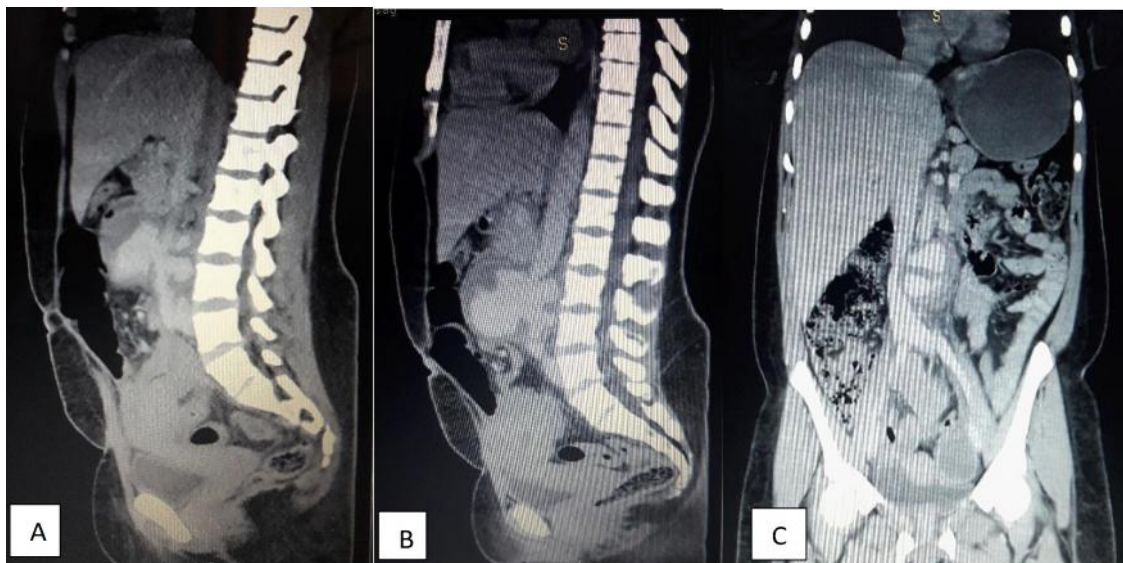

Figure 2: (A&B) Sagittal views of contrast enhanced CT of the abdomen (arterial phase) of a 37-year-old female showing multiple anterior and posterior saccular aneurysms. The eccentric filling defect on the anterior aneurysm is a thrombus. (C) Coronal view shows the compression of the inferior vena cava by an aneurysm

The patient was being worked up for surgery. But, 3 days prior surgery, patient had worsening abdominal pain with episodes of fainting attacks. Unfortunately, patient eventually had a rupture of the aneurysm and died.

DISCUSSION

Saccular aneurysms are rarer than the fusiform type of aortic aneurysm, accounting for about 5% of all

utilization of ionizing radiation by CT is a major concern. Nevertheless, US and CT play a complementary role in the management of patients with AAA.

A previous study stated that aneurysm of the abdominal aorta is a well-known cause of back pain⁶. Our patient had a history of a chronic waist and back pain that was being managed as such. This emphasizes

the importance of abdominopelvic evaluation and imaging in young patients with chronic waist and low back pain.

Mortality from rupture of an abdominal aortic aneurysm was reported to be about 90%.⁹ The natural course of an abdominal aneurysm, if left untreated is to continue to increase in size until it ruptures.¹ Evidence have also shown the relationship between size and rupture tendency of abdominal aneurysms⁹ and the size threshold for repair stated to be 5.5cm.¹⁰ The patient died 3 days prior to surgery. This emphasizes the need for prompt treatment of aortic aneurysm especially when they are large at diagnosis and the saccular type.⁸ Owen *et al.*, has also stated that radiological evidence of AAA erosion into adjacent structure should prompt expedient action to avoid rupture.⁶

Other factors that play a role in the increase risk of rupture of AAA include the rate of expansion, intraluminal thrombus thickness and wall stress.¹⁰ In this patient, the multiplicity of the aneurysms and their location adjacent to each other probably led to arterial wall stress. In addition, the size of the aneurysm, the saccular type and intraluminal thrombus were the other risk factors for the aneurysmal rupture and eventual death.

In conclusion, SAAA may occur even in the absence of identifiable causative or risk factors. Chronic back pain is an established symptom of an abdominal aortic aneurysm. So, patients with low back pain should be screened for abdominal aortic aneurysm. The risk factors for the rupture of an abdominal aortic aneurysm are the multiplicity of the aneurysm, intraluminal thrombus thickness, aneurysm size and type (saccular), rate of expansion, intraluminal thrombus thickness and erosion of an aneurysm into the adjacent structures.

REFERENCES

1. **Clancy K**, Wong J, Spicher A. Abdominal Aortic Aneurysm: A Case Report and Literature Review. *Perm J*. 2019;23:18.218.
2. **Brown SL**, Busuttill RW, Baker JD *et al.* Bacteriologic and surgical determinants of survival in patients with mycotic aneurysms. *J Vasc Surg*. 1984;1(4):541-547.
3. **Coady MA**, Rizzo JA, Hammond GL, *et al.* Penetrating ulcer of the thoracic aorta: what is it? How do we recognize it? How do we manage it? *J Vasc Surg*. 1998;27(6):1006-1015.
4. **Forsdahl SH**, Singh K, Solberg S, Jacobsen BK. Risk factors for abdominal aortic aneurysms: a 7-year prospective study: the Tromso Study, 1994-2001. *Circulation*. 2009;119(16):2202-2208.
5. **Cornuz J**, Sidoti Pinto C, Tevaearai H, Egger M. Risk factors for asymptomatic abdominal aortic aneurysm: systematic review and meta-analysis of population-based screening studies. *European journal of public health*. 2004;14(4):343-349.
6. **Owen RP**, Chan C. Saccular abdominal aortic aneurysm: clear cause of exquisite back pain. *BMJ Case Reports*. 2012;2012:bcr2012006327.
7. **Lee SH**, Chang SA, Jang SY *et al.* Screening for abdominal aortic aneurysm during transthoracic echocardiography in patients with significant coronary artery disease. *Yonsei Med J*. 2015;56(1):38-44.
8. **Muluk SC**, Gertler JP, Brewster DC *et al.* Presentation and patterns of aortic aneurysms in young patients. *Journal of Vascular Surgery*. 1994; 20(6):880-888.
9. **Keisler B**, Carter C. Abdominal aortic aneurysm. *American family physician*. 2015;91(8):538-543.
10. **Gish DS**, Baer JA, Crabtree GS, *et al.* Impending aortic aneurysm rupture - a case report and review of the warning signs. *J Community Hosp Intern Med Perspect*. 2016;6(5):32217.