

Ovarian Hemangioma: a Rare Case Report and Review of the Literature

Katayoun Ziari, Kamyab Alizadeh

Dept. of Pathology, Faculty of Medicine, AJA University of Medical Sciences, Tehran, Iran

KEY WORDS

Ovary
Cavernous Hemangioma
Differential diagnosis

ABSTRACT

Ovarian hemangiomas are benign and rare tumors of female genital tract with less than 60 reported cases in the literature. A 38-yr-old woman was admitted to Be'sat Hospital, Tehran, Iran in 2012, due to severe abdominal pain. Ultrasound evaluation revealed a 6 cm left ovarian cystic mass and serum tumor markers were normal. Then, left salpingo-oophorectomy was performed for the patient. Microscopic examination revealed a follicular cyst and an incidental cavernous hemangioma consisting thin-walled vascular channels filled with blood that lined with flattened endothelial cells. In IHC staining strong immunoreactivity for CD31 and CD34 were seen, finally, the diagnosis of primary ovarian hemangioma, cavernous-type was made. The clinicopathologic presentation of this unusual benign tumor is discussed.

ARTICLE INFO

Received 30 Dec 2014;
Accepted 05 Jan 2015;

©Iran J Pathol. All rights reserved.

Corresponding Information: Kamyab Alizadeh, Department of pathology, Be'sat Hospital, Basij highway, Tehran, Iran Tel: +98-2139954937 Email: Kamyab_alizadeh@yahoo.com

COPYRIGHT © 2016, IRANIAN JOURNAL OF PATHOLOGY. This is an open-access article distributed under the terms of the Creative Commons Attribution-noncommercial 4.0 International License which permits copy and redistribute the material just in noncommercial usages, provided the original work is properly cited.

Introduction

Vascular tumors of female genital tract, especially those arising in the ovary, are very rare. The number of well-documented cases of ovarian hemangioma does not exceed 60 (1-3). These neoplasms occur in both adults and children with the age ranging from infancy to 81 years (1, 4). Most ovarian hemangiomas are discovered as an incidental finding or during autopsy. Other cases are presented with an ovarian mass and acute abdomen due to ovarian torsion or ascites (5).

The aim of present article is to describe the clinicopathologic features and differential

diagnosis of ovarian hemangioma in view of the recent literature.

Case report

A 38-yr-old woman was admitted to Be'sat Hospital, Tehran, Iran in 2012, with an acute onset of lower abdominal pain of 18 hours duration.

The medical history of the patient was unremarkable. Hematological and biochemical tests were within normal limits and serum tumor markers were normal. Ultrasound examination revealed left ovarian cyst measured approximately 6 cm. The patient underwent laparotomy and left

62 Ovarian Hemangioma: a Rare Case Report

salpingo-oophorectomy, and then the specimen was sent for histopathology. The postoperative course was uneventful. Macroscopically, the outer surface of the ovary was smooth and glistening with brown to purplish tint measuring 8x5x3 cm.

On sectioning, the cut surface of the ovary was cystic filled with clear fluid and had a brownish internal surface with maximal diameter 5 cm. In the periphery of the cyst, an area with spongy texture and honeycomb appearance was noted (Measuring 3x1.5x1) (Fig. 1).

Microscopically, most of the ovary was replaced by follicular cyst. In addition, a small vascular lesion was incidentally diagnosed, composed of numerous various in sized dilated

thin walled vascular channels lined by single layer of endothelial cells, separated by connective tissue septa. No atypia, necrosis or increased mitotic figures were noted. In serial sectioned histological specimens, neither teratoma components nor luteinization of the surrounding ovarian stroma was observed. (Fig. 2)

Immunohistochemistry analysis revealed that vascular endothelial markers (CD31 and CD34) were strongly positive for the cells lining the vascular channels, which confirmed the vascular nature of the lesion. Finally, the diagnosis of primary ovarian hemangioma, cavernous-type, was approved.

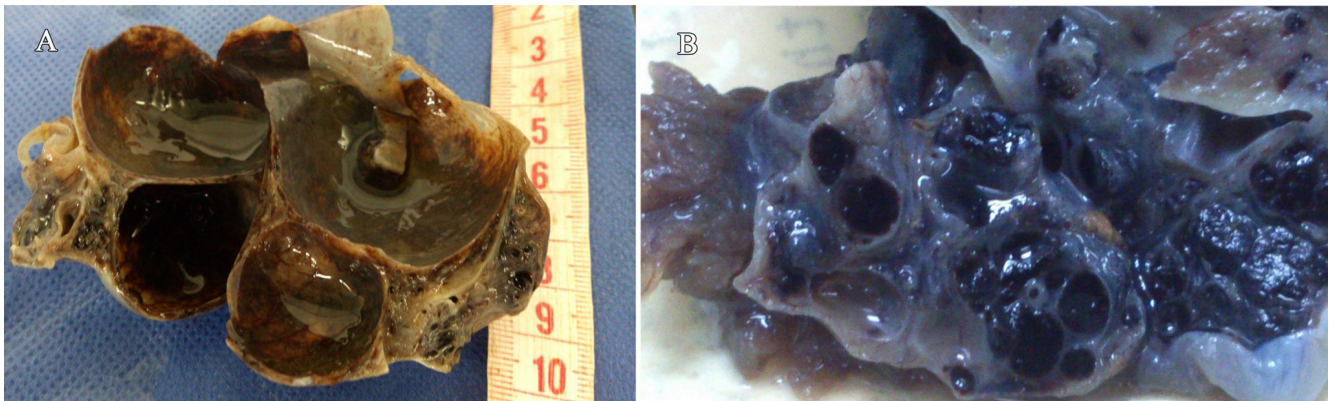


Fig. 1
A) Gross appearance of the specimen B) Gross appearance of hemangioma

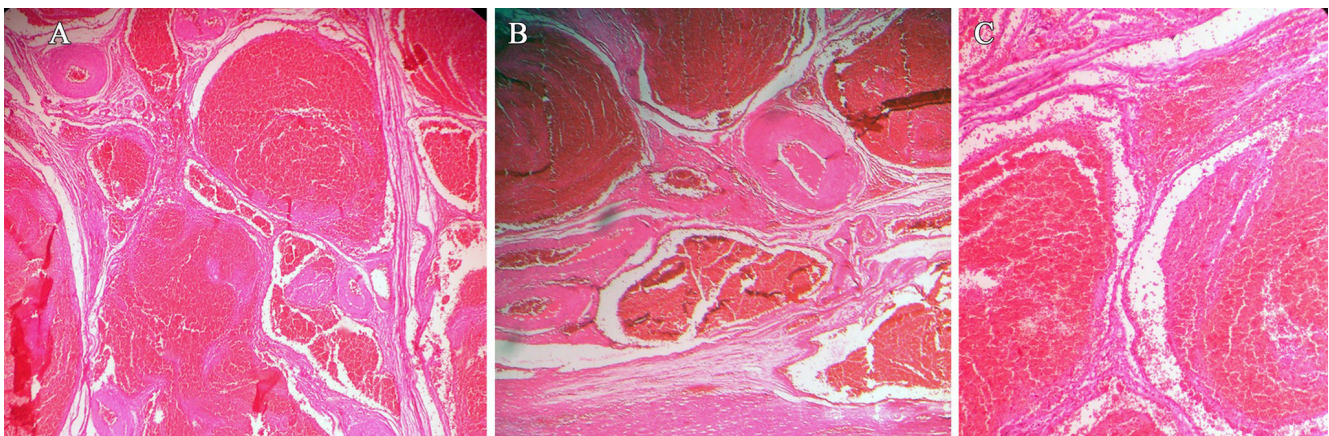


Fig. 2
A) Microscopic reveals multiple thin walled vessels (H&E stain 4x); B) Adjacent area show follicular cyst (H&E stain 4x); C) Vascular channels lined with bland looking epithelium (H&E stain 10x)

Discussion

Vascular tumors of female genital tract, especially those of the ovary, are very rare. The first was reported by Payne in 1869 (6). Cyclic changes in the female genital organs during the reproductive period and the asymptomatic nature and small size of the neoplasm have been attributed to explain its rarity of occurrence (7). The number of well-documented cases seems to be 50 or more but does not exceed 60 (1-3). The age range of this neoplasm is from infancy to 81 yr old (1, 2, 4).

In most patients, ovarian hemangiomas are asymptomatic and present as incidental finding during operation or autopsy, other cases present with an ovarian mass, acute abdomen due to ovarian torsion or ascites (5). Similar to other cases, our patient presented to the hospital with acute abdomen and hemangioma discovered incidentally in microscopic examination. The tumor is usually unilateral but bilateral tumors have been reported (8). In present case, the tumor was unilateral. Although this tumor has been found in different parts of ovaries, the medulla and hilar region are the most common locations of the tumor (8). In our case, the site exactly could not be specified, because the primary shape was destroyed due to presence of a large cyst.

Ovarian hemangiomas have been associated with massive ascites clinically mimicking an ovarian carcinoma (9). Pseudo-meigs' syndrome, stromal luteinization, stromal hyperplasia and thrombocytopenia as complications of ovarian hemangioma have been reported (2, 9). In present report, none of the above findings was seen in further investigations, including CT scan, lab data, and serial histopathologic sections.

The decreased platelet count is regarded as one of the manifestations of Kasabach and Merritt syndrome, particularly in bilateral cases associated with diffuse abdominopelvic hemangiomatosis (2). Ovarian hemangioma coexistence with non-ovarian neoplasm such

as cervical carcinoma, endometrial carcinoma, rectosigmoid carcinoma, and tubal carcinoma has also been reported (3, 10).

The etiology of ovarian hemangiomas is unknown and controversial. These lesions have been considered either as hematomatous malformations or true neoplasm in which pregnancy, other hormonal effects, or infections have been implicated as factors enhancing the growth of hemangioma (11).

Pre-existing stromal luteinization of the ovaries may stimulate the development of an ovarian hemangioma due to the growth stimulatory effects of estrogens in vessels and expression of estrogen receptors by hemangioma (10, 12).

According to another hypothesis, the presence of an expansile ovarian hemangioma induces stromal luteinization; these luteinized stromal cells produce steroid hormones, mainly androgens, which are subsequently converted to estrogens in adipose tissue, that cause unopposed estrogenic stimulation to the endometrium.

The end results of this phenomena may present with postmenopausal or dysfunctional uterine bleeding, male type hair loss and elevated androgen and estradiol levels (12).

Macroscopically, ovarian hemangiomas are usually small and the size of the lesion has been reported from 5 mm to 24 cm in the greatest diameter. Grossly, it is an enlarged ovary with a smooth glistening outer surface showing a red or purplish color. On cut surfaces spongy textured and honeycomb appearance due to multiloculated cystic spaces filled with frank blood or serous fluid are observed. In present case, the greatest diameter of the lesion was 3 cm with spongy texture and honeycomb appearance similar to other cases. Histologically, they demonstrate either a cavernous capillary or mixed type with the cavernous type predominance. Unlike the rest of the body, where capillary hemangiomas are more common (2).

Microscopically, they are composed of

dilated, blood filled, generally thin-walled vessels ranging from small to large size lined by a single layer of flattened endothelial cells. Inflammation, hemorrhage, calcification and hemosiderin deposits in stroma may be present (13).

While the clinical differential diagnoses of ovarian hemangioma include tubo-ovarian mass, twisted ovarian cyst, and chocolate cyst (3), the main pathologic differential diagnosis are vascular proliferation, lymphangioma and monodermal teratoma with vascular component prominence (2).

The most problematic entity that enters into the differential diagnosis is proliferations of dilated hilar blood vessels. To define the lesion as a true hemangioma, proliferating vascular channels with minimal amounts of stroma should form a circumscribed lesion distinct from the remainder of the ovary compared with vascular proliferation, which tend to be smaller and diffuse (14). In the current case, the presence of numerous thin-walled vascular channels having different size separated with minimal amount of stroma lead to primary interpretation hemangioma rather than vascular proliferation. Lymphangioma due to presence of pale eosinophilic homogeneous material within the vascular channels, should be distinguished from hemangioma (15).

Teratomas are included in differential diagnosis due to the prominent vascular component. In such cases careful sampling is important to exclude the presence of other teratomatous elements before diagnosing the tumor as a pure hemangioma (16). In this case, serial sections were examined to rule out monodermal teratoma with angiomatous component.

Sometimes, pre-operative and intra-operative finding can be confusing and tumor may be misdiagnosed as malignancy, which may lead to unnecessary radical surgery. In these situations, hemangioma should be kept in mind as a differential diagnosis of ovarian mass before surgery (14). However, in our case, the clinical and paraclinical data were within normal limit.

The present patient had unilateral cavernous-type ovarian hemangioma tumor, which presented as an acute abdomen due to ovarian cyst and the tumor was discovered as an incidental finding. Calcification, necrosis or stromal hemorrhage and inflammation were not found.

Conclusion

Hemangiomas of the ovary are rare tumor commonly discovered incidentally at autopsy or surgery. Surgical removal of the involved areas is treatment of choice. An ovarian hemangioma can be associated with gynecologic cancer and hemangiomatosis, therefore surgical removal of the involved areas and careful examination of contralateral ovary and endometrium for a possible malignancy and examination of the abdominopelvic for ruling out hemangiomatosis are essential.

References:

1. Mirilas P, Georgiou G, Zevgolis G. Ovarian cavernous hemangioma in an 8-year-old girl. *Eur J Pediatr Surg* 1999;9(2):116-8.
2. Uppal S, Heller DS, Majmudar B. Ovarian hemangioma--report of three cases and review of the literature. *Arch Gynecol Obstet* 2004;270(1):1-5.
3. Gupta R, Singh S, Nigam S, Khurana N. Benign vascular tumors of female genital tract. *Int J Gynecol Cancer* 2006;16(3):1195-200.
4. Rodriguez MA. Hemangioma of the ovary in an 81-year-old woman. *South Med J* 1979;72(4):503-4.
5. Alvarez M, Cerezo L. Ovarian cavernous hemangioma. *Arch Pathol Lab Med* 1986;110(1):77-8.
6. Payne J. Vascular tumors of the liver, suprarenal capsules and other organs. *Trans Path Soc London* 1869;20:203.
7. Pethe VV, Chitale SV, Godbole RN, Bidaye SV. Hemangioma of the ovary--a case report and review of literature. *Indian J Pathol Microbiol* 1991;34(4):290-2.
8. Talerman A. Hemangiomas of the ovary and the uterine cervix. *Obstetrics & Gynecology* 1967;30(1):108-

13.

9. Gehrig PA, Fowler WC, Jr., Lininger RA. Ovarian capillary hemangioma presenting as an adnexal mass with massive ascites and elevated CA-125. *Gynecol Oncol* 2000;76(1):130-2.

10. Miliaras D, Papaemmanouil S, Blatzas G. Ovarian capillary hemangioma and stromal luteinization: a case study with hormonal receptor evaluation. *Eur J Gynaecol Oncol* 2001;22(5):369-71.

11. DiOrio J, Jr., Lowe LC. Hemangioma of the ovary in pregnancy: a case report. *J Reprod Med* 1980;24(5):232-4.

12. Carder PJ, Goulesbrough DR. Ovarian haemangiomas and stromal luteinization. *Histopathology* 1995;26(6):585-6.

13. Kim MY, Rha SE, Oh SN, Lee YJ, Jung ES, Byun JY. Case report: Ovarian cavernous haemangioma presenting as a heavily calcified adnexal mass. *Br J Radiol*

2008;81(971):e269-71.

14. Mitra B, Sengupta S, Rai A, Mehta J, Quader AR, Roy S, et al. Ovarian haemangioma: A rare case report. *Int J Surg Case Rep* 2013;4(11):981-4.

15. Feuerstein IM, Aronson BL, McCarthy EF. Bilateral ovarian cystic teratomata mimicking bilateral pure ovarian hemangiomas: case report. *Int J Gynecol Pathol* 1984;3(4):393-7.

16. Akbulut M, Bir F, Colakoglu N, Soysal ME, Duzcan SE. Ovarian hemangioma occurring synchronously with serous papillary carcinoma of the ovary and benign endometrial polyp. *Ann Saudi Med* 2008;28(2):128-31.

How to cite this article:

Ziari K, Alizadeh K. Ovarian Hemangioma: a Rare Case Report and Review of the Literature. *Iran J Pathol* 2016; 11(1): 61 - 65.