

# A Case Report and Literature Review of Midtrimester Termination of Pregnancy Complicated by Placenta Previa and Placenta Accreta

Satoko Matsuzaki, MD<sup>1</sup> Shinya Matsuzaki, MD, PhD<sup>1</sup> Yutaka Ueda, MD, PhD<sup>1</sup> Yusuke Tanaka, MD<sup>1</sup>  
Mamoru Kakuda, MD<sup>1</sup> Takeshi Kanagawa, MD<sup>1</sup> Tadashi Kimura, MD, PhD<sup>1</sup>

<sup>1</sup>Department of Obstetrics and Gynecology, Osaka University Graduate School of Medicine, Osaka, Japan

Address for correspondence Shinya Matsuzaki, MD, PhD, Department of Obstetrics and Gynecology, Osaka University Graduate School of Medicine, 2-2 Yamadaoka, Suita, Osaka 565-0871, Japan (e-mail: zacky@gyne.med.osaka-u.ac.jp).

Am J Perinatol Rep 2015;5:e6–e11.

## Abstract

**Objective** Concurrent placenta previa and placenta accreta increase the risk of massive obstetric hemorrhage. Despite extensive research on the management of placenta previa (including placenta accreta, increta, and percreta), the number and quality of previous studies are limited. We present a case of placenta accreta requiring an induced second-trimester abortion because of premature rupture of the membranes (PROM).

**Study Design** Case report and review of the literature.

**Results** A 41-year-old female presented at 20 weeks of gestation with placenta previa and PROM. Ultrasonography revealed placenta accreta with multiple placental lacunae. She then developed massive hemorrhaging just prior to a planned termination of pregnancy. We performed a hysterectomy with the intent of preserving life because of the failure of the placenta to detach and blood loss totaling 4,500 mL.

**Conclusion** Previous studies suggest that second-trimester pregnancy terminations in cases of placenta previa which are not complicated with placenta accreta do not have a particularly high risk of hemorrhage. However, together with our case, the literature suggests that placenta previa complicated with placenta accreta presents a significant risk of hemorrhage both during delivery and intraoperatively. Further reports are needed to evaluate the most appropriate treatment options.

## Keywords

- ▶ placenta previa
- ▶ placenta accreta
- ▶ midtrimester termination
- ▶ cesarean hysterectomy

Placenta previa is an obstetric complication in which the placenta is attached over the lower uterine segment. When associated with placenta accreta, the risk of massive obstetric hemorrhage is increased.<sup>1</sup> The established risk factors for placenta accreta are prior cesarean delivery and placenta previa.<sup>1</sup> Despite extensive research on the management of placenta previa (including placenta accreta, increta, and percreta),<sup>2–6</sup> the number and quality of studies are limited. Moreover, termination of pregnancy (TOP) due to placenta

accreta in the second trimester is rare, and the management of this condition is both controversial and rarely reported. We present a case of placenta accreta requiring a complicated induced second-trimester abortion because of premature rupture of the membranes (PROMs). We terminated the pregnancy using intravaginal gemeprost. During the termination, massive hemorrhaging occurred, necessitating subsequent hysterectomy. Here, we discuss the case and present a review of the related literature.

received  
August 2, 2014  
accepted  
September 11, 2014  
published online  
December 18, 2014

DOI <http://dx.doi.org/10.1055/s-0034-1395992>.  
ISSN 2157-6998.

Copyright © 2015 by Thieme Medical Publishers, Inc., 333 Seventh Avenue, New York, NY 10001, USA.  
Tel: +1(212) 584-4662.

License terms

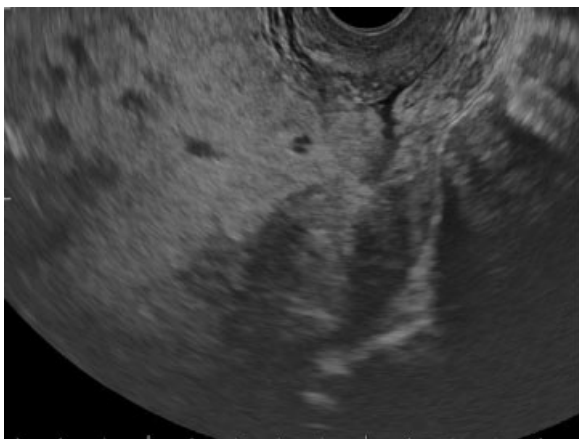


## Case Presentation

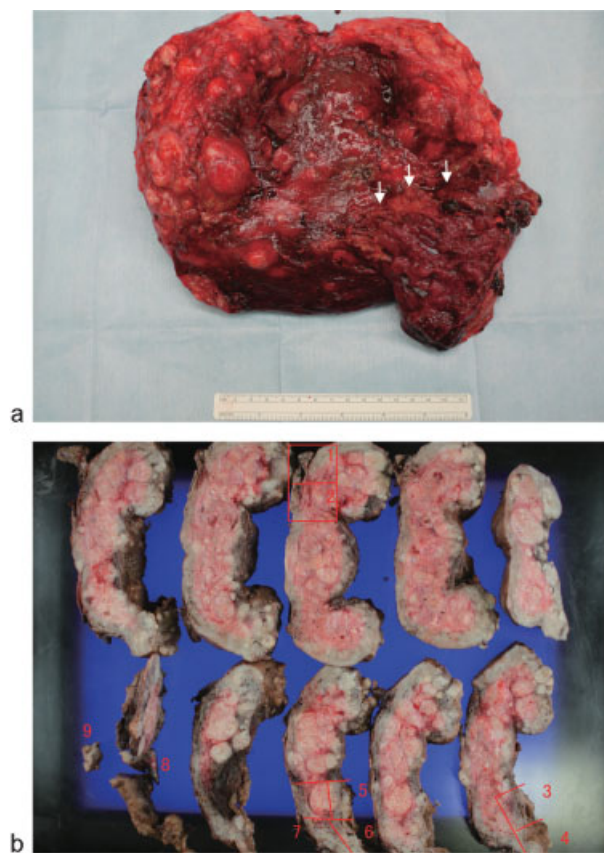
A 41-year-old female (gravida 2, para 1) at 20 weeks of gestation was referred to our hospital from a private clinic because of placenta previa complicated by PROM. The patient had a history of uterine surgical intervention with one cesarean delivery and two myomectomies. The placenta previa was considered complete, as the placenta was attached deep in the anterior wall, totally embedded within the lower uterine segment. Upon ultrasonography, we suspected multiple small myomas and placenta accreta on the basis of the presence of multiple placental lacunae (→ Fig. 1).

The patient opted for TOP because of the poor neonatal prognosis associated with second-trimester PROM and a desire to preserve her uterus. We then counseled the patient on the risk of TOP complicated by placenta accreta. The patient was offered either conventional TOP using intra-vaginal gemeprost or feticide. She chose the former, and informed consent was obtained. Prophylactic uterine embolization before TOP was also declined. During the TOP, the patient developed severe hemorrhaging with a blood loss of approximately 850 mL. After further 30 minutes, blood loss increased to 1,200 mL. Her cervix was dilated 1 cm, and continuation of TOP was considered too dangerous. Therefore, we decided to perform cesarean delivery via a vertical uterine incision and delivered a stillborn male weighing 190 g. Massive hemorrhaging then occurred, and the placenta did not spontaneously deliver because of the abnormal adherence. At this point, the total blood loss from the placental site was estimated to be 2,000 mL, and we decided that the safest course of action was to perform a hysterectomy, which was completed without further complications. The excised uterus revealed multiple myomas and an abnormal circumferential adhesion between the placenta and the uterine wall, suggesting placenta accreta. Later, histopathological analysis confirmed the diagnosis of placenta accreta associated with multiple myomas (→ Fig. 2a and 2b).

The total blood loss was approximately 4,500 mL (preoperative, 1,350 mL; intraoperative, 3,150 mL). Intraoperatively,



**Fig. 1** A vaginal ultrasound revealed complete placenta previa covering the internal os in the 20th week of gestation. Multiple placental lacunae were observed.



**Fig. 2** (a) Histopathological study of the placenta that failed to deliver spontaneously following cesarean section. The surgery was converted to open hysterectomy. The white arrow indicates the abnormal adherence between the uterine myometrium and placenta. (b) Histopathological analysis of the placenta at 20 weeks of gestation, confirming placenta previa complicated by placenta accreta in the sections numbered 3–6.

the patient received infusions and red blood cell transfusions totaling 3,000 mL and 2,160 mL, respectively. Postoperatively, the patient had an uncomplicated recovery and was discharged 7 days after the operation in good health.

## Discussion

Several studies have reported an association between the number of prior cesarean deliveries and the incidence of placenta accreta,<sup>1</sup> with placenta previa being the most serious risk factor for placenta accreta.<sup>6</sup> In our case, the patient had a history of cesarean delivery and two myomectomies, and she was considered to be at high risk for placenta accreta.<sup>6</sup> Immediate delivery was necessary in our case, which precluded the use of magnetic resonance imaging (MRI) and limited the use of ultrasonography for placental assessment. The diagnosis was complete placenta previa with evidence of placental lacunae. One study reported that complete previa is associated with a higher incidence of placenta accreta compared with incomplete previa.<sup>7</sup> Another study reported that transvaginal sonographic findings of intraplacental lacunae in patients with complete previa and a history of cesarean section are useful predictors of an adherent

placenta.<sup>8</sup> Although placenta accreta is difficult to diagnose, doing so accurately is crucial for improving maternal outcomes. To date, several reports have described ultrasonography and MRI<sup>9–12</sup> as the preferred diagnostic methods when placenta accreta is suspected.

The best method for second-trimester TOP is still unknown, and determining the appropriate management is difficult. Only small studies have reported on second-trimester TOPs complicated by placenta previa and placenta accreta, and we found no systematic literature review on this topic. Therefore, we performed a PubMed search using the key words “placenta previa” and “termination,” “abortion,” “second trimester,” or “accreta” and excluded “fetal death.” The search was limited to the English literature between 1990 and 2014, from 12 to 23 weeks of gestation, and led to 11 reports, which are summarized in ►Table 1.<sup>13–23</sup>

Thomas et al compared 23 patients with placenta previa and 108 patients with it that required a second-trimester TOP by dilatation and evacuation at 13 to 24 weeks of gestation and observed no clinically significant differences in outcomes.<sup>13</sup> Similar results were reported in other studies and also for TOP using gemeprost.<sup>17,20</sup> Another study reported the efficacy of induction with and without feticide among patients ultrasonographically diagnosed with complete placenta previa.<sup>19</sup> All patients underwent induction of labor by gemeprost, sulprostone, and misoprostol; nine underwent TOP without feticide and six underwent TOP with feticide. The authors of the study concluded that performing feticide before inducing labor for TOP in the second and third trimester may decrease maternal blood loss where the placenta previa covered the internal os. A similar report was published concerning mifepristone- and misoprostol-induced midtrimester TOP with preinduction feticide in patients with a diagnosis of complete placenta previa.<sup>22</sup> They concluded that feticide effectively decreases placenta previa-related bleeding during medical midtrimester TOP. However, these studies investigated small numbers of patients, and further investigation is needed to reveal the usefulness of feticide before the induction of labor.

We identified four reports suggesting an increased risk of massive hemorrhage during TOP in cases of placenta previa complicated by placenta accreta.<sup>14–16,21</sup> Rashbaum et al investigated 16,827 cases of second-trimester dilatation and evacuation, of which seven required hysterectomy because of massive hemorrhage; all the patients had placenta accreta and five cases were complicated with placenta previa.<sup>14</sup> Although a detailed analysis was not possible, massive bleeding was observed in the cases of placenta previa with accreta, and they concluded that placenta accreta can be a potential complicating factor in patients undergoing dilatation and evacuation in the second trimester. Borgatta et al reported eight cases of placenta accreta in the second trimester.<sup>15</sup> In all cases, prophylactic uterine artery embolization and subsequent dilatation and evacuation were performed. One case had placenta previa with placenta increta, which resulted in blood loss of approximately 6,000 mL and required a subsequent hysterectomy. This case demonstrates the high risk of bleeding associated with TOP in cases of placenta

previa with increta. In four out of eight cases, clinically insignificant bleeding was observed, and the author concluded that preoperative prophylactic catheterization or embolization might be effective. Cheng et al reported six cases of placenta accreta, of which four also had placenta previa.<sup>16</sup> If placenta accreta was suspected, surgeons performed prophylactic uterine artery embolization and subsequent hysterectomy, reporting an approximate mean blood loss of 1,700 mL during the hysterectomy. They concluded that prophylactic selective arterial embolization was effective and safe for the anticipated high morbidity or mortality during obstetric surgery. However, severe bleeding was observed irrespective of prophylactic uterine artery embolization and scheduled hysterectomy. Further reports are needed to establish the efficacy of this treatment. Steinauer et al conducted a retrospective study of uterine artery embolization for post-abortion hemorrhage among 42 patients.<sup>21</sup> In this report, seven cases had abnormal placentation, of which 4 cases had placenta previa complicated by placenta accreta and three needed subsequent hysterectomy due to failure to achieve hemostasis via uterine artery embolization. Because this was a retrospective study, an accurate estimation of the risk of placenta previa with accreta could not be determined; however, the report suggested the risks associated with TOP in cases of placenta previa with accreta.

The retrospective reports described above focused on high-risk patients requiring surgical treatment such as hysterectomy due to massive hemorrhaging during TOP for placenta previa. However, these reports also suggest that patients with suspected placenta accreta have an increased likelihood of requiring subsequent medical or surgical treatment, including hysterectomy. The case presented herein had complete placenta previa and suspected placenta accreta and was considered at high risk for hemorrhage. She requested TOP because of PROM at 20 weeks of gestation. Although she was offered feticide before the induction of labor, she elected to not receive it. Induction by gemeprost seems to be safe for TOP in cases of placenta previa without accreta.<sup>20</sup> However, massive hemorrhage was observed during the gemeprost induction in the present case. Ours is the first reported case in which induction by gemeprost was converted to cesarean hysterectomy. The reason may have been the presence of placenta previa with placenta accreta. The patient wanted to preserve her uterus, and, therefore, the fetus was delivered by vertical uterine incision. Subsequent massive hemorrhaging was observed from the placental site and a hysterectomy was needed. This case, together with the results of the previous studies described above, indicates that obstetricians should recognize the risk of cesarean delivery in the presence of placenta previa with accreta even during the second trimester. If the obstetrician encounters massive bleeding during TOP in a patient with placenta previa and placenta accreta and the patient does not wish to preserve the uterus, en bloc removal of the uterus with the fetus in situ might be suitable.

In summary, we presented the case of a patient with placenta previa and placenta accreta who developed severe hemorrhaging during TOP that ultimately necessitated hysterectomy. Previous studies suggest that second-trimester

**Table 1** Results of systematic literature review of second-trimester termination of pregnancy (TOP) in cases of placenta previa complicated by placenta accreta

First author	Year (Ref. no.)	Cases of previa	Cases of accreta	Mean age (y)	Gestational age (wk)	Method	Blood loss	Complications
Thomas	1994 <sup>13</sup>	23 cases	None	26.3	17.0 wk (mean)	D&E	small	not increased
Analyzed second trimester termination at 13–24 wk gestation. Compared patients with or without placenta previa.								
Conclusion: Patients with placenta previa lost an average of 21 mL more blood than those without previa.								
Rashbaum	1995 <sup>14</sup>	5 cases	5 cases	28.7	19.1 wk (mean)	D&E	massive	hysterectomy performed in all cases
16,827 second trimester D&E procedures were identified. All cases that resulted in hysterectomy for uncontrolled hemorrhage were reviewed.								
Conclusion: Placenta accreta can be a potential complicating factor in patients undergoing D&E in the second trimester.								
Borgatta	2001 <sup>15</sup>	1 of 8 cases	8 cases (1 case was described as placenta previa)	32.8	19.5 wk (mean)	D&E	4 case: no clinical significant bleeding 4 case: 6,000 mL, 3,000 mL, 800 mL, and 2,000 mL	4 case: none 4 case: all cases needed the hysterectomy
Prophylactic uterine artery embolization was performed for 8 women who were at high risk of hemorrhage from placenta accreta to decrease the bleeding.								
The author collected case reports of embolization after spontaneous or induced abortion from oral presentations and from members of the National Abortion Federation.								
Conclusion: There may be a role for prophylactic catheterization or embolization when there is a risk of severe hemorrhage.								
Cheng	2003 <sup>16</sup>	4 cases	6 cases (2 cases were without placenta previa)	27	20.3 wk (mean)	hysterectomy	1,770 mL (mean)	none
Prophylactic uterine artery embolization and subsequent hysterectomy was performed to decrease the bleeding.								
The patient who had abnormal placentation that was diagnosed by antepartum ultrasonography, prophylactic uterine artery embolization and subsequent hysterectomy was performed.								
Conclusion: Our experience also confirms the effectiveness and safety of prophylactic selective arterial embolization for anticipated high morbidity or mortality of obstetric surgery.								
Halperin	2003 <sup>17</sup>	8 cases	none	27	21.2 wk (mean)	D&E	small	not increased
The records of 306 consecutive women undergoing pregnancy termination at 19–24 weeks' gestation were reviewed and divided into those with and without complete placenta previa based on an ultrasound examination before the procedure.								
Conclusion: Late midtrimester pregnancy termination with placenta previa appears to be safe and apparently does not increase maternal morbidity as compared with the patients without placenta previa.								
Yamada T	2003 <sup>18</sup>	2 cases	none	28	18.0 (mean)	cesarean delivery	~1,000 mL	none
Case reports of second trimester cesarean deliveries with increased antepartum bleeding								
Conclusion: Terminating the pregnancy at the time of worsening of symptoms even in the second trimester should be considered as an option in the treatment of placenta previa.								
Ruano	2004 <sup>19</sup>	9 cases	none	32.4	23.2 wk (mean)	induction of labor with previous feticide	the mean decreased Hb was 2.5 g/dL	4 cases: transfusion, 1 case: hysterectomy
		6 cases	none	33	21.3 wk (mean)	induction of labor without previous feticide	the mean decreased Hb was 1.0 g/dL	no transfusion and hysterectomy
		total 15 cases						
This study included some cases over 24 weeks of gestation. Feticide was performed to decrease the bleeding.								
Retrospective study. The patients with second and third trimester termination of pregnancy with placenta previa were reviewed and patients with or without the feticide before the induction of labor were compared								
Conclusion: In cases with complete placenta previa, second or third trimester termination of pregnancy is feasible. It carries a substantial risk of hemorrhage that may be decreased by preinduction feticide.								

(Continued)



**Table 1** (Continued)

First author	Year (Ref. no.)	Cases of previa	Cases of accreta	Mean age (y)	Gestational age (wk)	Method	Blood loss	Complications
Nakayama	2007 <sup>20</sup>	7 cases	none	27.4	17.4 wk (mean)	gemeprost	344 mL (mean)	1 case needed the transfusion.
		4 cases	none	29.5	15.5 wk (mean)	D&E	178 mL (mean)	none
		total 11 cases						
Retrospective study. The patients with second trimester termination of pregnancy with placenta previa were reviewed. Compared with induction of labor by gemeprost and D&E.								
Conclusion: The use of gemeprost for second trimester pregnancy termination in women with placenta previa seems to be relatively safe and does not increase intraoperative blood loss in the majority of cases.								
Steinauer	2008 <sup>21</sup>	4 of 42 cases	7 of 42 cases (4 of 7 cases were placenta previa)	27.8	20.8 wk (mean)	all cases: D&E	2,475 mL (mean)	1 case: femoral embolus
							300–3200 mL (range)	3 cases: hysterectomy
Retrospective study. Forty-two women were identified who had post abortion uterine artery embolization for hemorrhage. Seven cases were identified with abnormal placentation. Four of seven cases were identified with placenta previa.								
Conclusion: When counseling patients with suspected placenta accreta about the efficacy of uterine artery embolization, they should be informed about the risk of requiring subsequent medical or surgical treatment.								
Borras	2010 <sup>22</sup>	2 cases	none	34.5	21.5 wk (mean)	misoprostol	no significant clinical bleeding	none
Preinduction feticide was performed to decrease the bleeding.								
Two case reports about the mifepristone-misoprostol midtrimester TOP with a diagnosis of complete placenta previa.								
Conclusion: This report is relevant considering that this regimen is the most widely used and generally reported as the safest and most effective medical midtrimester TOP method.								
Lathrop	2012 <sup>23</sup>	1 case	1 case	32	18 wk	not described	massive	transfusion and UAE was performed
Preinduction feticide was performed to decrease the bleeding.								
Conclusion: Not described detail of a case. The patient needed the uterine artery embolization to control the postabortal hemorrhage								
Our case	2014	1 case	1 case	41	20 wk	gemeprost	4,500 mL	1 case: hysterectomy
Case report about the TOP in placenta previa with placenta accreta.								
Conclusion: Induction of labor by gemeprost was attempted. However, massive bleeding was observed during the TOP. This might be caused of the placenta previa with accreta.								
The obstetrician should take care the massive bleeding for the cesarean delivery even though in second trimester in the presence of placenta previa and placenta accreta.								

Abbreviations: D&E, dilatation and evacuation; UAE, uterine artery embolization.

TOP in cases of placenta previa which are not complicated with placenta accreta does not carry a particularly high risk of hemorrhage. However, together with our case, the relevant literature suggests that placenta previa complicated with placenta accreta is associated with a significant risk of hemorrhage both during delivery and obstetric surgery. Feticide, prophylactic uterine artery embolization, and scheduled hysterectomy without TOP may decrease the bleeding in such cases. However, reports concerning TOP in cases with placenta previa and accreta are few, and further studies are needed to evaluate the most appropriate treatment options.

#### Acknowledgments

We thank A. Yagi and K. Sakiyama for secretarial assistance.

#### Conflict of Interest

The authors declare no conflicts of interest or relevant financial relationships related to this study.

#### References

- Silver RM, Landon MB, Rouse DJ, et al; National Institute of Child Health and Human Development Maternal-Fetal Medicine Units Network. Maternal morbidity associated with multiple repeat cesarean deliveries. *Obstet Gynecol* 2006;107(6):1226–1232
- Oyelese Y, Smulian JC. Placenta previa, placenta accreta, and vasa previa. *Obstet Gynecol* 2006;107(4):927–941
- Rao KP, Belogolovkin V, Yankowitz J, Spinnato JA II. Abnormal placentation: evidence-based diagnosis and management of placenta previa, placenta accreta, and vasa previa. *Obstet Gynecol Surv* 2012;67(8):503–519
- Robinson BK, Grobman WA. Effectiveness of timing strategies for delivery of individuals with placenta previa and accreta. *Obstet Gynecol* 2010;116(4):835–842
- Matsuzaki S, Yoshino K, Kajimoto E, et al. Successful management of placenta percreta by cesarean hysterectomy with transverse uterine fundal incision. *Int J Reprod Contracept Obstet Gynecol*. 2014;3(2):447–449
- Belfort MA; Publications Committee, Society for Maternal-Fetal Medicine. Placenta accreta. *Am J Obstet Gynecol* 2010;203(5):430–439
- Tuzovic L. Complete versus incomplete placenta previa and obstetric outcome. *Int J Gynaecol Obstet* 2006;93(2):110–117
- Yang JI, Lim YK, Kim HS, Chang KH, Lee JP, Ryu HS. Sonographic findings of placental lacunae and the prediction of adherent placenta in women with placenta previa totalis and prior Cesarean section. *Ultrasound Obstet Gynecol* 2006;28(2):178–182
- Levine D, Hulka CA, Ludmir J, Li W, Edelman RR. Placenta accreta: evaluation with color Doppler US, power Doppler US, and MR imaging. *Radiology* 1997;205(3):773–776
- Comstock CH, Love JJ Jr, Bronsteen RA, et al. Sonographic detection of placenta accreta in the second and third trimesters of pregnancy. *Am J Obstet Gynecol* 2004;190(4):1135–1140
- Lam G, Kuller J, McMahon M. Use of magnetic resonance imaging and ultrasound in the antenatal diagnosis of placenta accreta. *J Soc Gynecol Investig* 2002;9(1):37–40
- Warshak CR, Eskander R, Hull AD, et al. Accuracy of ultrasonography and magnetic resonance imaging in the diagnosis of placenta accreta. *Obstet Gynecol* 2006;108(3, Pt 1):573–581
- Thomas AG, Alvarez M, Friedman F Jr, Brodman ML, Kim J, Lockwood C. The effect of placenta previa on blood loss in second-trimester pregnancy termination. *Obstet Gynecol* 1994;84(1):58–60
- Rashbaum WK, Gates EJ, Jones J, Goldman B, Morris A, Lyman WD. Placenta accreta encountered during dilation and evacuation in the second trimester. *Obstet Gynecol* 1995;85(5, Pt 1):701–703
- Borgatta L, Chen AY, Reid SK, Stubblefield PG, Christensen DD, Rashbaum WK. Pelvic embolization for treatment of hemorrhage related to spontaneous and induced abortion. *Am J Obstet Gynecol* 2001;185(3):530–536
- Cheng YY, Hwang JI, Hung SW, et al. Angiographic embolization for emergent and prophylactic management of obstetric hemorrhage: a four-year experience. *J Chin Med Assoc* 2003;66(12):727–734
- Halperin R, Vaknin Z, Langer R, Bukovsky I, Schneider D. Late midtrimester pregnancy termination in the presence of placenta previa. *J Reprod Med* 2003;48(3):175–178
- Yamada T, Kasamatsu H, Mori H. Case report: Two cases of placenta previa terminated at 18 weeks' gestation. *Kobe J Med Sci* 2003;49(3–4):51–54
- Ruano R, Dumez Y, Cabrol D, Dommergues M. Second- and third-trimester therapeutic terminations of pregnancy in cases with complete placenta previa—does feticide decrease postdelivery maternal hemorrhage? *Fetal Diagn Ther* 2004;19(6):475–478
- Nakayama D, Masuzaki H, Miura K, Hiraki K, Yoshimura S, Ishimaru T. Effect of placenta previa on blood loss in second-trimester abortion by labor induction using gemeprost. *Contraception* 2007;75(3):238–240
- Steinauer JE, Diedrich JT, Wilson MW, Darney PD, Vargas JE, Drey EA. Uterine artery embolization in postabortion hemorrhage. *Obstet Gynecol* 2008;111(4):881–889
- Borrás A, Gómez O, Sanz M, Martínez JM, Puerto B. Feticide followed by mifepristone-misoprostol regimen for midtrimester termination of pregnancy in two cases of complete placenta previa. *Fetal Diagn Ther* 2010;28(2):114–116
- Lathrop E, Schreiber C. Controversies in family planning: management of second-trimester pregnancy terminations complicated by placenta accreta. *Contraception* 2012;85(1):5–8