

Long-term Experience with the Björk-Shiley Monostrut Tilting Disc Valve

The Björk-Shiley Monostrut valve is tilting disc mechanical valve prosthesis. This study was designed to present the long-term outcome of our experience. One hundred and thirty-seven Björk-Shiley Monostrut valves were implanted in 101 consecutive patients from November 1983 to February 1990. There were 60 male and 41 female with mean age of 34.5 yr at the time of operation. Fifty-nine patients underwent single valve replacement, 38 had double valve, and 4 had triple valve replacement. There were six in-hospital deaths (5.9%): three from cardiopulmonary bypass weaning failure and one each from septic shock, sudden cardiac arrest, and uncontrollable bleeding. Mean duration of follow-up was 181.2 ± 76.2 months. Overall survival was 86.2% at 15 yr and 83.1% at 20 yr. Patients with mitral valve replacement had 93.5% and 90.2% cumulative survival at 10 and 15 yr, respectively, while patients with aortic valve replacement had 91.1% and 86.5% cumulative survival at 10 and 15 yr. Two groups had no significant difference in survival. Double valve replacement patients had 92.2% and 84.0% survival at 10 and 15 yr, respectively. There were no significant differences in survival between the single and double valve replacement groups. Freedom from thromboembolism was noted in: 97.8%, 97.8%, 96.4% and 87.8% at 5, 10, 15 and 20 yr, respectively. Absence of endocarditis was noted in 98.6% and 94.8% at 15 and 20 yr. Absence of reoperation was 92.5% at 20 yr. In conclusion, the Björk-Shiley Monostrut valve is reliable, with a similar incidence of valve-related morbidity as in other mechanical valves.

Key Words : *Björk-Shiley Monostrut Valve; Mechanical Valve; Long-term Result*

Hyuk Ahn, Kyung-Hwan Kim,
Dong Jin Kim, Dong Seop Jeong

Department of Thoracic and Cardiovascular Surgery,
Seoul National University Hospital, Seoul National
University College of Medicine, Seoul, Korea

Received : 21 December 2006
Accepted : 4 April 2007

Address for correspondence

Kyung-Hwan Kim, M.D.
Department of Thoracic and Cardiovascular Surgery,
Seoul National University Hospital, Seoul National
University College of Medicine, 28 Yeongseon-dong,
Jongno-gu, Seoul 110-744, Korea
Tel : +82.2-2072-3971, Fax : +82.2-765-7117
E-mail : kkh726@snu.ac.kr

INTRODUCTION

The Björk-Shiley Monostrut valve is tilting disc mechanical valve prosthesis. The original Björk-Shiley valve was referred to as the Delrin Björk valve that was developed after the ball and horizontal disc valves. Many modifications have followed including the pyrolite carbon leaflet, single inflow strut, tantalum strut, and the convexo-concave valve (1, 2). The convexo-concave valve had defects of the outflow strut fracture; the monostrut valve was introduced to prevent outflow strut fracture (3). We have used the Björk-Shiley monostrut valve for 14 yr since 1977. Here we present our data on the long-term outcomes of our experience with this valve.

MATERIALS AND METHODS

Between 1970 and 1990, about 170 Björk-Shiley Monostrut valves were used in 139 patients at our hospital. Here we present the long-term surgical outcomes of 101 patients whose medical records were available for evaluation. Between November 1983 and February 1990, 101 patients underwent valve

replacement using the Björk-Shiley Monostrut valve. There were 60 male patients and 41 females with a mean age of 34.5 ± 10.4 (range, 10-59 yr). Among them, 72 mitral valves, 63 aortic valves (7 underwent Bentall operation), and 2 tricuspid valves were replaced; overall, 137 Björk-Shiley Monostrut valves were used for valve replacement. Fifty-nine patients underwent single valve replacement (35 mitral and 24 aortic), 38 had double valve (mitral with aortic), and 4 had triple valve replacement. Out of 42 multiple valve replacements, 6 patients had other valvular prostheses: St. Jude in 3 (1 in aortic and 2 in tricuspid position), Ionescu-Shiley in 2, and Hancock in 1 (mitral position). For the mitral valve replacements we used a 23 mm sized valve in one patient, 27 mm in four, 29 mm in 15, 31 mm in 38, and 33 mm in 14. For the aortic valve replacements, we used 19 mm-sized valve in two patients, 21 mm in 13, 23 mm in 19, 25 mm in 19, 27 mm in five, 29 mm in four, and 31 mm in two. For the tricuspid valve replacements, we used 33 mm-sized valve in two patients. The combined operative procedures were left atrial auricle obliteration in 27, tricuspid annuloplasty in 17, tricuspid commissurotomy in one, mitral valvuloplasty in one, and correction of congenital anomalies in five cases.

The valvular pathology included rheumatic fever in 65,

bioprosthetic valve failure in 13, endocarditis in 10 (8 native and 2 prosthetic), degenerative disease in two, and unspecified in 11 patients. The New York Heart Association (NYHA) functional classification of patients was class II or I in 30 patients, class III in 61, and class IV in 10.

All patients were treated with warfarin postoperatively after extubation; the target INR (prothrombin time, international normalized ratio) was 1.7-2.3. After discharge, the INR was followed up every one to two months to control the warfarin dose. In general, patients were followed up every one to two months at the outpatient clinic. The data was analyzed based on the guidelines for reporting morbidity and mortality after cardiac valvular operations reported by Edmunds et al. (4).

RESULTS

Early deaths

There were six in-hospital deaths (5.9%): two after mitral and aortic valve replacement and one each after mitral valve replacement, aortic valve replacement, triple valve replacement, and modified Bentall operation. The causes of mortality were cardiopulmonary bypass weaning failure in three, septic shock in one, sudden cardiac arrest in one, and uncontrollable bleeding in one patient. Cardiopulmonary bypass weaning failure occurred in three patients; one of them previously underwent tissue valve replacement for endocarditis. One patient who died of septic shock had fungal endocarditis after tissue valve replacement and had acute renal failure postoperatively. Sudden cardiac arrest occurred in one patient five weeks after surgery. One patient who underwent the Bentall procedure died from sudden uncontrollable bleeding on the first day postoperatively; a tear around the anastomosis site was strongly suspected.

Late deaths (Table 1)

There were 13 late deaths (13.7%) during the follow-up period. The initial operations were mitral and aortic valve replacement in four, mitral and aortic valve replacement with tricuspid annuloplasty in two, mitral valve replacement with tricuspid annuloplasty in two, mitral valve replacement in two,

Table 1. Causes of late death

Causes of deaths	Number
Cerebral infarction	3
Sepsis	2
Congestive heart failure	2
Death after redo valve surgery	2
Sudden cardiac arrest	1
Cerebral hemorrhage	1
Lymphoma	1
Chronic liver disease	1

mitral, aortic and tricuspid valve replacement in one, aortic valve replacement with tricuspid annuloplasty in one, and the Bentall procedure in one patient. The causes of death were cerebral infarction in three, sepsis in two, congestive heart failure in two, cerebral hemorrhage in one, sudden cardiac arrest in one, multiorgan failure in one patient after a second operation, cardiopulmonary weaning failure after the third operation in one, lymphoma in one and chronic liver disease in one patient.

Late morbidity (Table 2)

There were 13 valve-related morbidities in 12 patients. Five patients had mitral valve replacement, 3 had aortic and mitral valve replacement, 1 had aortic valve replacement and tricuspid annuloplasty, 1 had aortic valve replacement, 1 had mitral/aortic/tricuspid valve replacement, and 1 had the Bentall operation.

Valve failure

There was one patient with structural valve degeneration. A 36-yr-old male underwent mitral valve replacement and 26 months later, prosthetic valve regurgitation was noted on echocardiography; the patient had no other specific symptoms. The patient is currently on routine follow-up with periodic echocardiographic examinations.

There were two patients with non-structural valve failure. One patient with a bicuspid aortic valve had aortic regurgitation with endocarditis. Two years after aortic valve replacement, paravalvular leakage was noted on echocardiography; the patient had no symptoms or signs, and he is being managed conservatively. The other patient had a ventricular septal defect with aortic regurgitation. Paravalvular leakage was noted right after the valve replacement, and two years later, severe hemolytic anemia with prosthetic valve endocarditis was detected. The patient underwent another aortic valve replacement with a St Jude mechanical valve; however, the paravalvular leakage persisted. Twenty-two months after the second operation, the third

Table 2. Valve-related complications

Complications	Number	Event/100 patient-year
Structural deterioration	1	0.065
Nonstructural dysfunction	2	0.131
Thromboembolism	8	0.590
Cerebral	6	
Femoral	1	
Ocular	1	
Anticoagulation-related hemorrhage	6	0.393
Leg ischemia	2	
Conjunctiva	1	
Jejunum	1	
Uterine	1	
Oral	1	
Prosthetic valve endocarditis	2	0.131

operation was performed; the patient died due to perioperative low cardiac output.

Thromboembolism

Thromboembolism occurred in eight patients. Five patients had mitral valve replacement, two had double valve replacement, one had triple valve surgery, and one had Bentall operation. Six patients had cerebral infarction, one had a femoral artery embolism, and one had an ocular artery embolism. All patients who had an embolic event had atrial fibrillation at the time of the embolism.

Anticoagulation-related hemorrhage

There were six patients who had anticoagulation-related hemorrhage that required hospital care; some had severe cerebral hemorrhage. Two patients had mitral valve replacement, two had aortic valve replacement, one had double valve replacement, and one had the Bentall operation. No patient had major bleeding after tricuspid valve replacement. The location of the hemorrhage included the lower extremities, conjunctiva, uterus, jejunum, and mouth (after tooth extraction).

Prosthetic valve endocarditis

There were two cases of prosthetic valve endocarditis. One patient had paravalvular leakage after surgery; no microorganism was identified on blood culture. However, there was purulent material noted at the prosthetic valve during surgery for the problem. The paravalvular leakage persisted, and the third operation was performed; the patient died due to low cardiac output. The other patient had mitral valve replacement; after tooth extraction a high fever and leukocytosis were noted. The patient and laboratory findings improved with antibiotics. There were no microorganisms detected on blood cultures, and the patient was diagnosed with endocarditis because his laboratory findings were normalized and the fever subsided after treatment with antibiotics.

Reoperation for valve replacement

There were two reoperations for valve replacement. One patient had paravalvular leakage and endocarditis after the first operation and expired after the third operation as noted above. The other patient had mitral valve replacement 14 yr later after the initial surgery; she stopped her warfarin medication during pregnancy. Valve thrombosis was detected on echocardiography; she underwent a redo mitral valve replacement with an On-X bileaflet mechanical valve.

Valve-related mortality

There were two valve-related mortalities. One patient who had double valve replacement died after a struggle with her husband; she died suddenly. The other patient also died suddenly after Bentall operation; we could not identify the cause of death.

Long-lasting sequelae

There were seven long-lasting sequelae. All had mitral valve replacement and cerebral infarction after surgery. One patient had a depressive disorder after surgery.

Overall survival

The mean follow-up duration was 181.2 ± 76.2 (0.3-263.8) months. The overall survival (except early death) was 86.2% at 15 yr and 83.1% at 20 yr. Patients who had mitral valve replacement had 93.5% and 90.2% cumulative survival at 10 and 15 yr, while patients who had aortic valve replacement had 91.1% and 86.5% cumulative survival at 10 and 15 yr, respectively (Fig. 1). The two groups had no significant difference in the rate of survival. Double valve replacement patients had 92.2% and 84.0% survival at 10 and 15 yr, respectively. There were no significant differences in survival rates between the single and double valve replacement groups.

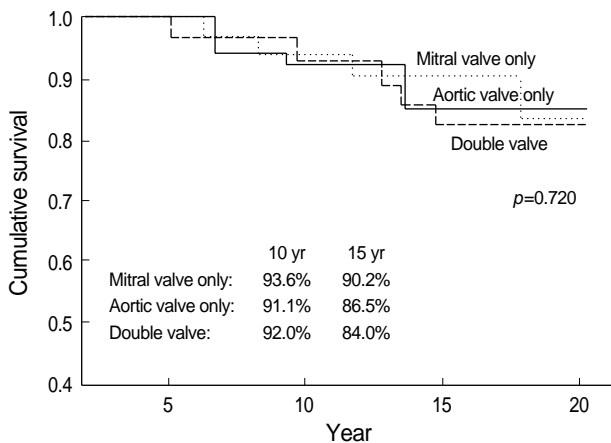


Fig. 1. Comparison of survival among mitral valve, aortic valve, and double valve replacement.

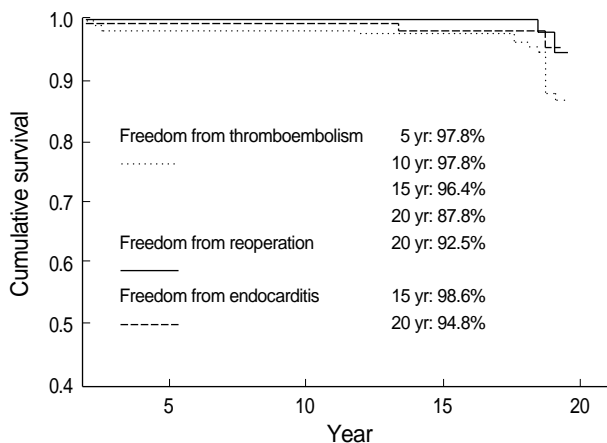


Fig. 2. Freedom from valve-related morbidity.

Morbidity profiles

The morbidity profiles of the study patients are shown in Fig. 2. Freedom from thromboembolism was noted in 97.8%, 97.8%, 96.4% and 87.8% at 5, 10, 15 and 20 yr, respectively. Absence of endocarditis was noted in 98.6% and 94.8% at 15 and 20 yr. Absence of reoperation was 92.5% at 20 yr. We could not get exact data about anticoagulation-related bleeding, and therefore, we did not suggest our result in this series.

DISCUSSION

Most of the ball valves or horizontal disc valves are centrally occluding valves. They have different upper and lower systolic pressure. To improve this type of device, the Wada tilting disc valve was developed; however, this valve had a fixed hinged point. The Delrin Björk valve was developed in 1968 with no hinged point and other improvements. It is now used worldwide. In 1971 the Delrin plate was changed to a pyrolytic carbon plate because the plate deformed with moisture; to protect against fracture, an inflow strut was linked to an eccentric valvular orifice (5). In 1975, to be able to detect valvular obstruction by thromboembolism easily, the valvular orifice was changed to tantalum, which is radioopaque (6). In 1979, in order to reduce the risk of thromboembolism, the flat plate was reshaped to be concave, and the angular aperture was reformed 60 degrees. In order to decrease the pressure gradient, the angular aperture was changed to 70 degrees; however, as a result, outflow strut fracture occurred; then the manufacturing production of the valve was suspended. Lindblom et al. (3) reported 1,461 cases of Björk-Shiley valve replacements; the five-year valve failure rate with a 60 or 70-degree angular aperture was 0.6% and 2.8%, respectively. Orszulak et al. (7) used Delrin valve, 60 degree opening angled valve and convexo-concaved valve. They reported the prevalence of patients remaining free of event at 5 and 10 yr at 61% and 42%, respectively.

The Monostrut Björk-Shiley valve was developed to protect from outflow strut fracture. In addition, to reduce the risk of thromboembolism a concave plate with an angular aperture of 70 degrees was developed. Nakano et al. (8) reported that there were no cases with structural valve deterioration when the Monostrut Björk-Shiley valve was used. The freedom from valve-related morbidity and mortality was $86 \pm 2.0\%$ at 5 yr: $86 \pm 9.5\%$ for aortic, $87 \pm 3.3\%$ for mitral, and $75 \pm 7.3\%$ for double valve replacement. Effective valve areas (average) of 12 mitral and 12 aortic valve prostheses were calculated at rest and during bicycle exercise: 2.4 cm^2 at rest and 2.8 cm^2 during exercise in 27 mm aortic valves, 2.4 cm^2 at rest and 3.0 cm^2 during exercise in 25 mm aortic valves, 2.0 cm^2 at rest and 2.4 cm^2 during exercise in 27 mm mitral valves, and 2.6 cm^2 at rest and 2.5 cm^2 during exercise in 29 mm mitral valve. Therefore, the Björk-

Shiley Monostrut valve was accepted as reliable with a low incidence of valve-related morbidity and with satisfactory hemodynamic characteristics at rest and during exercise. Lindblom et al. (9) reported that the three-year survival (early mortality excluded) was 88.6% (aortic valve replacement 89.2%, mitral valve replacement 89.3%, and double valve replacement 82.5%). The three-year rate of freedom from thromboembolism in patients receiving anticoagulants was as follows: aortic valve replacement 97.5%, mitral valve replacement 92.8%, and double valve replacement 100%. There were no cases of valve thrombosis or fatal embolism. By contrast, there were two cases of aortic valve thrombosis among 34 patients with aortic valve replacement who did not receive anticoagulation.

Thromboembolism is one of the most serious complications of mechanical valve replacement procedures. The incidence of thromboembolism was 0.6%/patient-year in our series, slightly lower than that reported by Nakano (8), 1.5%/patient-year, and that by Nashef et al. (10), 2%/patient-year. For patients with mitral valve replacement, the incidence was 0.3%/patient-year; there was no embolism observed in patients with aortic valve replacement; patients with double valve replacement had an incidence of 0.4%/patient-year, and for patients with triple valve replacement it was 1.3%/patient-year. However, there were only five patients with triple valve replacements. In these patients we used multiple different valves for replacement; therefore, it is difficult to determine a meaningful incidence rate in this group of patients. The three-year survival without thromboembolism in the aortic and mitral valve replacement patients was 100%, and these findings are consistent with those of Crawford (1) who reported rates of 98% and 93%, respectively in 1987 Daenen et al. (11) reported their mid-term result of the Björk-Shiley Monostrut valve in a large series. For 647 patients, actuarial freedom from thromboembolism was 86% at 6 yr; there were no cases of valve thrombosis, and patients having thromboembolic event showed a higher probability of late death after native valve replacement.

Anticoagulation-related complications occurred in 0.4%/patient-year, lower than the rate reported by Björk et al. (1) (2.2%/patient-year). We had no anticoagulation related death; however, there was 0.5%/patient-year mortality. In addition, the St Jude valve and Carbomedics had a 1.43%/patient-year and 2.64%/patient-year anticoagulation-related complication rate, which was almost the same as the Björk-Shiley valve rates. We used the same strategy for anticoagulation therapy in all patients who had mechanical valve replacement.

From the results of our long-term evaluation of the Björk-Shiley valve, it appears to have similar anticoagulation-related hemorrhage risks but slightly higher thromboembolism risks than in other mechanical valves. We are now using a bileaflet mechanical valve instead of tilting disc prosthesis; however, the Björk-Shiley Monostrut valve had good long-term results without significant complications and a mortality rate comparable to those in other valves, which is in line with other

reports (12, 13). From these observations, we state that the performance of the Monostrut Björk-Shiley valve on long-term follow-up is acceptable and comparable with results published by other centers using the same type of prosthesis (12-15).

REFERENCES

1. Crawford FA Jr. *Current heart valve prostheses. Cardiac Surgery* 1987; 1: 183-202.
2. Björk VO. *A new tilting disc valve prosthesis. Scand J Thorac Cardiovasc Surg* 1969; 3: 1-10.
3. Lindblom D, Björk VO, Semb BK. *Mechanical failure of the Björk-Shiley valve. Incidence, clinical presentation and management. J Thorac Cardiovasc Surg* 1986; 92: 894-907.
4. Edmunds LH Jr, Clark RE, Cohn LH, Grunkemeier GL, Miller DC, Weisel RD. *Guidelines for reporting morbidity and mortality after cardiac valvular operations. Ad Hoc Liaison Committee for Standardizing Definitions of Prosthetic Heart Valve Morbidity of The American Association for Thoracic Surgery and The Society of Thoracic Surgeons. J Thorac Cardiovasc Surg* 1996; 112: 708-11.
5. Björk VO. *The pyrolytic carbon occluder for the Björk-Shiley tilting disc valve prosthesis. Scand J Thorac Cardiovasc Surg* 1972; 6: 109-13.
6. Björk VO, Henze A, Hindmarsh T. *Radiopaque marker in the tilting disc of the Björk-Shiley heart valve. Evaluation of in vivo prosthetic valve function by cineradiography. J Thorac Cardiovasc Surg* 1977; 73: 563-9.
7. Orszulak TA, Schaff HV, DeSmet JM, Danielson GK, Pluth JR, Puga FJ. *Late results of valve replacement with the Björk-Shiley valve (1973 to 1982). J Thorac Cardiovasc Surg* 1993; 105: 302-12.
8. Nakano SN, Kawashima Y, Matsuda H, Kawamoto T, Shintani H, Mitsuno M, Ueda T. *A five-year appraisal and hemodynamic evaluation of the Björk-Shiley Monostrut valve. J Thorac Cardiovasc Surg* 1991; 101: 881-7.
9. Lindblom D, Lindblom U, Henze A, Björk VO, Semb BK. *Three-year clinical results with the Monostrut Björk-Shiley prosthesis. J Thorac Cardiovasc Surg* 1987; 94: 34-43.
10. Nashef MD. *An evaluation of the Björk-Shiley Monostrut valve: Abst. of monostrut valve symposium. Dallas Tx* 1987; 30.
11. Daenen W, Van Kerrebroeck C, Stalpaert G, Mertens B, Lesaffre E. *The Björk-Shiley Monostrut valve. Clinical experience in 647 patients. J Thorac Cardiovasc Surg* 1993; 106: 918-27.
12. Aris A, Padro JM, Camara ML, Crexells C, Augé JM, Caralps JM. *Clinical and hemodynamic results of cardiac valve replacement with the Monostrut Björk-Shiley prosthesis. J Thorac Cardiovasc Surg* 1988; 95: 423-31.
13. Thulin LI, Bain WH, Huysmans HH, van Ingen G, Prieto I, Basile F, Lindblom DA, Olin CL. *Heart valve replacement with the Björk-Shiley Monostrut valve: early results of a multicenter clinical investigation. Ann Thorac Surg* 1988; 45: 164-70.
14. Canivet P, Vitoux B, Vahanian A, Michel PL, Cormier B, Enriquez Sarano L, Richaud C, Acar J. *Björk-Shiley-Monostrut prosthesis of the aortic valve. Mid-term development. Arch Mal Coeur Vaiss* 1991; 84: 57-62.
15. Dietrich MS, Nashef SA, Bain WH. *Heart valve replacement with the Björk-Shiley Monostrut valve in patients over 60 years of age. Thorac Cardiovasc Surg* 1998; 37: 131-4.