

ARTICLE

Identification of two novel mutations in the *GALNT3* gene in a Chinese family with hyperphosphatemic familial tumoral calcinosis

Lihao Sun^{1*}, Lin Zhao^{1,2*}, Lianjun Du³, Peipei Zhang³, Minjia Zhang¹, Min Li¹, Tingting Liu¹, Lei Ye¹, Bei Tao¹, Hongyan Zhao¹, Jianmin Liu¹ and Xiaoyi Ding³

Hyperphosphatemic familial tumoral calcinosis (HFTC) is a rare, autosomal recessive genetic disease. This disease is characterized by the progressive calcification of soft tissues leading to symptoms of pressure and hyperphosphatemia but normal concentrations of serum calcium with or without an elevation of 1,25-dihydroxyvitamin D₃ levels. HFTC is caused by loss-of-function mutations in the *GALNT3*, *FGF23* or *KL* genes. Here, we identified two novel mutations in the *GALNT3* gene in a Chinese family with HFTC. Identification of a novel genotype in HFTC provides clues for understanding the phenotype-genotype relationships in HFTC and may assist not only in the clinical diagnosis of HFTC but also in the interpretation of the genetic information used for prenatal diagnosis and genetic counseling.

Bone Research (2016) 4, 16038; doi:10.1038/boneres.2016.38; published online: 8 November 2016

INTRODUCTION

Familial tumoral calcinosis (FTC) is a rare, autosomal recessive genetic disease. The main clinical manifestation of FTC is the development of calcified masses predominantly at peri-articular locations, especially the hips, leading to intolerable pain, skin ulcerations and secondary skin and bone infections.¹

According to serum phosphate concentrations, FTC can be classified as hyperphosphatemic (HFTC) or normophosphatemic FTC.² FTC is caused by a loss-of-function mutation in one of the following genes: *FGF23*, which encodes the potent phosphaturic protein fibroblast growth factor 23; *GALNT3*, which encodes the uridine diphosphate-N-acetyl- α -D-galactosamine-polypeptide N-acetylgalactosaminyl-transferase 3 (GalNAc-T3), a glycosyl transferase responsible for *FGF23* O-glycosylation and proper secretion; or *KL*, which encodes Klotho, an *FGF23* co-factor required to activate *FGF* receptors.^{3–7}

The incidences of FTC in men and women are similar; however, the incidence in black patients of African descent is relatively high, followed by that in white patients from the Middle East.¹ Only one observed individual with HFTC caused by an *FGF23* mutation was Japanese.^{7–8} Herein, we report two HFTC cases with two novel mutations in the *GALNT3* gene.

MATERIALS AND METHODS

Case report

The proband of this study was a 13-year-old boy. When he was 2 years old, his parents accidentally discovered hard masses with slight tenderness on his right hip and feet. With increasing age, the masses increased in size. Several operations were performed to remove the masses on his feet and right hip.

The patient's sister also had similar masses on her hip (Figure 1) and feet; these masses were excised but

¹Department of Endocrine and Metabolic Diseases, Rui-jin Hospital, Shanghai Jiao-Tong University School of Medicine, 197 Rui-jin Er Road, Shanghai 200025, China; ²Department of Endocrinology and Metabolism, Zhong-shan Hospital, Fudan University, Shanghai 200032, China and ³Department of Radiology, Rui-jin Hospital, Shanghai Jiao-Tong University School of Medicine, 197 Rui-jin Er Road, Shanghai 200025, China

*These authors contributed equally to this work.

Correspondence: Jianmin Liu (liujianmin@medmail.com.cn) and Xiaoyi Ding (Dingxiaoyi@hotmail.com)

Received: 17 August 2016; Accepted: 23 August 2016

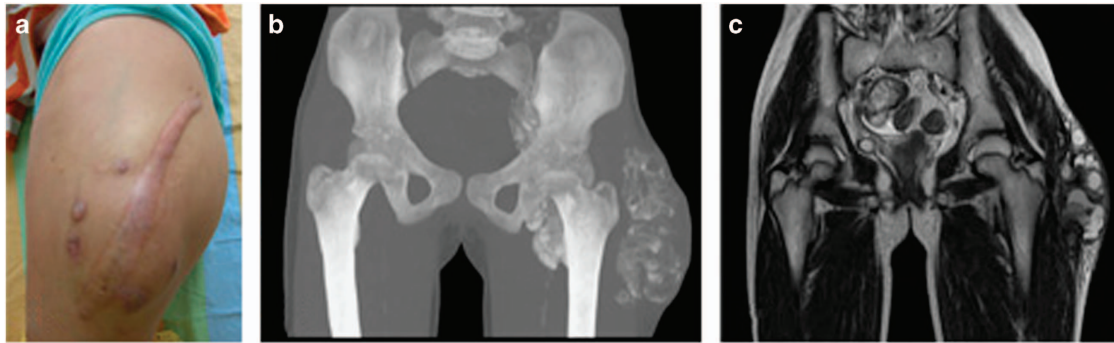


Figure 1. Imaging data for the sister of the patient. (a) The left hip shows a surgical scar overlying a large tumor mass. (b,c) Pelvic computed tomography (CT) with a three-dimensional reconstruction and magnetic resonance imaging (MRI) revealed a calcified left hip mass infiltrating into the pelvis.

Table 1. The serum biochemical parameters of the current familial tumoral calcinosis (FTC) family

Biochemical parameters	Proband	Sister	Mother	Father
Phosphate/(mmol·L ⁻¹)	2.88 (0.8–1.6)	1.82	1.17	1.23
Calcium/(mmol·L ⁻¹)	2.55 (2–2.75)	2.41	2.36	2.28
PTH/(pg·mL ⁻¹)	15.4 (15–68.3)	48.7	52	30
25(OH)D/(nmol·L ⁻¹)	69.2 (44.7–144)	37.5	41.2	52.4
Creatinine/(μmol·L ⁻¹)	46 (53–115)	53	74	82

recurred post-operatively. No ectopic calcification foci were identified in their parents. The serum phosphate concentrations of the father and mother were normal (Table 1). Both parents were healthy and did not have a history of autoimmune diseases or similar disorders. There was no consanguineous marriage or white or black genetic admixture in this family for the past three generations.

Upon physical examination, the proband was conscious and cooperative. Claudication of the right leg was observed. A large, hard mass with slight tenderness was found on the right hip (Figure 2a). The serum phosphate level for this patient was as high as 2.88 mmol·L⁻¹ (normal range: 0.8–1.6 mmol·L⁻¹). His serum levels of parathyroid hormone (PTH) and 25-hydroxyvitamin D₃ were normal.

A plain X-ray of the pelvis revealed calcification of a soft tissue mass in the right hip. No cortical hyperostosis, diaphysitis, or periosteal apposition was observed at the femur (Figure 2b) or ankle joints. Magnetic resonance imaging of the pelvis confirmed the findings of the plain radiography (Figure 2c).

An operation to remove the mass on the right hip of the proband was performed in our hospital. The tumor size was ~16×3×5 cm³ with multiple lobes and gray allantoic fluid (Figure 2d). The size of the cyst within the tumor was 1.5×2.5 cm², and the cyst was encapsulated by a 0.5 cm thick, smooth wall and contained a lime-like material. The

histopathological examination of the tumor mass revealed fibrous tissue hyperplasia within the cyst wall with calcification and giant cell reaction (Figure 2e).

Genetic analysis

Whole-blood samples were collected from the proband, his sister and family members (9 samples) after written informed consent was obtained. Genomic DNA was isolated from the leukocytes. A direct sequencing method was used to sequence the *GALNT3* and *FGF23* genes of the patients and their relatives (ABI 3700 automated fluorescent sequencer was used for bidirectional sequencing). DNA from another 100 unrelated normal subjects was also tested for these two genes. The potential for DNA sequence alterations and the effects of such alterations on the structure and function of the DNA were evaluated by the online programs MutationTaster⁹ (<http://www.mutationtaster.org>), PolyPhen-2¹⁰ (<http://genetics.bwh.harvard.edu/pph2>) and SIFT¹¹ (<http://sift.jcvi.org>).

RESULTS

As shown in Figure 3, exon 2 of the *GALNT3* gene in both the proband and his sister had 2 homozygous missense mutations: a 539G-A homozygous mutation (Figure 3c1), which resulted in the substitution of arginine 180 with histidine (R180H), and a 659T-A homozygous mutation (Figure 3c2), leading to the substitution of isoleucine 220 with asparagine (I220N). Their parents did not present any clinical characteristics of FTC, but both had the heterozygous mutations of *GALNT3* in exon2 (R180H and I220N; Figure 3b1 and b2). The identified nucleotide changes were not found in other members of the family (Figure 3a1). As predicted by MutationTaster and PolyPhen-2, both of these mutations were “Disease causing”. The results derived from the SIFT analysis also showed that the

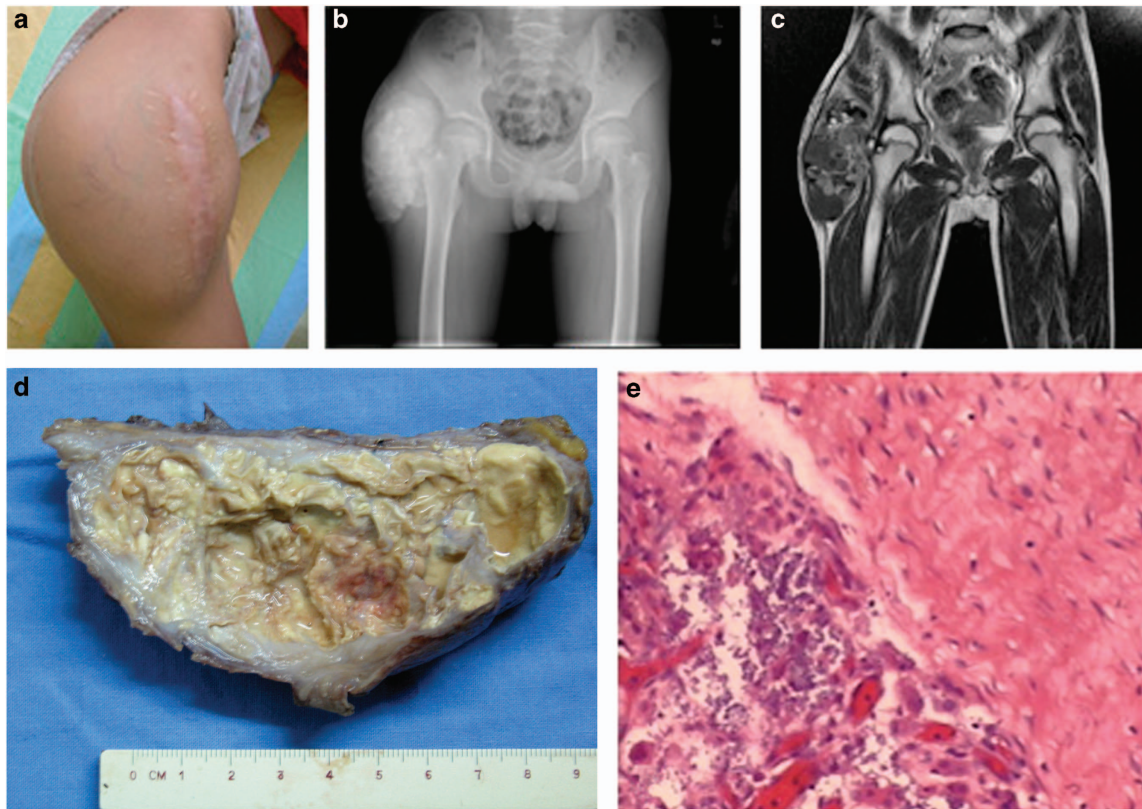


Figure 2. Imaging data of the patient. (a) On the right side of the buttocks of the patient, a 14-cm surgical scar with varicosity of the superficial veins in the region was observed in the region of the abnormal mass that was approximately 18 cm in length. (b) A computed tomography (CT) reconstruction film of the pelvis shows a calcified soft tissue mass in the right hip. Femur: normal bone density. (c) In a T1-weighted magnetic resonance imaging of the pelvis, low intensity signals were obtained at the site of the lesion, indicating the presence of a soft tissue mass in the right hip. (d) A 16 × 3 × 5 cm tumor specimen was obtained during the operation; the tumor section showed multiple lobes and a gray allantoic fluid. The size of the cyst within the tumor was 1.5 × 2.5 cm, and the cyst was encapsulated with a 0.5-cm-thick smooth wall and contained a lime-like material. (e) Histological analysis showed fibrous tissue hyperplasia of the capsular wall with calcification and giant cell reaction.

mutation of I220N is “Damaging” and that R180H is “Tolerated”.

The *FGF23* mutation was not found in the proband or other members of the family. No mutations at these loci were identified in an additional 100 unrelated normal subjects.

DISCUSSION

This study documents the first Chinese family clinically diagnosed with HFTC and confirmed by genetic analysis, with the identification of two new mutations in *GALNT3*.

FTC is an autosomal recessive, genetic metabolic disorder. The most notable clinical manifestation of FTC is ectopic calcification, predominantly at the hip, elbow joints, shoulders, and knees. FTC rarely affects the skin, intervertebral discs, epidural sites, or perineum. There are two subtypes of FTC, hyperphosphatemic (HFTC) and normophosphatemic FTC. Clearly, the two cases presented here are not normophosphatemic FTC. In addition,

our patients did not present bone lesions, such as hyperostosis; therefore, hyperostosis-hyperphosphatemia syndrome, which also results from mutations in the *GALNT3* gene,¹ could be excluded.

Generally, HFTC occurs before the age of 20. Serum phosphate levels in these patients are elevated, but their circulating calcium and PTH concentrations are normal. The serum levels of 1,25-dihydroxyvitamin D₃ are normal or slightly higher than normal in these patients. The renal function is normal in these patients.^{12–13}

The imaging features of FTC are typical. These tumor masses are often located in the *musculus extensor lateralis*. Computed tomography typically reveals lobulated calcific masses within the soft tissues with a separate encapsulated cystic component. T1-weighted images from the magnetic resonance imaging show a non-homogeneous low-signal region, whereas the T2-weighted image shows a high-signal region of nodules and a non-signal region in the diffuse low-signal region.¹⁴ The two patients we presented also had typical imaging features of FTC.

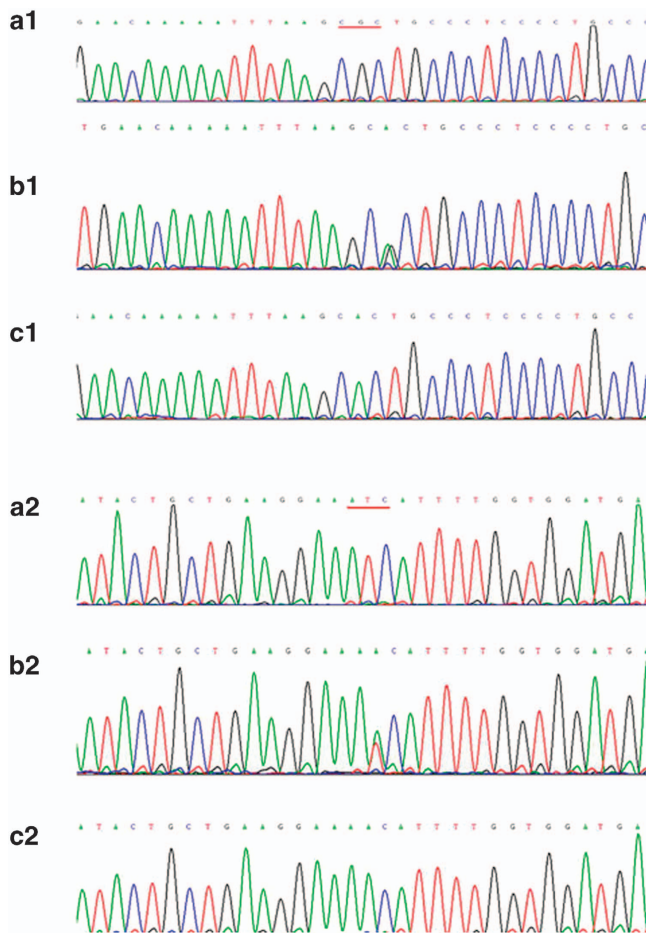


Figure 3. Mutation types of *GALNT3*. The sequence of the PCR-amplified exon 2 of the *GALNT3* gene. Wild-type 539G-A (a1), heterozygous mutation (b1), homozygous mutation (c1). Wild-type 659T-A (a2), heterozygous mutation (b2), homozygous mutation (c2).

A differential diagnosis of FTC should be made because several other medical conditions may appear similar to FTC in the imaging tests,¹ such as renal inadequacy, heterotopic calcification secondary to primary hyperparathyroidism, and vitamin D poisoning. Systemic diseases with clinical manifestations of ectopic calcification include mixed connective tissue disease, dermatomyositis, polymyositis, and systemic lupus erythematosus. Neoplastic diseases (including synovial sarcoma, osteosarcoma, and chondrosarcoma) and some degenerative disorders, such as calcified tendonitis, may also have similar radiological findings to those of FTC.¹⁴ If the patient has no history of the above-mentioned diseases and has a normal renal function, normal serum PTH, and 25-hydroxyvitamin D₃ levels, heterotopic calcification secondary to the other diseases is unlikely.

The most common molecular pathogenesis of HFTC is related to loss-of-function mutations in *GALNT3*,¹ which encodes UDP-GalNAc transferase 3 (GalNAc-T3) and

mediates the glycosylation of FGF23, a potent phosphaturic protein. In the presence of a *GALNT3* mutation, FGF23 proteins cannot be glycosylated and are vulnerable to degradation, resulting in hyperphosphatemia and FTC.^{5,15–16}

GALNT3 mutations in FTC can occur at various loci within the gene, and there are no obvious hotspot mutations.^{17–24} In our study, both the proband and his sister carried 2 homozygous mutations (R180H and I220N) on exon 2 of the *GALNT3* gene. It has been reported that most *GALNT3* mutations can lead to early termination of protein translation or the defective translation of exons caused by an error in intron splicing.¹⁸ Mutational analysis using online software programs revealed that these two mutations are both located within the coding region and may cause alterations in the amino acid sequence, which might affect protein features. Thus, these mutations are predicted to be pathogenic. In addition, the mutation I220N within the glycosyl transferase domain may cause splice-site changes. In addition, the novel mutations we identified in exon 2 are adjacent to several previous reported mutations, further suggesting that this region of the *GALNT3* may be susceptible to an increased mutation rate.

The clinical phenotype and severity of HFTC are not always related to the genotype. In our cohort, each patient harbored two homogenous mutations in exon 2 of the *GALNT3* gene and demonstrated severe clinical features, whereas other HFTC patients carrying one homozygous mutation in *GALNT3*, with mild to severe calcification, need multiple operations.¹⁹ Indeed, the phenotypes of FTC are heterogeneous, with a wide variation in disease severity and involved tissues.^{25–26} For example, Ichikawa S. *et al.*²⁷ described an FTC patient with a compound heterozygote for two mutations in exon 3 and exon 5 of the *GALNT3* gene, resulting in coding changes within the catalytic domain of GalNAc-T3. However, this patient demonstrated only a small eyelid ectopic calcification. In another two symptomatic siblings with compound heterozygous *GALNT3* mutations in exon 4 and 5, one exhibited features of FTC but the other demonstrated hyperostosis-hyperphosphatemia syndrome.²⁶ Different *GALNT3* mutations have been reported in the literature (Table 2). It is noteworthy that our two cases are the only ones carrying homozygous mutations. The parents of the patients in our study carried compound heterozygotes for the two mutations in exon 2, which were reported in 11 of 32 families with FTC or hyperostosis-hyperphosphatemia syndrome caused by *GALNT3* mutations (Table 2), but they were reluctant to participate in additional examinations to exclude mild FTC or hyperostosis-hyperphosphatemia syndrome.

Our study has several limitations. Serum FGF23 levels were not measured, and a genetic analysis was not performed

Table 2. A summary of currently known *GALNT3* mutations and their associated clinical features

Family	Mutation (cDNA)	Mutation (protein)	Exon	Phenotype	Homozygous compound heterozygotes	References
1	c.2T>A	p.M1?	1	Hyperostosis		20
	c.839G>A	p.C280Y	4		Compound heterozygotes	26
2	c.842A>G	p.E281G	4	Tumoral calcinosis, hyperostosis		
	c.1097T>G	p.L366R	5		Compound heterozygotes	28
3	c.1312C>T	p.R438C	6	Hyperostosis, tumoral calcinosis, thyroid calcification and other atypical symptoms	Compound heterozygotes	
	c.1774C>T	p.Q592X	9		Compound heterozygotes	
4	c.516-2A>T	p.C173VfsX4	2	Tumoral calcinosis		21
5	c.1313G>A	p.R438H	6	Hyperostosis	Homozygous	21
6	c.1102_1103insT	p.S368FfsX8	5	Tumoral calcinosis	Homozygous	18
7	c.1460G>A	p.W487X	7	Tumoral calcinosis	Homozygous	18
8	c.966T>G	p.Y322X	4	Tumoral calcinosis	Homozygous	16
	c.1441CT	p.Q481X	7		Compound heterozygotes	
9	c.803-804insC	p.A268fsX4	3	Hyperostosis		5
	c.1626+1G>A	splice site	8		Compound heterozygotes	
10	c.815C>A	p.T272K	3	Tumoral calcinosis		27
	c.1076C>A	p.T359K	5		Compound heterozygotes	
11	c.41_58del	p.R14fs21X	1	Tumoral calcinosis		22
12	c.1387A>T	p.K463X	6	Tumoral calcinosis	Homozygous	12
13	c.1774C>T	p.Q592X	9	Tumoral calcinosis	Homozygous	23
14	c.484C>T c.516-2A>T	p.R162X p.C173VfsX4	1	Tumoral calcinosis	Homozygous	9
15	c.1524+1G>A	p.K465_Y508del	7	Hyperostosis	Compound heterozygotes	23
16	c.1524+1G>A	p.K465_Y508del	7	Tumoral calcinosis		3
17	c.1524+5G>A	Splice site	7	Tumoral calcinosis	Homozygous	3
	c.484C>T	p.R162X	1		Homozygous	
18	c.485G>A	p.R162Q	1	Tumoral calcinosis	Compound heterozygotes	17
19	c.1392+1G>A	Splice error	6	Hyperostosis		17
20	c.677delC	p.A226VfsX3	2	Tumoral calcinosis	Homozygous	17
21	c.1720T>G	p.C574G	9	Tumoral calcinosis	Homozygous	17
22	c.1245T>A	p.H415Q	6	Tumoral calcinosis	Homozygous	19
23	c.1312T>C	p.R438C	6	Tumoral calcinosis	Homozygous	19
24	c.1524+1G>A	p.K465_Y508del	7	Hyperostosis	Homozygous	20
25	c.767G>T	p.G256V	3	Tumoral calcinosis	Homozygous	21
26	c.484C>T	p.R162X	1	Tumoral calcinosis	Homozygous	23
27	c.484C>T	p.R162X	1	Tumoral calcinosis	Homozygous	24
28	c.516-2A>T	p.C173VfsX4	2	Tumoral calcinosis	Homozygous	22
	c.260-266del	p.R87QfsX2	1		Homozygous	
29	c.1584-1585insA	p.P529TfsX17	8	Tumoral calcinosis	compound heterozygotes	22
30	c.516-2A>T	p.C173VfsX4	2	Tumoral calcinosis		22
	c.1524+5G>A	Splice site	7		Homozygous	
31	c.746-749del	p.R250TfsX2	3	Tumoral calcinosis	Compound heterozygotes	22
	c.892del	p.Y298SfsX5	4			
32	c.539G>A	p.R180H	2	Tumoral calcinosis	Compound homozygous	Present study
	c.659T>A	p.I220N	2	Tumoral calcinosis		Present study

on the *KL* gene. In addition, a functional analysis of the *GALNT3* gene was not conducted.

In summary, we identified two novel mutations (R180H and I220N) in exon 2 of the *GALNT3* gene. This report provides the first clinical and genetic description of HFTC in a Chinese family. Further study is needed to explore the mechanism of such a mutation on FGF23 activity. Our findings may assist not only in the clinical diagnosis of HFTC but also in the interpretation of the genetic information used for prenatal diagnosis and genetic counseling.

Acknowledgements

This work was funded by the Science and Technology Commission of Shanghai Municipality (No. 134119a2400). This work was also supported by National Rare Diseases Registry System of China (Nos. 2016YFC0901500 and 2016YFC0901503) and the Shanghai Municipal Health Bureau Project (No. 20124235).

Competing interests

The authors declare no conflict of interest.

References

- 1 Sprecher E. Familial tumoral calcinosis: from characterization of a rare phenotype to the pathogenesis of ectopic calcification. *J Invest Dermatol* 2010; **130**: 652–660.
- 2 Smack D, Norton SA, Fitzpatrick JE. Proposal for a pathogenesis-based classification of tumoral calcinosis. *Int J Dermatol* 1996; **35**: 265–271.
- 3 Topaz O, Shurman DL, Bergman R *et al*. Mutations in GALNT3, encoding a protein involved in O-linked glycosylation, cause familial tumoral calcinosis. *Nat Genet* 2004; **36**: 579–581.
- 4 Larsson T, Yu X, Davis SI *et al*. A novel recessive mutation in fibroblast growth factor-23 causes familial tumoral calcinosis. *J Clin Endocrinol Metab* 2005; **90**: 2424–2427.
- 5 Ichikawa S, Imel EA, Kreiter ML *et al*. A homozygous missense mutation in human KLOTHO causes severe tumoral calcinosis. *J Clin Invest* 2007; **117**: 2684–2691.
- 6 Farrow EG, Imel EA, White KE. Miscellaneous non-inflammatory musculoskeletal conditions. Hyperphosphatemic familial tumoral calcinosis (FGF23, GALNT3 and alphaKlotho). *Best Pract Res Clin Rheumatol* 2011; **25**: 735–747.
- 7 Bergwitz C, Banerjee S, Abu-Zahra H *et al*. Defective O-glycosylation due to a novel homozygous S129P mutation is associated with lack of fibroblast growth factor 23 secretion and tumoral calcinosis. *J Clin Endocrinol Metab* 2009; **94**: 4267–4274.
- 8 Yamaguchi T, Sugimoto T, Imai Y *et al*. Successful treatment of hyperphosphatemic tumoral calcinosis with long-term acetazolamide. *Bone* 1995; **16**: 247S–250S.
- 9 Schwarz JM, Rodelsperger C, Schuelke M *et al*. MutationTaster evaluates disease-causing potential of sequence alterations. *Nat Methods* 2010; **7**: 575–576.
- 10 Adzhubei IA, Schmidt S, Peshkin L *et al*. A method and server for predicting damaging missense mutations. *Nat Methods* 2010; **7**: 248–249.
- 11 Kumar P, Henikoff S, Ng PC. Predicting the effects of coding non-synonymous variants on protein function using the SIFT algorithm. *Nat Protoc* 2009; **4**: 1073–1081.
- 12 Campagnoli MF, Pucci A, Garelli E *et al*. Familial tumoral calcinosis and testicular microlithiasis associated with a new mutation of GALNT3 in a white family. *J Clin Pathol* 2006; **59**: 440–442.
- 13 Polykandriotis EP, Beutel FK, Horch RE *et al*. A case of familial tumoral calcinosis in a neonate and review of the literature. *Arch Orthop Trauma Surg* 2004; **124**: 563–567.
- 14 Olsen KM, Chew FS. Tumoral calcinosis: pearls, polemics, and alternative possibilities. *Radiographics* 2006; **26**: 871–885.
- 15 Kato K, Jeanneau C, Tarp MA *et al*. Polypeptide GalNAc-transferase T3 and familial tumoral calcinosis. Secretion of fibroblast growth factor 23 requires O-glycosylation. *J Biol Chem* 2006; **281**: 18370–18377.
- 16 Barbieri AM, Filopanti M, Bua G *et al*. Two novel nonsense mutations in GALNT3 gene are responsible for familial tumoral calcinosis. *J Hum Genet* 2007; **52**: 464–468.
- 17 Ichikawa S, Baujat G, Seyahi A *et al*. Clinical variability of familial tumoral calcinosis caused by novel GALNT3 mutations. *Am J Med Genet A* 2010; **152A**: 896–903.
- 18 Garringer HJ, Mortazavi SM, Esteghamat F *et al*. Two novel GALNT3 mutations in familial tumoral calcinosis. *Am J Med Genet A* 2007; **143A**: 2390–2396.
- 19 Yancovitch A, Hershkovitz D, Indelman M *et al*. Novel mutations in GALNT3 causing hyperphosphatemic familial tumoral calcinosis. *J Bone Miner Metab* 2011; **29**: 621–625.
- 20 Frishberg Y, Ito N, Rinat C *et al*. Hyperostosis-hyperphosphatemia syndrome: a congenital disorder of O-glycosylation associated with augmented processing of fibroblast growth factor 23. *J Bone Miner Res* 2007; **22**: 235–242.
- 21 Rafaelsen S, Johansson S, Raeder H *et al*. Long-term clinical outcome and phenotypic variability in hyperphosphatemic familial tumoral calcinosis and hyperphosphatemic hyperostosis syndrome caused by a novel GALNT3 mutation; case report and review of the literature. *BMC Genet* 2014; **15**: 98.
- 22 Ramnitz MS, Gourh P, Goldbach-Mansky R *et al*. Phenotypic and Genotypic Characterization and Treatment of a Cohort With Familial Tumoral Calcinosis/Hyperostosis-Hyperphosphatemia Syndrome. *J Bone Miner Res* 2016; **31**: 1845–1854.
- 23 Demellawy DE, Chang N, de Nanassy J *et al*. GALNT3 gene mutation-associated chronic recurrent multifocal osteomyelitis and familial hyperphosphatemic familial tumoral calcinosis. *Scand J Rheumatol* 2015; **44**: 170–172.
- 24 Vieira AR, Lee M, Vairo F *et al*. Root anomalies and dentin dysplasia in autosomal recessive hyperphosphatemic familial tumoral calcinosis (HFTC). *Oral Surg Oral Med Oral Pathol Oral Radiol* 2015; **120**: e235–e239.
- 25 Sprecher E. Tumoral calcinosis: new insights for the rheumatologist into a familial crystal deposition disease. *Curr Rheumatol Rep* 2007; **9**: 237–242.
- 26 Joseph L, Hing SN, Presneau N *et al*. Familial tumoral calcinosis and hyperostosis-hyperphosphatemia syndrome are different manifestations of the same disease: novel missense mutations in GALNT3. *Skeletal Radiol* 2010; **39**: 63–68.
- 27 Ichikawa S, Imel EA, Sorenson AH *et al*. Tumoral calcinosis presenting with eyelid calcifications due to novel missense mutations in the glycosyl transferase domain of the GALNT3 gene. *J Clin Endocrinol Metab* 2006; **91**: 4472–4475.
- 28 Dumitrescu CE, Kelly MH, Khosravi A *et al*. A case of familial tumoral calcinosis/hyperostosis-hyperphosphatemia syndrome due to a compound heterozygous mutation in GALNT3 demonstrating new phenotypic features. *Osteoporos Int* 2009; **20**: 1273–1278.



This work is licensed under a Creative Commons Attribution 4.0 International License. The images or other third party material in this article are included in the article's Creative Commons license, unless indicated otherwise in the credit line; if the material is not included under the Creative Commons license, users will need to obtain permission from the license holder to reproduce the material. To view a copy of this license, visit <http://creativecommons.org/licenses/by/4.0/>

© The Author(s) 2016