

# Severe cutaneous drug toxicity following enfortumab vedotin treatment for metastatic urothelial carcinoma



Christina D. Enescu, BS,<sup>a</sup> Christina Artz, MD,<sup>b</sup> and Anna Axelson, MD<sup>b</sup>  
*Detroit, Michigan*

**Key words:** cutaneous drug toxicity; enfortumab vedotin; exfoliative dermatitis; general dermatology.

## INTRODUCTION

Enfortumab vedotin (EV) is an antibody-drug conjugate approved for the treatment of urothelial carcinoma (UC).<sup>1,2</sup> It is comprised of human monoclonal antibody conjugated to monomethyl auristatin E (MMAE), a microtubule-disrupting agent that leads to cell-cycle arrest and apoptotic death. EV binds to a transmembrane protein on the surface of UC cells, nectin-4, which leads to internalization of MMAE into target cells.<sup>1,2</sup> Nectin-4 is expressed in the skin, where it has a role in cell-cell attachment.<sup>3</sup> Thus, disruption of nectin-4 by EV can lead to dermatologic toxicities.<sup>2,3</sup>

A few cases of dermatologic toxicities from EV have been reported in the literature outside of the clinical trial setting.<sup>2-6</sup> This case report describes the progression of a unique cutaneous drug toxicity observed in a patient treated with EV for metastatic UC. To our knowledge, no similar clinical presentation from EV has been documented, and this case also adds to the literature a severe EV-associated drug eruption that warranted drug discontinuation.

## CASE REPORT

A 73-year-old woman with high-grade metastatic papillary UC presented with skin peeling 1 day after receiving a second cycle of EV. Physical examination revealed large, nonpainful, erythematous patches with superficial desquamation along the bilateral thighs, lower portion of the legs, arms, chest, and neck (Fig 1). The patient was minimally symptomatic, and a diagnosis of exfoliative dermatitis secondary to EV was favored. Hydrocortisone cream 2.5% was prescribed for symptom management.

### Abbreviations used:

EV:	enfortumab vedotin
MMAE:	monomethyl auristatin E
SJS:	Stevens-Johnson syndrome
TEN:	toxic epidermal necrolysis
UC:	urothelial carcinoma

Continued EV therapy was advised while monitoring for further eruption progression.

Thirteen days later, prior to finishing cycle 3, the patient presented to the emergency department with worsening of exfoliative dermatitis and new bullae formation. Painful erythema acutely developed on the anterior aspects of the shins with bullae formation on the lower portion of the left leg. Physical examination showed generalized erythema on the chest, arms, back, and abdomen with large erythematous patches on the proximal aspects of the thighs and edematous plaques with multiple tense bullae on the left shin (Fig 2). Hypopigmented patches from the initial eruption remained on the trunk and extremities. No ocular, nasal, oral, or genital mucosal lesions were present.

Punch biopsies from the inferior aspect of the left shin revealed focal interface dermatitis with necrotic keratinocytes and areas of full-thickness epidermal necrosis with secondary blister formation (Figs 3 and 4). The papillary dermis exhibited a sparse infiltrate of mostly CD8+ lymphoid cells and occasional melanophages. Direct immunofluorescence was negative for IgG, IgM, IgA, C3, and fibrinogen. These findings were concerning for bullous erythema multiforme, Stevens-Johnson syndrome (SJS),

From the Department of Dermatology, Wayne State University School of Medicine, Detroit<sup>a</sup>; and Department of Dermatology, Henry Ford Health System, Detroit.<sup>b</sup>

Funding sources: None.

IRB approval status: Not applicable.

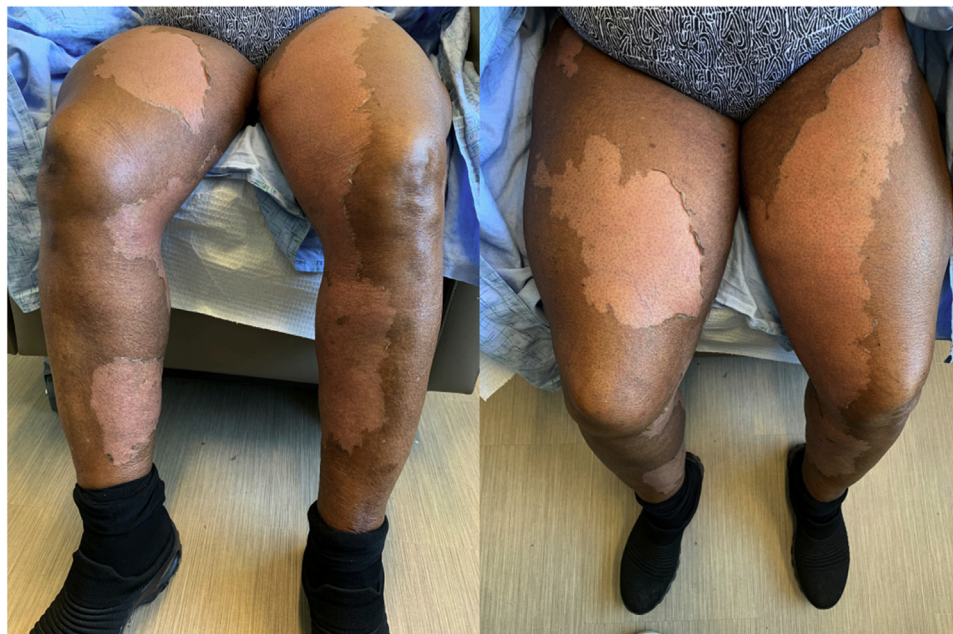
Correspondence to: Christina D. Enescu, BS, Wayne State University School of Medicine, 540 East Canfield Street, Detroit, MI 48201. E-mail: [christina.enescu@med.wayne.edu](mailto:christina.enescu@med.wayne.edu).

JAAD Case Reports 2022;21:140-3.

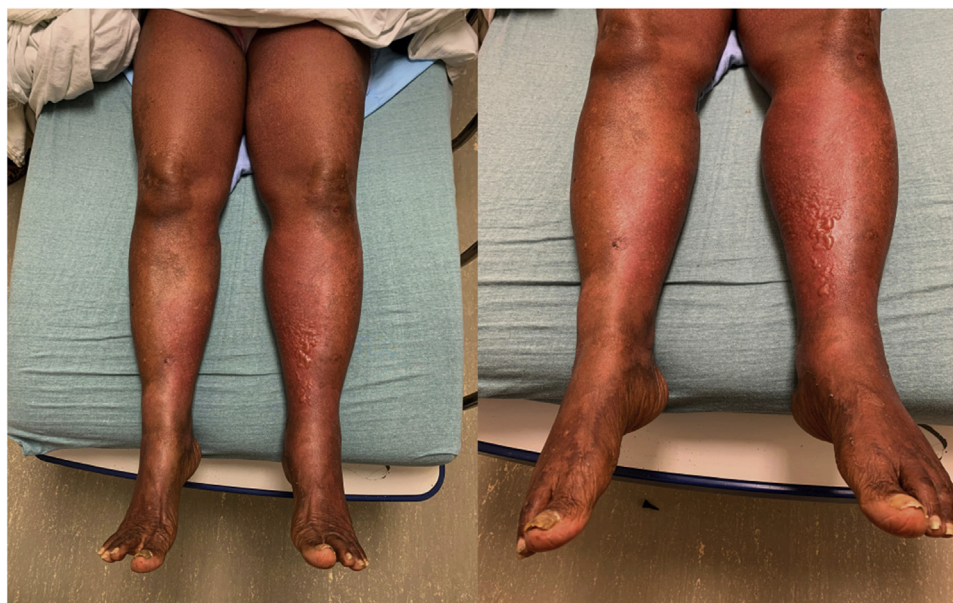
2352-5126

© 2022 by the American Academy of Dermatology, Inc. Published by Elsevier, Inc. This is an open access article under the CC BY-NC-ND license (<http://creativecommons.org/licenses/by-nc-nd/4.0/>).

<https://doi.org/10.1016/j.jdc.2022.01.005>



**Fig 1.** Exfoliative dermatitis secondary to enfortumab vedotin. Large, well-demarcated, desquamated patches along the anterior and posterior aspects of the lower parts of the legs.

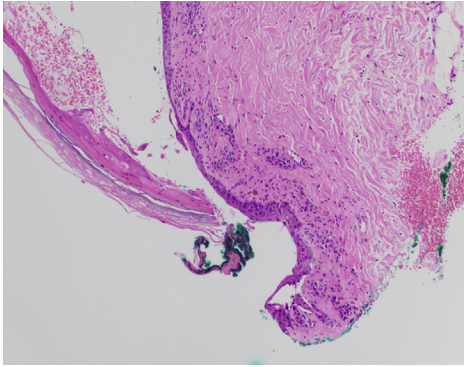


**Fig 2.** Patches of erythema on the proximal aspects of the thighs, developing into erythematous plaques with multiple tense bullae on the medial-anterior aspects of the shins bilaterally, with patches of hyperpigmentation and hypopigmentation from prior desquamation on the lower extremities.

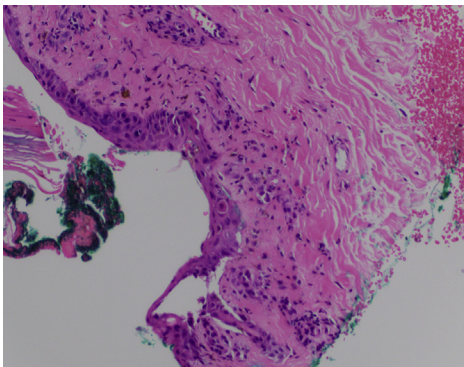
toxic epidermal necrolysis (TEN), or bullous drug eruption.

The patient had stable vital signs and no signs of mucosal involvement. However, as there are case reports of rapidly developing SJS and TEN in association with EV treatment,<sup>1-3</sup> the decision was made

to start the patient on oral prednisone 70 mg daily for 3 days in addition to topical steroids with the goal of preventing further progression. Significant decrease in pain was appreciated 24 hours following prednisone initiation. There was no further progression of bullae on physical examination the following day.



**Fig 3.** Low-power magnification demonstrating focal interface dermatitis with necrotic keratinocytes and full-thickness epidermal necrosis (Hematoxylin-eosin stain; original magnification:  $\times 100$ ).



**Fig 4.** Clearer interface dermatitis with keratinocyte necrosis (Hematoxylin-eosin stain; original magnification:  $\times 200$ ).

Further EV infusions were held. The patient was discharged within 48 hours of emergency department admission, with close clinical follow-up.

One week later, only superficial desquamation of previously involved skin was appreciated. Four weeks later, the patient's cutaneous drug toxicity had completely resolved. The final diagnosis was severe cutaneous drug toxicity with partial epidermal necrosis due to EV, likely secondary to collateral damage from expression of nectin-4 in the skin. At the time of rash resolution, there were no further plans to restart chemotherapy, as her cancer was considered to be in remission.

## DISCUSSION

Nectins are calcium-dependent cell-adhesion molecules necessary for adherens junction formation.<sup>7</sup> They are expressed on the surface of cells where they have a role in regulating cell-cell contact. EV targets nectin-4, which is expressed in epithelial malignancies, such as UC.<sup>4,8</sup> Nectin-4 is also expressed in the skin, where it has a role in epithelial

cell-cell attachment, and may explain the mechanism behind the cutaneous toxicity seen in nectin-4-targeting therapies, such as EV. Experiments with mutant nectin-4 have also shown decreased adhesiveness of epithelial cells, which further support its role in cell-cell attachment.<sup>7</sup>

MMAE is the cytotoxic conjugate of EV that works by disrupting microtubule networks within cells to inhibit mitosis and cause apoptosis. MMAE may also be an underlying cause of cutaneous toxicity since rashes are commonly observed with other antibody-drug conjugates that contain MMAE, such as glemtatumumab vedotin and polatuzumab vedotin.<sup>4,9,10</sup>

This case represents an unusual form of EV-associated interface dermatitis that is not found in the literature. Other cases that have been documented include vacuolar interface dermatitis,<sup>4</sup> erythema multiforme-like rash,<sup>2</sup> eczematoid and lichenoid eruption,<sup>5</sup> SJS,<sup>1</sup> fatal TEN,<sup>3</sup> fatal SJS-TEN overlap (SJS/TEN),<sup>2</sup> and subtle interface dermatitis prior to a fatal hypersensitivity reaction.<sup>6</sup> Our case demonstrates an exuberant form of interface dermatitis that developed secondary blisters; yet, it did not progress to a fatal hypersensitivity reaction. The exuberant bullae formation was unique, concerning, and unpredictable. Many of the above-mentioned cases lacked the diffuse erythema and bullae that were seen on our patient's examination.

Prior cases of EV-associated cutaneous toxicity have demonstrated a wide spectrum of presentation severity, with some necessitating discontinuation of EV.<sup>1-3,6</sup> There are 2 reports of fatal TEN<sup>3</sup> and SJS/TEN<sup>2</sup> despite discontinuation of EV; in both cases, delayed discontinuation likely allowed for rash progression despite treatment.<sup>2,3</sup> Other cases have been managed successfully with continued EV treatment in combination with topical and oral therapies.<sup>2,4,5</sup> Our patient's presentation was inconsistent with SJS/TEN but had the potential to evolve into a more serious reaction with continued medication use through antigen cross presentation. Due to the severity of the cutaneous eruption and concern for progression, the decision to discontinue EV treatment was made.

The variation in presentation and severity of these reactions makes it particularly challenging to determine whether treatment with EV can be safely continued, despite rash development. Characterization of these presentations and learning when to stop the medication are critical, as EV may be the last treatment option for some patients. This case highlights the importance of awareness of cutaneous toxicities associated with EV therapy and the need for close monitoring of patients for adverse skin reactions.

**Conflicts of interest**

None disclosed.

**REFERENCES:**

1. Rosenberg JE, O'Donnell PH, Balar AV, et al. Pivotal trial of enfortumab vedotin in urothelial carcinoma after platinum and anti-programmed death 1/programmed death ligand 1 therapy. *J Clin Oncol*. 2019;37(29):2592-2600. <https://doi.org/10.1200/JCO.19.01140>
2. Viscuse PV, Marques-Piubelli ML, Heberton MM, et al. Case report: Enfortumab vedotin for metastatic urothelial carcinoma: a case series on the clinical and histopathologic spectrum of adverse cutaneous reactions from fatal Stevens-Johnson syndrome/toxic epidermal necrolysis to dermal hypersensitivity reaction. *Front Oncol*. 2021;11:621591. <https://doi.org/10.3389/fonc.2021.621591>
3. Francis A, Jimenez A, Sundaresan S, Kelly B. A rare presentation of enfortumab vedotin-induced toxic epidermal necrolysis. *JAAD Case Rep*. 2020;7:57-59. <https://doi.org/10.1016/j.jidcr.2020.10.020>
4. Wu S, Adamson AS. Cutaneous toxicity associated with enfortumab vedotin treatment of metastatic urothelial carcinoma. *Dermatol Online J*. 2019;25(2):13030-qt4j44w7w6.
5. Sasaki R, Fujimura T, Lyu C, Aiba S. Severe eczematoid and lichenoid eruption with full-thickness epidermal necrosis developing from metastatic urothelial cancer treated with enfortumab vedotin. *J Dermatol*. 2020;47(12):1436-1438. <https://doi.org/10.1111/1346-8138.15577>
6. Dobry AS, Virgen CA, Hosking AM, et al. Cutaneous reactions with enfortumab vedotin: a case series and review of the literature. *JAAD Case Rep*. 2021;14:7-9. <https://doi.org/10.1016/j.jidcr.2021.05.020>
7. Fortugno P, Josselin E, Tsiakas K, et al. Nectin-4 mutations causing ectodermal dysplasia with syndactyly perturb the rac1 pathway and the kinetics of adherens junction formation. *J Invest Dermatol*. 2014;134(8):2146-2153. <https://doi.org/10.1038/jid.2014.119>
8. Challita-Eid PM, Satpayev D, Yang P, et al. Enfortumab vedotin antibody-drug conjugate targeting nectin-4 is a highly potent therapeutic agent in multiple preclinical cancer models. *Cancer Res*. 2016;76(10):3003-3013. <https://doi.org/10.1158/0008-5472.CAN-15-1313>
9. Yardley DA, Weaver R, Melisko ME, et al. EMERGE: a randomized phase II study of the antibody-drug conjugate glembatumumab vedotin in advanced glycoprotein NMB-expressing breast cancer. *J Clin Oncol*. 2015;33(14):1609-1619. <https://doi.org/10.1200/JCO.2014.56.2959>
10. Palanca-Wessels MC, Czuczman M, Salles G, et al. Safety and activity of the anti-CD79B antibody-drug conjugate polatuzumab vedotin in relapsed or refractory B-cell non-Hodgkin lymphoma and chronic lymphocytic leukaemia: a phase 1 study. *Lancet Oncol*. 2015;16(6):704-715. [https://doi.org/10.1016/S1470-2045\(15\)70128-2](https://doi.org/10.1016/S1470-2045(15)70128-2)