



Contents lists available at ScienceDirect

## International Journal of Surgery Case Reports

journal homepage: [www.casereports.com](http://www.casereports.com)

# Questioning the failure of neural crest cell migration theory in Hirschsprung's disease: A case report and literature review

Ahmed Almumtin

Saudi Board of General Surgery, Royal Commission Hospital, Jubail, Saudi Arabia

## ARTICLE INFO

## Article history:

Received 23 December 2020

Accepted 12 January 2021

Available online 16 January 2021

## Keywords:

Hirschsprung's disease

Aganglionosis

Migration theory

Case report

## ABSTRACT

**INTRODUCTION:** Segmental aganglionosis (the absence of ganglions) is a rare presentation of Hirschsprung's disease, whereby only limited segment/segments of aganglionic bowel is interposed between segments of innervated bowel, or "skip" area of normal innervations is present within an area of aganglionosis.

**PRESENTATION OF CASE:** We reported a case of a 3 day old male newborn who presented with failure to pass meconium along with progressive abdominal distension. There were skip lesions present in between. Mikulicz double barrel enterostomy was carried out, which was followed by an uneventful postoperative period. Four months later, the patient was admitted for levelling biopsies which revealed the absence of ganglions in the terminal ileum as well as in the rectosigmoid junction. But the ganglions were present in between and proximal to the terminal ileum where the previously dilated small bowel segment was resected. This presentation was contradicted the most accepted migration theory of Hirschsprung's disease.

**DISCUSSION:** As seen in our case, and in 21 other cases published between 1954–2016, we highly recommend that leveling/mapping biopsies should definitely include the cecal pole and the small bowel segments proximal to the ileocecal valve as well as the multilevel colonic biopsies down till the rectum. **CONCLUSION:** Reporting of these cases brings out interesting questions with respect to the pathogenesis and serves to highlight the existence of several variants within the spectrum of Hirschsprung's disease.

© 2021 The Author(s). Published by Elsevier Ltd on behalf of IJS Publishing Group Ltd. This is an open access article under the CC BY-NC-ND license (<http://creativecommons.org/licenses/by-nc-nd/4.0/>).

## 1. Introduction

Neural crest cells appear in the developing oesophagus at about 4 weeks of gestation and end up by the seventh week [1]. The enteric nervous system is composed of autonomic ganglia in the myenteric and the sub mucosal plexuses. In humans, vagal neural crest cells initially migrate in the outer half of the midgut mesenchyme [2]. After the entire midgut region is colonized, the vagal neural crest cells form a narrow layer close to the serosa, where the myenteric ganglia will be formed [3]. Sub mucosal plexus arises several days later from a secondary migration of the neural crest cells from the myenteric plexus. In the hindgut of mice and humans, vagal crest cells migrate in the outer part of the mesenchyme and aggregate in the region where myenteric ganglia are to be formed [2]. Sacral neural crest cells are most numerous in the distal colorectum where they constitute up to 17% of the enteric neurons [4]. The current approach towards the diagnosis and therapy of Hirschsprung's disease is usually based on a single distal aganglionic zone [5]. The aganglionosis is confined to the rectosigmoid in about 75–80% of patients [6,7]. However, in 15–20 percent of patients, aganglionosis extends proximally to the sigmoid colon

(known as a long-segment disease). In approximately 5 percent, the entire colon is affected (known as total colonic aganglionosis), and in rare cases, the small bowel may also get involved. Segmental aganglionosis as reported here and previously (Table A2), might easily get over looked or misdiagnosed as total colonic aganglionosis. In the case described below, we have reported aganglionic segments of terminal ileum, appendix and rectosigmoid, whereas rest of the colon shows the presence of microscopically normal ganglions. This unusual aganglionosis has also been referred to in the literature as "zonal aganglionosis", "segmental aganglionosis", "skip area" and "skip lesions" [8–12]. This case report therefore represents a different pattern of segmental aganglionosis. The report has been furnished in accordance with the SCARE criteria [13].

## 2. Patient information and clinical findings

A 3 day old male newborn presented to the hospital with failure to pass meconium along with progressive abdominal distension. The full-term baby boy, was born to a 33 year old lady, para 2, by caesarean section. She was not known to have any chronic medical illness and had regular antenatal visits with uneventful prenatal and natal periods. Birth weight was 2.7 kg. Initial examination revealed non-dysmorphic male newborn, without any signs of dehydration or respiratory distress, with normal vital signs. How-

E-mail address: [almumtina@rchsp.med.sa](mailto:almumtina@rchsp.med.sa)

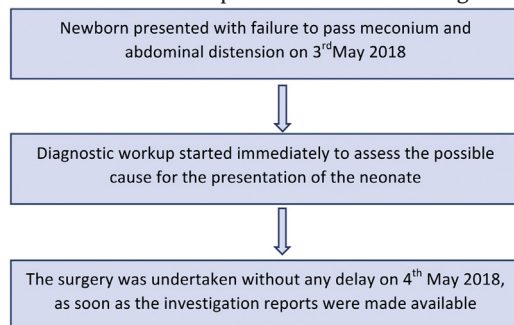
<https://doi.org/10.1016/j.ijscr.2021.01.049>

2210-2612/© 2021 The Author(s). Published by Elsevier Ltd on behalf of IJS Publishing Group Ltd. This is an open access article under the CC BY-NC-ND license (<http://creativecommons.org/licenses/by-nc-nd/4.0/>).

ever, there was marked abdominal distension. The patency of anus was established by digital rectal examination, and it did not show any gush of meconium or air.

### 3. Timeline of events

The newborn presented with failure to pass meconium and abdominal distension on 3rd May 2018. This was within 24 h following delivery by caesarean section. Soon the diagnostic workup began to investigate the cause, as the patency of anus was established on physical examination. All the investigation reports were obtained within a day following which, no delay was made to operate the neonate. The surgery was performed on 4th May 2018. The course of events has been depicted in the flowchart given below.



### 4. Diagnostic assessment

Initial Laboratory testing was unremarkable. Imaging techniques included plain abdominal antero-posterior and cross table X-rays (Figs. A1 and A2), Barium enema, and gastrografin follow-through (Figs. A3 and A4 respectively). However, barium enema reached an area within the colon, from where it failed to pass further (Fig. A3). Gastrografin follow-through with serial X-rays revealed an interruption at a fixed dilated bowel loop (Fig. A4).

### 5. Therapeutic intervention

Initial management was conservative in nature. The child was kept nil per mouth. Gastric decompression was done and intravenous fluids were started. With serial abdominal examinations and abdominal girth measurements, it was seen that the abdominal distension was progressive in nature, as a result of which he was taken for exploratory laparotomy. Necessary consents were obtained. Intra-operatively, there was a discrepancy in bowel loops and size. A hard pellet filling the ileal segment around 30 cm proximal to the ileocecal junction was noticed. Dilated small bowel segments proximal to the meconium inspissated segment about 10 cm long, and of 6 cm in diameter were present. A disused micro colony was also seen. These findings suggest meconium ileum versus Hirschsprung's disease. Dilated ileal segment (10 cm) was resected. Appendectomy was done and a full-thickness rectosigmoid biopsy was obtained and Mikulicz double-barrel enterostomy was carried out. With an uneventful postoperative period, the newborn was started on feeding formula, enterostomy started to function, and was discharged home to follow on an outpatient basis. Histopathology results came out with ganglions being present in the resected dilated small bowel segment but absent in the appendix and rectosigmoid biopsies. (G, H, I Respectively) Fig. A5.

### 6. Follow-up and outcome

Four months later following surgery, the patient was admitted for levelling biopsies. Multiple full-thickness biopsies were taken (Terminal ileum, ascending, proximal, transverse, distal transverse,

and descending colon and another biopsy from the rectosigmoid junction) (F, E, D, C, B, A respectively). Fig. A5 and Table A1. The ganglions were neither identified in the terminal ileum, nor in the rectosigmoid junction, but were present in between and proximal to the terminal ileum where the previously dilated small bowel segment was resected.

One year later, he was admitted electively for total colectomy (including the aganglionic terminal ileum) and Duhamel's Procedure. Both stoma sites were submitted to histopathology and found to contain normally appearing ganglions. After colectomy, random ascending, transverse, and descending colon biopsies were obtained, the results of which were found to be consistent with the results of the levelling biopsy.

### 7. Discussion

The theory of migration, which pertains to the cranio caudal movement of neural crest cells during the first 12 weeks of gestation, is the most accepted explanation for Hirschsprung disease. However, such cases raise questions over creditability of the migration theory, since it explains the colonic involvement with distal extension, but does not give any justification for the presence of skip lesions. Multiple plausible explanations can be put forward for this discrepancy. Variable spread of intramural ganglion cells followed by failure of "reentry" of the extramural ganglion cells during gestation resulting in skip lesions is a proposed mechanism. Also, during the extramural phase of neural crest cell migration, neural crest cells may migrate via the mesentery into the colon in addition to the expected craniocaudal neural crest cell migration. In addition to this, it can be a problem of maturation or apoptosis of the ganglion cells or both as well. As per the conventional approach, the surgical management involves resection of the aganglionic segment, which is followed either by an immediate anastomosis between the resulting two ends or a multistage procedure with the deployment of an enterostomy. However, independent of the surgical approach, if the prognosis of the patient differs from the expected outcome in postoperative period, skip lesions should be looked for. Hence, multiple biopsies of the entire length of the colon are recommended before undertaking any corrective surgery for total aganglionosis along with formal mapping of the ganglion cells. The length of such skip segment disease is unpredictable and variable as per the prior case reports. Therefore, as per the findings in our case, we strongly recommend that such preoperative biopsies should include the cecal pole and the small bowel segment proximal to the ileocecal valve as well as random biopsies throughout the length of the colon up to the rectum. As per our case, and in accordance with the 21 cases published between 1954–2016, we highly recommend that leveling/mapping biopsies should not only include the cecal pole and the small bowel segment prior to the ileocecal valve but also the multilevel colonic tissue down till the rectum.

### 8. Conclusion

In management of patients with Hirschsprung disease, presenting with total colonic aganglionosis, the possibility of segmental aganglionosis should be investigated with high suspicion. Preservation of these segments can have a positive influence on both the postoperative outcome of the patients as well as on the colonic functional movements.

### Additional information

The case is set to be published in full accordance with all the applicable policies and procedures of King Fahad Hospital Uni-

versity along with all the applicable Saudi laws and regulations including National Committee on Bio-Ethics Regulations and King Fahd of the University and IRB approval by Imam Abdul Rahman Bin Faisal University. Reference number of the committee is 2017–400-Med-NF. All the necessary procedures related to collection, recording, and reporting of data are accurate to the best of our knowledge. Due consideration was given to the privacy, health, and welfare of the research participant. We hereby confirm no conflict of interest. Also the study participant was at negligible risk. Care was taken to ensure no breach in the confidentiality of data.

**Declaration of Competing Interest**

No any conflicts of interest.

**Funding**

Self funded Research Work; No any external sponsorship.

**Ethical approval**

National Committee on Bio-Ethics Regulations and King Fahd of the University and IRB approval by Imam Abdul Rahman Bin Faisal University. Reference number of the committee is 2017–400-Med-NF.

**Consent**

Written informed consent was obtained from the parents of the study participant for publication of this Case Report and for all the accompanying images and videos.

**Author contribution**

Dr. Ahmed T Almuntnin: Main author: case concept and design, writing the paper.

**Registration of research studies**

Not Applicable.

**Guarantor**

Dr. Ahmed Almuntnin.

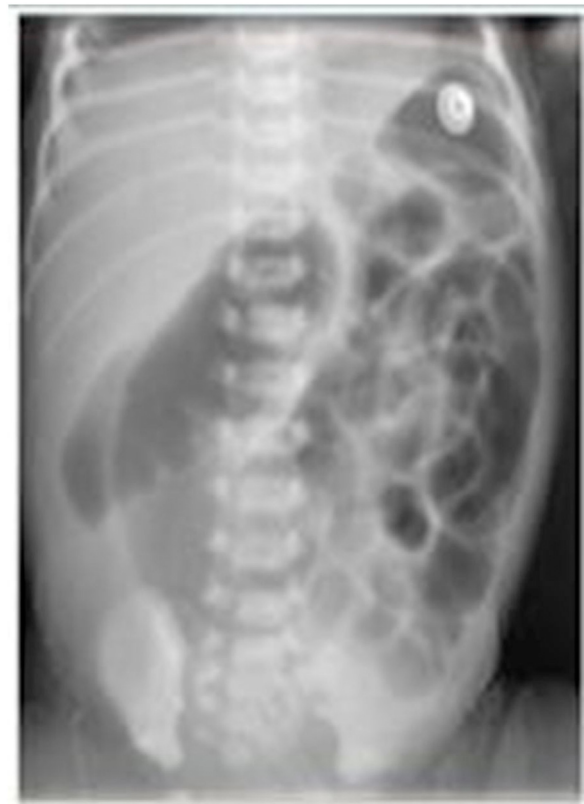**Provenance and peer review**

Not commissioned, externally peer-reviewed.

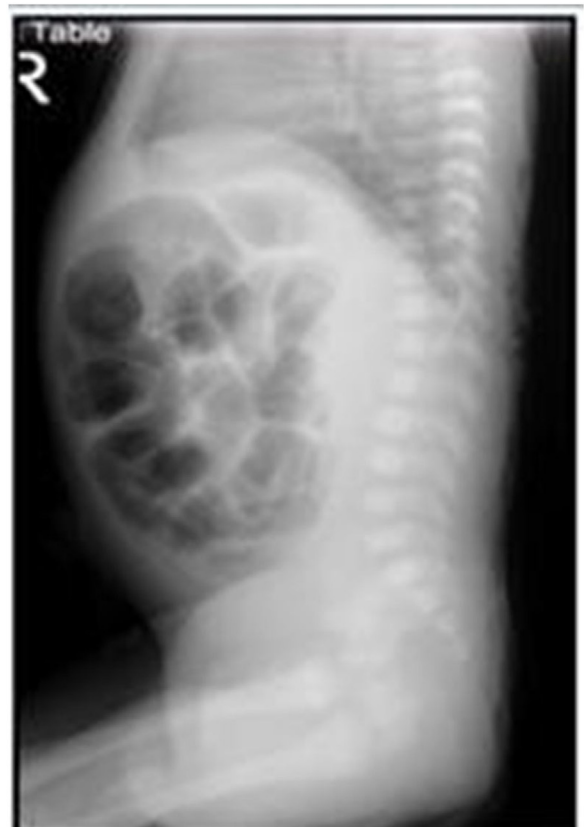**Appendix A.**

**Table A1**  
Ganglion presence in different areas.

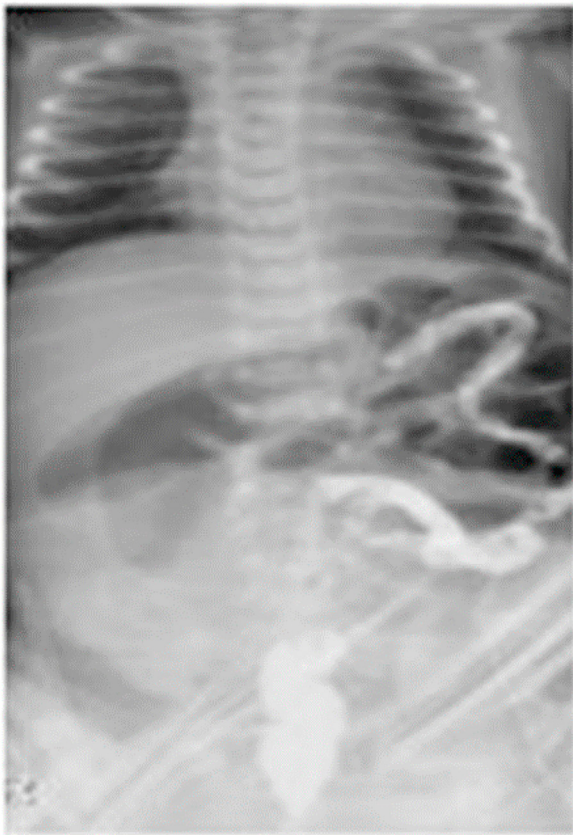Biopsied area	Ganglion presence microscopically and Calretinin stain
Terminal Ileum	Absent
Ascending colon	Present
Proximal transverse	Present
Distal transverse	Present
Descending colon	Present
Rectosigmoid junction	Absent



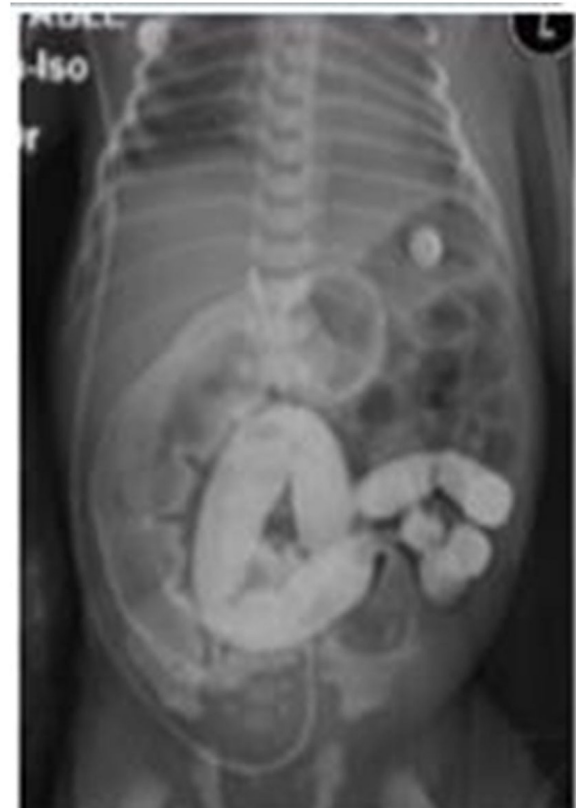**Fig. A1.** Plain abdomen X-ray showing distended bowel loops of variable sizes and no pneumoperitoneum.



**Fig. A2.** Plain abdomen X-ray cross table view, showing distended bowel loops.



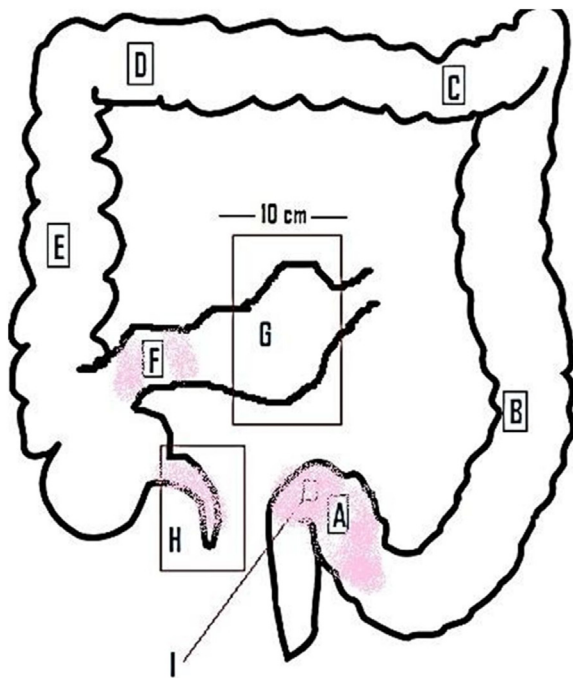
**Fig. A3.** Barium enema is showing microcolon with barium flow interrupted and an areathat might represent distal transverse colon.



**Fig. A4.** Gastrografin follow through, with an interruption of gastrografin flow at a fixed dilated distal bowel.

**Table A2**  
Studies characteristics.

Reference	Year	Gender	Number of patients	Column Head
Keefer	1954	Male	1	Rectosigmoid with skip in sigmoid
Sprinz	1961	Female	1	TCA except in transverse colon
Maclver	1972	Male	1	Rectosigmoid with skip in sigmoid
Martin	1979	Male	1	TCA except skin in transverse colon
De Chadaverian	1982	Male	1	TCA except skin in transverse colon
Yunis	1983	Male	5	TCA except skin in transverse colon
Taguchi	1983	Male	1	TCA except skin in transverse colon
Seldrenrijk	1986	Male	2	TCA with multiple skips
Anderson	1986	Male	1	TCA except skin in ascending colon
Kapur	1995	Female	2	TCA except skin in ascending colon
Yang	2005	Male	3	TCA except skin in rectum
Ziad	2006	Male	2	TCA with multiple skips
Oshio	2008	Female	1	TCA except skin in transverse colon
Puri	2010	Male	1	TCA except skin in cecum
Doi	2011	Male	1	TCA except skin in ascending colon
Burjonrappa	2012	Female	1	TCA except skin in transverse colon
Moore	2013	Male	1	TCA except skin in transverse colon
Erten	2014	Male and Female	2	Skip in right and descending colon
Ragunath	2014	Male	1	TCA except skip in hepatic flexure
Gross	2015	Male	1	TCA with skip in ascending colon and hepatic flexure
Ruiz	2016	Male	1	Skip in transverse and descending colon
				Skip in cecum, distal transverse, descending and rectum



**Fig. A5.** A scheme showing the locations of obtained biopsies from the patient's bowels.

## References

- [1] C.E. Garipey, Intestinal motility disorders and development of the enteric nervous system, *Pediatr. Res.* 49 (5) (2001) 605–613.
- [2] E. Stranzinger, M.A. DiPietro, D.H. Teitelbaum, P.J. Strouse, Imaging of total colonic Hirschsprung disease, *Pediatr. Radiol.* 38 (11) (2008) 1162–1170.
- [3] I.J. Allan, D.F. Newgreen, The origin and differentiation of enteric neurons of the intestine of the fowl embryo, *Am. J. Anat.* 157 (2) (1980) 137–154.
- [4] A.J. Burns, N.M. Douarin, The sacral neural crest contributes neurons and glia to the post-umbilical gut: spatiotemporal analysis of the development of the enteric nervous system, *Dev. Camb. Engl.* 125 (21) (1998) 4335–4347.
- [5] A.G. MacIver, R. Whitehead, Zonal colonic aganglionosis, a variant of Hirschsprung's disease, *Arch. Dis. Child.* 47 (252) (1972) 233–237.
- [6] P. Puri, M.E. Höllwarth (Eds.), *Pediatric Surgery: Diagnosis and Management*, Springer-Verlag, Berlin Heidelberg, 2009 [Internet] [cited 2020 Dec 11]. Available from: <https://www.springer.com/gp/book/9783540695592>.
- [7] J.A. Badner, W.K. Sieber, K.L. Garver, A. Chakravarti, A genetic study of Hirschsprung disease, *Am. J. Hum. Genet.* 46 (3) (1990) 568–580.
- [8] T. Oshio, Imperforate anus, malrotation, and Hirschsprung's disease with double zonal aganglionosis: an extremely rare combination, *J. Pediatr. Surg.* 43 (1) (2008) 222–226.
- [9] E. Yunis, W.K. Sieber, D.R. Akers, Does zonal aganglionosis really exist? Report of a rare variety of Hirschsprung's disease and review of the literature, *Pediatr. Pathol.* 1 (1) (1983) 33–49.
- [10] K.D. Anderson, R. Chandra, Segmental aganglionosis of the appendix, *J. Pediatr. Surg.* 21 (10) (1986) 852–854.
- [11] J.P. de Chadarevian, M. Slim, S. Akel, Double zonal aganglionosis in long segment Hirschsprung's disease with a "skip area" in transverse colon, *J. Pediatr. Surg.* 17 (2) (1982) 195–197.
- [12] S. Castle, A. Suliman, K. Shayan, K. Kling, S. Bickler, B. Losasso, Total colonic aganglionosis with skip lesions: report of a rare case and management, *J. Pediatr. Surg.* 47 (3) (2012) 581–584.
- [13] R.A. Agha, T. Franchi, C. Sohrabi, G. Mathew, A. Kerwan, SCARE Group, The SCARE 2020 guideline: updating consensus Surgical CaseReport (SCARE) guidelines, *Int. J. Surg.* (2020), S1743–9191(20)30771–30778.

## Open Access

This article is published Open Access at [sciencedirect.com](https://www.sciencedirect.com). It is distributed under the [IJSCR Supplemental terms and conditions](#), which permits unrestricted non commercial use, distribution, and reproduction in any medium, provided the original authors and source are credited.