

LETTER TO THE EDITOR

Pyoderma gangrenosum after mRNA-based SARS-CoV-2 vaccine

Dear Editor,

We describe the case of a 49-year-old man with a background of ulcerative colitis and an inoperable astrocytoma treated with a fourth-line chemotherapy by bevacizumab and lomustine. Twenty-two days after receiving the second dose of the SARS-CoV-2 Pfizer-BioNTech mRNA-vaccine Comirnaty®, he presented at the injection site a painful oedematous lesion rapidly progressing into a large necrotic ulcer with an erythematous border (Fig. 1). He had associated fever, headaches and asthenia. First, he was treated as an infectious abscess with antibiotics and surgical debridement, but the ulcer continued to worsen. We rectified the diagnosis for pyoderma gangrenosum (PG), which was successfully treated within 1 month with topical and systemic corticosteroid therapy (prednisone 1 mg/kg/d), as presented in Figure 2. Considering the good response to immunosuppressive treatment and prespecified 4 minor criteria (pathergy, papule then ulceration, peripheral erythema, inflammatory bowel disease [IBD]), diagnosis of PG was eventually retained.¹ Even if biopsy is considered as a major criterion for PG diagnosis, it was not performed to avoid the risk of further pathergy. It has to be noted that his first shot of the same vaccine was well tolerated.

Delayed local skin reactions, are a rare side-effect that usually present as a localized, transient, erythematous and oedematous plaque several days after the first or the second dose of the mRNA-based SARS-CoV-2 vaccines named 'COVID ARM'.² They do not constitute a contraindication to a second injection. IBD is a well-known risk factor for neutrophilic dermatosis as PG, and our patient had a history of ulcerative colitis.³ It has to be noted that, 2 days before PG occurrence, our patient was also treated with subcutaneous granulocyte colony-stimulating factor (G-CSF) injection in the thigh in order to prevent chemotherapy-induced neutropenia. Cases of PG occurring after G-CSF have been reported in the literature.⁴ Few cases of neutrophilic dermatosis such as Sweet syndrome have been reported with SARS-CoV-2 vaccines.⁵⁻⁹ In the World Health Organization global database of individual case safety reports 'VigiBase', after more than 11.6 billion doses of SARS-CoV-2 vaccines, 21 cases of PG have been reported with vaccines against SARS-CoV-2 (11 with the Comirnaty®-Pfizer-BioNTech vaccine, 4 with the Spikevax®-Moderna vaccine, 4 with the Vaxzevria®-AstraZeneca vaccine and 2 with the COVID-19 Janssen vaccine). To our knowledge, only one case of PG has been published in a 27-year-old patient 24 h after receiving the first dose of Comirnaty® vaccine.¹⁰ In the 'VigiBase', PG has also been reported with various vaccines mainly smallpox, pneumococcal, herpes zoster, seasonal influenza and hepatitis A vaccines. In our case, the link between mRNA-based SARS-CoV-2 vaccine and PG is suggested mainly by the PG location at the site of vaccine

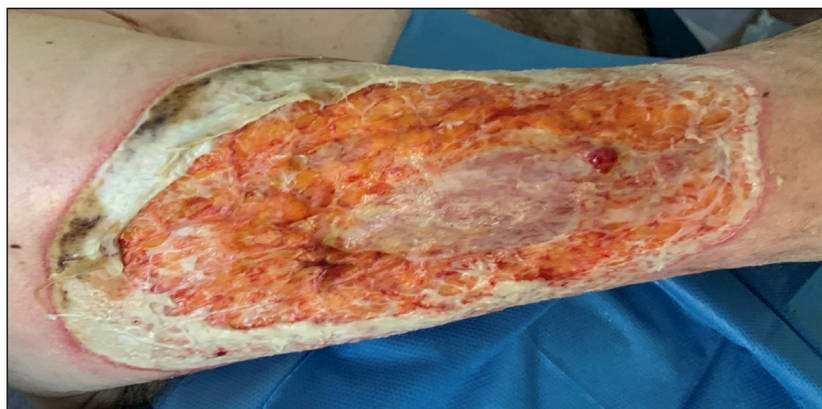


Figure 1 Dermatological aspect of pyoderma gangrenosum, located on the upper arm, 22 days after the second shot of the SARS-CoV-2 Pfizer-BioNTech mRNA vaccine.

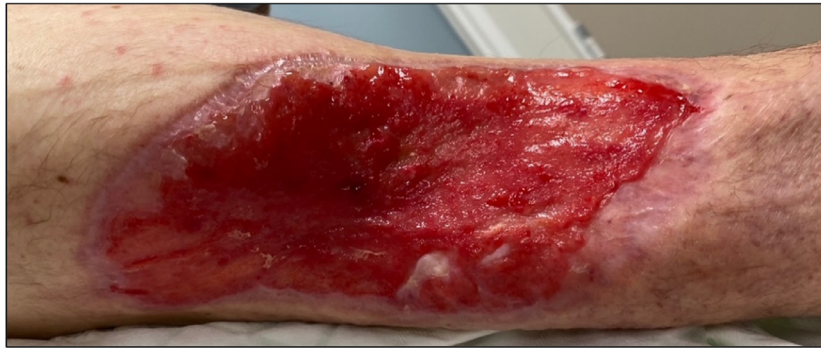

Figure 2 Evolution of pyoderma gangrenosum after being treated with topical corticosteroids and systemic steroid therapy (prednisone 1 mg/kg/day).

injection and the delay between the administration and PG occurrence. We hypothesize for our patient that the vigorous immune reaction induced by the SARS-CoV-2 vaccine triggered a pathergy phenomenon in a patient with medical (ulcerative colitis) and treatment (G-CSF) conditions favouring neutrophilic dermatosis.

In conclusion, the occurrence of PG at the site of SARS-CoV-2 vaccine injection is a rare but potential condition that clinicians should consider.

Acknowledgements

The opinions and conclusions in this study are not necessarily those of the various centres or of the WHO. Information from Vigibase comes from a variety of sources, and the probability that the suspected adverse effect is drug related is not the same in all cases.

The patient in this study has given written informed consent to the publication of his case details.

Funding sources




None.

Conflicts of interest

None declared.

Data availability statement

The data that support the findings of this study are available on request from the corresponding author.

J. Franceschi,^{1,*}  A.S. Darrigade,¹  P. Sanchez-Pena,² V. Legrain-Lifermann,³ B. Milpied¹ 

¹Department of Dermatology, Bordeaux University Hospital, Bordeaux cedex, France, ²Regional Center of Pharmacovigilance, Pharmacology

Department, Bordeaux University Hospital, Bordeaux cedex, France,

³Department of Dermatology, Dax Hospital, Dax, France

*Correspondence: J. Franceschi. E-mail: franceschijosephine@gmail.com

References

- Maverakis E, Ma C, Shinkai K *et al*. Diagnostic criteria of ulcerative pyoderma gangrenosum: a Delphi consensus of international experts. *JAMA Dermatol* 2018; **154**: 461–466.
- McMahon DE, Amerson E, Rosenbach M *et al*. Cutaneous reactions reported after Moderna and Pfizer COVID-19 vaccination: a registry-based study of 414 cases. *J Am Acad Dermatol* 2021; **85**: 46–55.
- Kridin K, Cohen AD, Amber KT. Underlying systemic diseases in pyoderma gangrenosum: a systematic review and meta-analysis. *Am J Clin Dermatol* 2018; **19**: 479–487.
- Dereure O, Hillaire-Buys D, Guilhou JJ. Neutrophil-dependent cutaneous side-effects of leucocyte colony-stimulating factors: manifestations of a neutrophil recovery syndrome? *Br J Dermatol* 2004; **150**: 1228–1230.
- Darrigade AS, Théophile H, Sanchez-Pena P *et al*. Sweet syndrome induced by SARS-CoV-2 Pfizer-BioNTech mRNA vaccine. *Allergy* 2021; **76**: 3194–3196.
- Merrill ED, Kashem SW, Amerson EH *et al*. Association of facial pustular neutrophilic eruption with messenger RNA-1273 SARS-CoV-2 vaccine. *JAMA Dermatol* 2021; **157**: 1128–1130.
- Torrealba-Acosta G, Martin JC, Huttenbach Y *et al*. Acute encephalitis, myoclonus and sweet syndrome after mRNA-1273 vaccine. *BMJ Case Rep* 2021; **14**: e243173.
- Sechi A, Pierobon E, Pezzolo E *et al*. Abrupt onset of sweet syndrome, pityriasis rubra pilaris, pityriasis lichenoides et varioliformis acuta and erythema multiforme: unravelling a possible common trigger, the COVID-19 vaccine. *Clin Exp Dermatol*. 2021; **47**: 437–440.
- Baffa ME, Maglie R, Giovannozzi N *et al*. Sweet syndrome following SARS-CoV2 vaccination. *Vaccine* 2021; **9**: 1212.
- Barry M, AlRajhi A, Aljerian K. Pyoderma gangrenosum induced by BNT162b2 COVID-19 vaccine in a healthy adult. *Vaccine* 2022; **10**: 87.

DOI: 10.1111/jdv.18389