



Dupilumab-associated cicatrizing ocular disease

Amit K. Reddy^{*}, Scott G. Hauswirth, Darren G. Gregory, Sophie D. Liao, Alan G. Palestine

Department of Ophthalmology, University of Colorado School of Medicine, Aurora, CO, USA

ARTICLE INFO

Keywords:

Cicatrizing conjunctivitis
Dupilumab
Pseudophthimoid
Atopic dermatitis

ABSTRACT

Purpose: To describe three cases of bilateral cicatrizing conjunctivitis associated with dupilumab treatment for atopic dermatitis.

Observations: Case 1 is a 69 year-old male with a history of mild, stable cicatrizing conjunctivitis thought to be secondary to atopic dermatitis. His cicatrizing disease progressed significantly after starting dupilumab, and then stabilized after dupilumab was discontinued. Case 2 is a 72 year-old male who presented with bilateral cicatrizing conjunctivitis. His symptoms of ocular erythema and irritation started shortly after initiating dupilumab for atopic dermatitis. The dupilumab was discontinued and the patient's symptoms resolved and ocular surface scarring stabilized. Case 3 is a 47 year-old male with a history of allergic conjunctivitis who was found to have new onset unilateral symblepharon approximately 12 months after starting dupilumab for atopic dermatitis. The dupilumab was discontinued and his ocular disease stabilized. However, his cutaneous symptoms worsened significantly, so dupilumab was restarted at half the previous dose. His atopic dermatitis symptoms improved and cicatrizing conjunctivitis remained stable on this regimen.

Conclusions and importance: Cicatrizing conjunctivitis with symblepharon formation distinct from ocular cicatricial pemphigoid is a potential side effect of dupilumab therapy for atopic dermatitis. Progression of the cicatrization appears to halt with discontinuation, or potentially dose reduction, of dupilumab.

1. Introduction

Dupilumab is a monoclonal antibody approved for use in the treatment of three conditions: atopic dermatitis, moderate-to-severe asthma, and chronic rhinosinusitis with nasal polyposis. Dupilumab binds to the alpha-chain of the interleukin (IL)-4 receptor, thus inhibiting signaling of IL-4 and IL-13.¹ While considered a safe long-term medication for the treatment of these conditions, dupilumab has been associated with conjunctivitis of varying severity. Although most cases of conjunctivitis are mild and transitory, some require long-term topical anti-inflammatory medications.² Even more uncommon is the development of cicatrizing conjunctivitis in the setting of dupilumab use.²⁻⁴ Herein we present three such cases in patients with atopic dermatitis.

2. Findings

2.1. Case 1

A 69 year-old male presented with several years of bilateral eye redness, irritation, and itching in the setting of known allergic

conjunctivitis. His past medical history was significant for atopic dermatitis. He was previously treated with topical and oral corticosteroids. Initial exam in our clinic revealed bilateral ocular surface dryness, blepharitis, and inferior forniceal shortening, thought to be secondary to atopic dermatitis. The ocular surface initially improved with oral doxycycline and topical cyclosporine 0.05% emulsion. The patient was then started on dupilumab 300 mg every two weeks for his atopic dermatitis. Follow-up two months after initiation showed progression of forniceal shortening and new symblepharon bilaterally (Fig. 1). The patient underwent conjunctival biopsy, with histopathology showing only non-specific inflammation. Direct immunofluorescence testing (DIF) was not performed. His cicatrization continued to worsen over the following few months. After discussion with his allergist, the dupilumab was discontinued. His symptoms of redness and irritation improved, and his cicatrizing conjunctivitis stabilized with no further progression on follow-up 18 months later.

2.2. Case 2

A 72 year-old male presented with bilateral eye redness and

^{*} Corresponding author. University of Colorado School of Medicine, Department of Ophthalmology, 1675 Aurora Court, F731, Aurora, CO, 80045, USA.

E-mail address: amit.reddy@cuanschutz.edu (A.K. Reddy).

<https://doi.org/10.1016/j.ajoc.2022.101528>

Received 21 October 2021; Received in revised form 11 March 2022; Accepted 2 April 2022

Available online 9 April 2022

2451-9936/© 2022 The Authors. Published by Elsevier Inc. This is an open access article under the CC BY-NC-ND license (<http://creativecommons.org/licenses/by-nc-nd/4.0/>).

irritation starting two years prior. The symptoms began approximately four months after starting dupilumab 300 mg every two weeks for atopic dermatitis. He was previously treated with topical cyclosporine 0.09% solution and topical fluorometholone 0.1%. Initial exam in our clinic showed bilateral conjunctival injection, inferior symblepharon, and lower eyelid cicatricial entropion. The patient underwent conjunctival biopsy, which showed non-specific inflammation and negative DIF. In consultation with his allergist, dupilumab was discontinued. The patient's ocular symptoms improved significantly following this, and there was no further progression of his symblepharon over two years of follow-up. He was able to undergo successful surgical correction of his bilateral lower eyelid entropion.

2.3. Case 3

A 47 year-old male presented with new-onset right upper eyelid ptosis. He had been followed at our eye clinic for the prior three years for bilateral allergic conjunctivitis and treated with topical anti-histamine and corticosteroid eyedrops. On exam, he was found to have right eye superior and inferior symblepharon and forniceal shortening that had not been present on prior exams. On further history, it was discovered that the patient had been started on dupilumab 300 mg every two weeks approximately 12 months prior for atopic dermatitis. Conjunctival biopsy was performed, with pathology showing non-specific inflammation and negative DIF. The patient's dupilumab was discontinued and his conjunctival scarring stabilized for the next one year. However, his symptoms related to atopic dermatitis worsened. The decision was made to re-start dupilumab at half his prior dose (300 mg every four weeks), and he was also started on topical cyclosporine 0.09% solution. The patient's conjunctival scarring remained stable with this regimen after one year of follow-up, and he underwent successful ptosis repair surgery.

3. Discussion

We present three cases of cicatrizing conjunctivitis associated with dupilumab therapy for atopic dermatitis.

Conjunctivitis is a common ocular side effect of dupilumab, with rates in initial trials ranging up to 28%.^{1,5} Similar results have been found in retrospective reviews of patients on dupilumab for atopic dermatitis.^{6,7} Fortunately, many of these case are mild and only require short courses of topical lubrication, corticosteroids, and occasionally other topical anti-inflammatory medications such as cyclosporine or tacrolimus.^{2,7,8} The side effect of conjunctivitis appears to be more common in patients who are on dupilumab for atopic dermatitis, as opposed to other indications, and in patients who have an additional history of atopic keratoconjunctivitis.^{9,10}

There have previously been four cases of cicatrizing conjunctivitis associated with dupilumab reported in the literature.²⁻⁴ Dupilumab therapy was stopped in one case with stabilization of the conjunctival scarring.³ Levine et al. reported a case of cicatrizing conjunctivitis in a patient who wished to continue dupilumab given the benefits for his atopic dermatitis. The frequency of dupilumab was extended from every two weeks to every four weeks and there was no progression of the cicatrizing disease. Both cases of cicatrizing conjunctivitis reported by Popiela et al. were continued on dupilumab and treated with topical anti-inflammatory medications.

Two of the three patients presented here had negative conjunctival biopsy with both histopathology and DIF in the evaluation for ocular cicatricial pemphigoid (OCP), while with one patient (Case 1), only histopathology was performed. No patients had involvement of other mucous membranes. Dupilumab was discontinued in two of the three patients with stabilization of conjunctival scarring. The third patient was re-started on dupilumab at decreased frequency with no progression of cicatrization on this regimen, but with improvement in his cutaneous atopic disease, similar to the patient reported by Levine et al.

The mechanism of dupilumab-related conjunctivitis exacerbation remains unknown. Since conjunctivitis is a common event in atopic

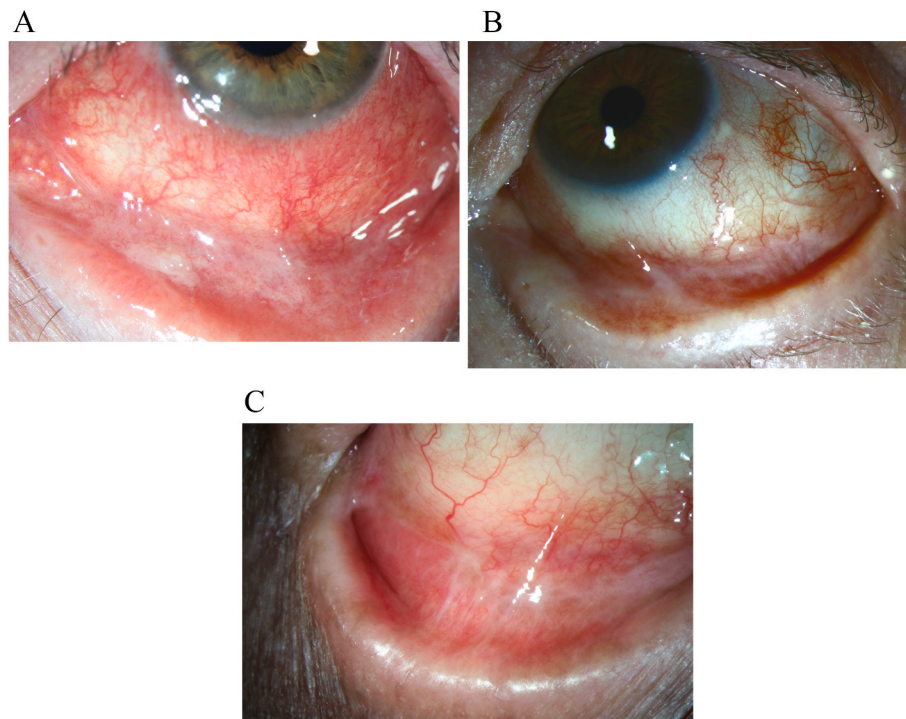


Fig. 1. A. **Case 1.** Left eye with conjunctival injection, inferior forniceal shortening, and new symblepharon after starting dupilumab for atopic dermatitis. Fig. 1B. **Case 2.** Left eye with inferior forniceal shortening, symblepharon, and sub-conjunctival fibrosis after starting dupilumab for atopic dermatitis. Fig. 1C. **Case 3.** Right eye with new inferior forniceal shortening, symblepharon, and sub-conjunctival fibrosis after starting dupilumab for atopic dermatitis.

dermatitis but is not associated with the other conditions where dupilumab is indicated, perhaps dupilumab has a paradoxical effect on atopic dermatitis-related conjunctivitis. It is possible that although the drug improves atopic dermatitis, it exacerbates the associated atopic conjunctivitis. We suggest that the conjunctival cicatrization here represents an exacerbation of atopic conjunctivitis in association with dupilumab use, leading to symblepharon formation in rare cases. The cessation of patient symptoms and symblepharon progression upon discontinuing dupilumab in our and others' reports supports the concept that this is ocular pseudo-pemphigoid related to dupilumab in patients with atopic dermatitis.

4. Conclusions

Our series emphasizes the importance of monitoring for this more serious adverse effect of dupilumab therapy. A broad differential, including OCP, should be maintained on identifying cicatrizing ocular surface disease. The diagnosis of dupilumab-associated cicatrizing conjunctivitis relies on the understanding that although the atopic dermatitis may be improving with treatment, the conjunctival scarring is paradoxically worsening. Biopsy to exclude true ocular pemphigoid may be indicated. It is reassuring that in the cases reported thus far, progression has been halted with discontinuation or dose reduction of dupilumab.

Patient consent

Consent to publish the case series was not obtained. This paper does not contain any personal information that could identify the patient. The retrospective chart review received exempt approval by the Colorado Multi-institutional Review Board and conformed to the Declarations of Helsinki.

Funding

Supported in part by an unrestricted grant to the University of Colorado Department of Ophthalmology from Research to Prevent Blindness, New York, NY, and by the center for ocular inflammation at the University of Colorado Department of Ophthalmology.

Authorship

All authors attest that they meet the current ICMJE criteria for

authorship.

Declaration of competing interest

No financial disclosure or conflicting relationship exists for any author.

Acknowledgments

None.

References

1. Simpson EL, Bieber T, Guttman-Yassky E, et al. Two phase 3 trials of dupilumab versus placebo in atopic dermatitis. *N Engl J Med*. Dec 15 2016;375(24):2335–2348. <https://doi.org/10.1056/NEJMoa1610020>.
2. Popiela MZ, Barbara R, Turnbull AMJ, et al. Dupilumab-associated ocular surface disease: presentation, management and long-term sequelae. *Eye (Lond)*. Jan 28 2021;doi:10.1038/s41433-020-01379-9.
3. Barnes AC, Blandford AD, Perry JD. Cicatricial ectropion in a patient treated with dupilumab. *Am J Ophthalmol Case Rep*. 2017;7:120–122. <https://doi.org/10.1016/j.ajoc.2017.06.017>.
4. Levine RM, Tattersall IW, Gaudio PA, King BA. Cicatrizing blepharoconjunctivitis occurring during dupilumab treatment and a proposed algorithm for its management. *JAMA Dermatol*. Dec 1 2018;154(12):1485–1486. <https://doi.org/10.1001/jamadermatol.2018.3427>.
5. Blauvelt A, de Bruin-Weller M, Gooderham M, et al. Long-term management of moderate-to-severe atopic dermatitis with dupilumab and concomitant topical corticosteroids (LIBERTY AD CHRONOS): a 1-year, randomised, double-blinded, placebo-controlled, phase 3 trial. *Lancet*. Jun 10 2017;389(10086):2287–2303. [https://doi.org/10.1016/S0140-6736\(17\)31191-1](https://doi.org/10.1016/S0140-6736(17)31191-1).
6. Maudinet A, Law-Koune S, Duret C, Lasek A, Modiano P, Tran THC. Ocular surface diseases induced by dupilumab in severe atopic dermatitis. *Ophthalmol Ther*. 2019;8(3):485–490. <https://doi.org/10.1007/s40123-019-0191-9>.
7. Nahum Y, Mimouni M, Livny E, Bahar I, Hodak E, Leshem YA. Dupilumab-induced ocular surface disease (DIOSD) in patients with atopic dermatitis: clinical presentation, risk factors for development and outcomes of treatment with tacrolimus ointment. *Br J Ophthalmol*. 2020;104(6):776–779. <https://doi.org/10.1136/bjophthalmol-2019-315010>.
8. Bohner A, Topham C, Strunck J, et al. Dupilumab-associated ocular surface disease: clinical characteristics, treatment, and follow-up. *Cornea*. May 1 2021;40(5):584–589. <https://doi.org/10.1097/ICO.0000000000002461>.
9. Akinlade B, Guttman-Yassky E, de Bruin-Weller M, et al. Conjunctivitis in dupilumab clinical trials. *Br J Dermatol*. 2019;181(3):459–473. <https://doi.org/10.1111/bjd.17869>.
10. Bansal A, Simpson EL, Paller AS, et al. Conjunctivitis in dupilumab clinical trials for adolescents with atopic dermatitis or asthma. *Am J Clin Dermatol*. 2021;22(1):101–115. <https://doi.org/10.1007/s40257-020-00577-1>.