



# Role of Permeability Surface Area Product in Grading of Brain Gliomas using CT Perfusion

Ira Agrawal<sup>1</sup> Shahina Bano<sup>1</sup> Ajay Chaudhary<sup>2</sup> Arvind Ahuja<sup>3</sup>

<sup>1</sup>Department of Radiodiagnosis, PGIMER, Dr. RML Hospital, New Delhi, India

<sup>2</sup>Department of Neurosurgery, PGIMER, Dr. RML Hospital, New Delhi, India

Asian J Neurosurg 2023;18:751–760.

Address for correspondence Shahina Bano, MD, DNB, Professor, Department of Radiodiagnosis, PGIMER, Dr. RML Hospital, New Delhi-110001, India (e-mail: dr\_shahinaindia@yahoo.com).

<sup>3</sup>Department of Pathology, PGIMER, Dr. RML Hospital, New Delhi, India

## Abstract

**Purpose** The aim of this study was to evaluate the role of permeability surface area product in grading brain gliomas using computed tomography (CT) perfusion

**Materials and Methods** CT perfusion was performed on 33 patients with brain glioma diagnosed on magnetic resonance imaging. Of these, 19 had high-grade glioma and 14 had low-grade glioma on histopathological follow-up. CT perfusion values were obtained and first compared between the tumor region and normal brain parenchyma. Then the relative values of perfusion parameters were compared between high- and low-grade gliomas. Cut-off values, sensitivity, specificity, and strength of agreement for each parameter were calculated and compared subsequently. A conjoint factor (permeability surface area product + cerebral blood volume) was also evaluated since permeability surface area product and cerebral blood volume are considered complimentary factors for tumor vascularity.

**Results** All five perfusion parameters namely permeability surface area product, cerebral blood volume, cerebral blood flow, mean transit time, and time to peak were found significantly higher in the tumor region than normal brain parenchyma. Among these perfusion parameters, only relative permeability surface area product and relative cerebral blood volume were found significant in differentiating high- and low-grade glioma. Moreover, relative permeability surface area product was significantly better than all other perfusion parameters with highest sensitivity and specificity (97.74 and 100%, respectively, at a cut-off of 9.0065). Relative permeability surface area product had a very good agreement with the histopathology grade. The conjoint factor did not yield any significant diagnostic advantage over permeability surface area product.

**Conclusion** Relative permeability surface area product and relative cerebral blood volume were helpful in differentiating high- and low-grade glioma; however, relative permeability surface area product was significantly better than all other perfusion parameters. Grading brain gliomas using relative permeability surface area product can add crucial value in their management and prognostication; hence, it should be evaluated in the routine CT perfusion imaging protocol.

## Keywords

- ▶ CT perfusion
- ▶ brain glioma
- ▶ permeability surface area
- ▶ cerebral blood volume
- ▶ cerebral blood flow
- ▶ mean transit time
- ▶ time to peak
- ▶ conjoint factor

article published online  
November 7, 2023

DOI <https://doi.org/10.1055/s-0043-1774820>.  
ISSN 2248-9614.

© 2023. Asian Congress of Neurological Surgeons. All rights reserved.

This is an open access article published by Thieme under the terms of the Creative Commons Attribution-NonDerivative-NonCommercial-License, permitting copying and reproduction so long as the original work is given appropriate credit. Contents may not be used for commercial purposes, or adapted, remixed, transformed or built upon. (<https://creativecommons.org/licenses/by-nc-nd/4.0/>)

Thieme Medical and Scientific Publishers Pvt. Ltd., A-12, 2nd Floor, Sector 2, Noida-201301 UP, India

## Introduction

Brain tumors account for 2% of all malignancies, with glioma being the most common intra-axial primary central nervous system tumor.<sup>1</sup> Clinical profile of patients with glioma may range from being completely asymptomatic to a comatose state since gliomas are extremely heterogeneous tumors ranging from benign slow growing astrocytoma to highly aggressive glioblastoma.<sup>2</sup>

Estimation of the grade of a glioma is imperative in deciding the management plan. Surgical resection is the mainstay of management wherever feasible. Patients with high-grade glioma are also administered adjuvant chemoradiation therapy. The chemoradiation therapy regimen varies considerably with the grade of glioma.<sup>3,4</sup> The prognosis is considered to be worse as the grade progresses.<sup>5</sup>

The current gold standard for preoperative grading of gliomas is histopathological evaluation of the tissue sample obtained by stereotactic biopsy. There are many limitations involved with this procedure like sampling error, inter-observer bias, and availability of a wide variety of classification systems. Moreover, stereotactic biopsy being an invasive procedure is associated with complications such as intratumoral hematoma, neurological deficits, and associated morbidity.<sup>6</sup>

Since gliomas are very infiltrative tumors, it is helpful to get an overall picture of the tumor characteristics in vivo, which can be achieved by imaging. Two of the most important factors for determining the malignancy of gliomas are their ability to infiltrate the brain parenchyma and to recruit or synthesize vascular networks for their growth, that is, neoangiogenesis. Malignant brain tumors are characterized by neoangiogenesis, having a higher proportion of immature and highly permeable vessels.<sup>7,8</sup>

Quantitative estimates of various perfusion parameters (imaging biomarkers) help in assessing the degree of neoangiogenesis and therefore help in estimating the tumor grade. Traditionally, perfusion imaging of brain tumors was performed with magnetic resonance (MR) imaging.<sup>6</sup> However, computed tomography perfusion (CTP) can serve as a better alternative to MR perfusion as it provides a linear relationship between density changes and tissue concentration of a contrast agent, has better spatial resolution, wider availability, faster scanning times, and low cost compared with MR perfusion. CTP is not affected by susceptibility artifact generated by hemorrhage or mineral deposits, a limitation with MR perfusion. CTP also has the advantage of being easily repeatable unlike invasive procedures.<sup>9,10</sup>

Various perfusion parameters can be obtained by using CTP with a single acquisition, namely cerebral blood flow (CBF), cerebral blood volume (CBV), mean transit time (MTT), time to peak (TTP), and permeability surface area product (PS). CBV, CBF, MTT, and TTP parameters are related to flow dynamics, whereas microvascular permeability is assessed by measuring PS. A conjoint factor (PS + CBV) represents the surrogate markers for microvascular permeability and flow dynamics.<sup>9,11</sup>

There is a paucity of literature in evaluating the role of PS in grading gliomas with no unanimous consensus regarding the most reliable parameter. Hence, this study was undertaken to evaluate the most reliable perfusion parameter in differentiating high- and low-grade gliomas.

## Materials and Methods

### Study Setting

This analytical cross-sectional study was conducted in the Department of Radiodiagnosis after obtaining ethical clearance from our institutional ethical committee. 33 patients of brain glioma diagnosed on MR imaging from November 1, 2018 to July 31, 2020 after signing a written consent were included in the study. Postoperative patients, pregnant or lactating females, and patients with impaired renal function or contrast allergy were excluded from the study.

The patients included in the study were between 19 and 77 years of age, with the mean age of presentation being 32.33 years. There was a male preponderance with 23 males and 10 females.

### CT Perfusion Acquisition

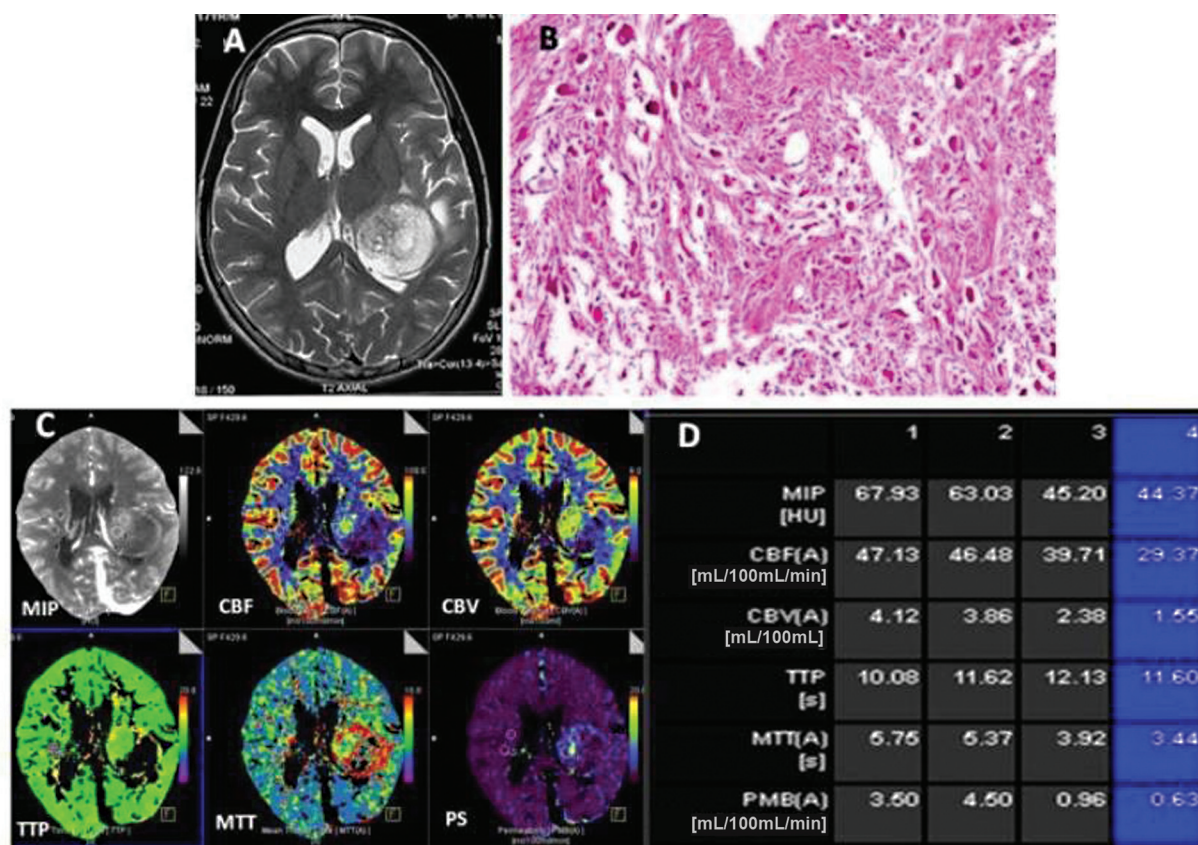
The study was performed on 128-slice dual-source CT scanner (Somatom Definition Flash Siemens, Erlanger, Germany). The patients were made to lie supine with head still. Dynamic perfusion study was performed, after injection of 40 mL nonionic contrast medium, Iomeron (Iomeprol 400 mg of iodine/mL) with flow rate of 5.5 mL/s via an 18-gauge cannula by using a power injector. Scanning was initiated after a 4 seconds delay from the start of injection and images were acquired for a total duration of 40 seconds, with total coverage area of 10 cm. CT parameters used to acquire dynamic data were 0.28 seconds gantry rotation time, 80 kVp, 180 mAs. Multiple time points were obtained with cycle time of 1.5 seconds.

### Post-Processing

Reconstruction and post-processing were done to generate CTP maps using inbuilt syngo volume perfusion CT neuro (VPCT Neuro) software. Reconstructed section thickness was 5 mm with 3 mm increment. Regions of interest (ROI) for the tumor were hand drawn. In the presence of multiple tumors, ROIs were drawn for all tumors in the scanning range. ROIs were also drawn in the background brain parenchyma that acted as control.

Perfusion values for the tumor and background brain parenchyma including CBF, CBV, MTT, TTP, and capillary PS were calculated and displayed as tables and functional maps of CBF, CBV, MTT, TTP, and PS. Relative values of the parameters were calculated and compared to the control values. The tumor grade was predicted, based upon these relative perfusion values.

After tumor biopsy or resection, histopathological grade was formulated, which was correlated with the CTP grade. Sensitivity, specificity, predictive values, and diagnostic accuracy of PS were calculated and compared with other CTP parameters.



**Fig. 1** (A) A 20-year-old male presented with pilocytic astrocytoma (World Health Organization grade I). T2-weighted imaging, (B) histopathology, (C) computed tomography perfusion (CTP) maps, (D) and CTP parameters (D). CBF, cerebral blood flow; CBV, cerebral blood volume; MIP, maximum intensity projection; MTT, mean transit time; PMB, permeability; TTP, time to peak.

### Statistical Methods

Categorical variables were presented in number and percentage (%) and continuous variables were presented as mean  $\pm$  standard deviation and median. Normality of data was tested by Kolmogorov–Smirnov test. If the normality was rejected, then nonparametric test was used.

Statistical tests were applied as follows:

1. Quantitative variables were compared using independent *t*-test/Mann–Whitney U test (when the data sets were not normally distributed) between the two groups and paired *t*-test/Wilcoxon signed rank test was used for comparison between lesion and control.
2. Receiver operating characteristic (ROC) curve was used to find out cut-off point of parameters for predicting high grade. Delong test was used for comparison of area under the curve between perfusion parameters.
3. Inter-rater kappa agreement was used to find the strength of agreement between perfusion parameters findings and actual histopathological examination (HPE) findings. A *p*-value of 0.05 was considered statistically significant.

The data was entered in MS EXCEL spreadsheet and analysis was done using Statistical Package for Social Sciences version 21.0.

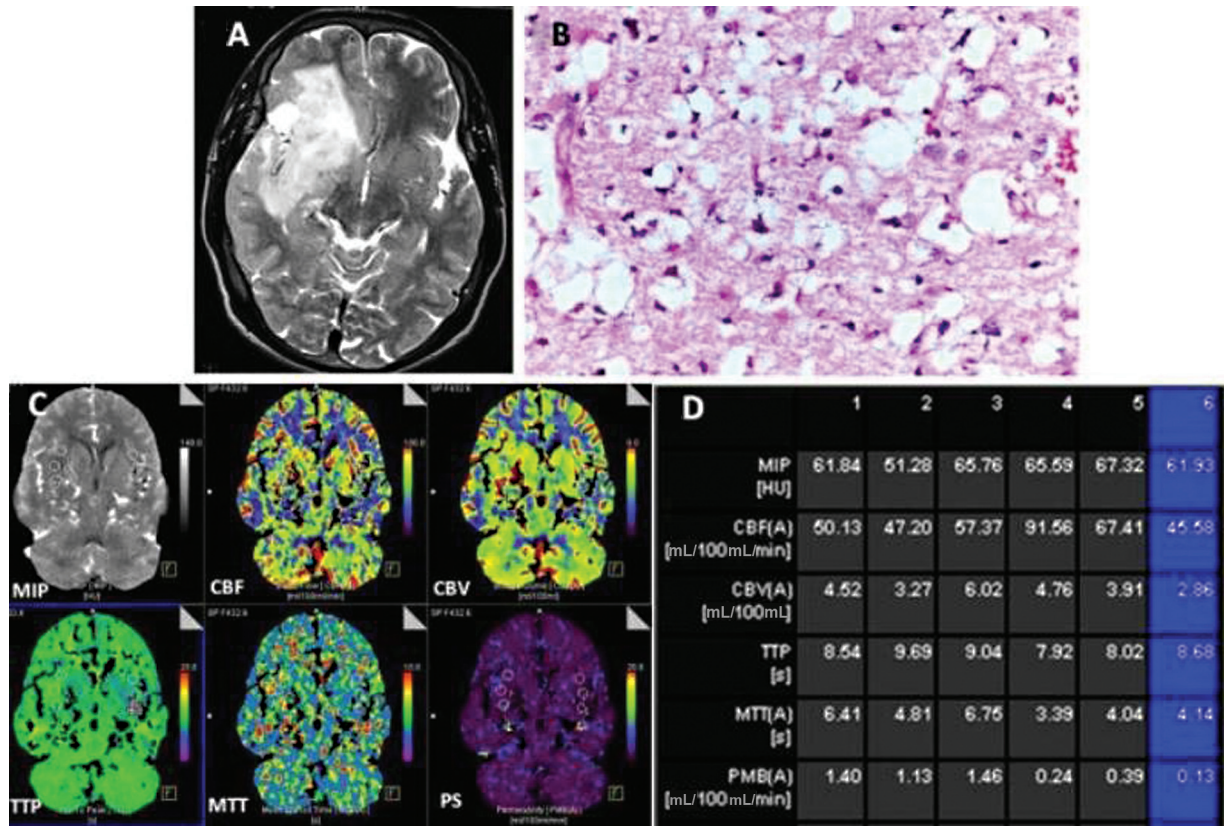
### Results and Observations

In our study, the most common clinical presentation was hemiparesis (45%) followed by seizures (39%) and headache (30.30%). Most of the gliomas (91%) were located in the supratentorial compartment, frontal lobe being the most common site (18%) followed by parietal lobe (15.15%) and frontoparietal lobe (15.15%).

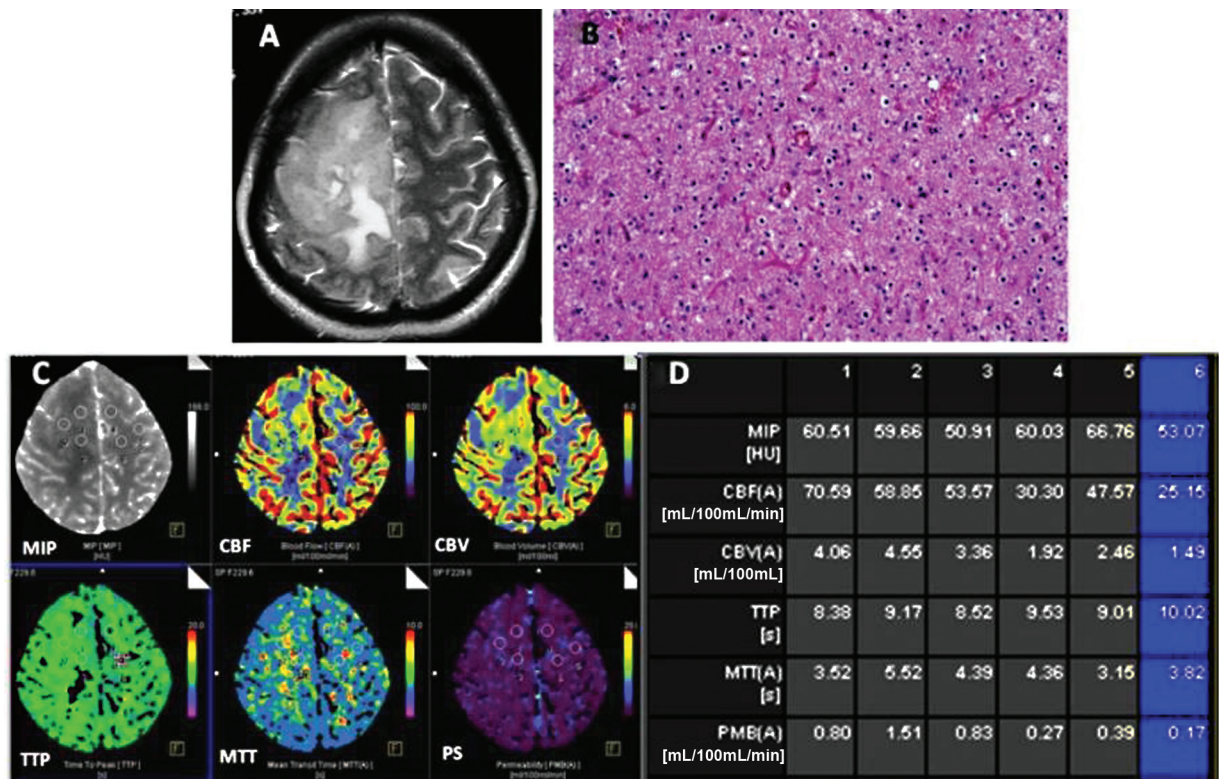
On histopathology, out of the 33 patients, 19 had high-grade glioma (grade III and IV), while 14 patients had low-grade glioma (grade I and II). Glioblastoma (42.42%) was the most common tumor phenotype followed by diffuse astrocytoma (24.24%) and pilocytic astrocytoma (12.12%). CT perfusion images of seven cases representing the spectrum of brain gliomas obtained in our study have been shown in **Figs. 1 to 7**.

On comparing the five perfusion parameters between the tumor region and background normal brain parenchyma, all the five parameters had significantly higher values (*p*-value  $< 0.05$ ) in the tumor region.

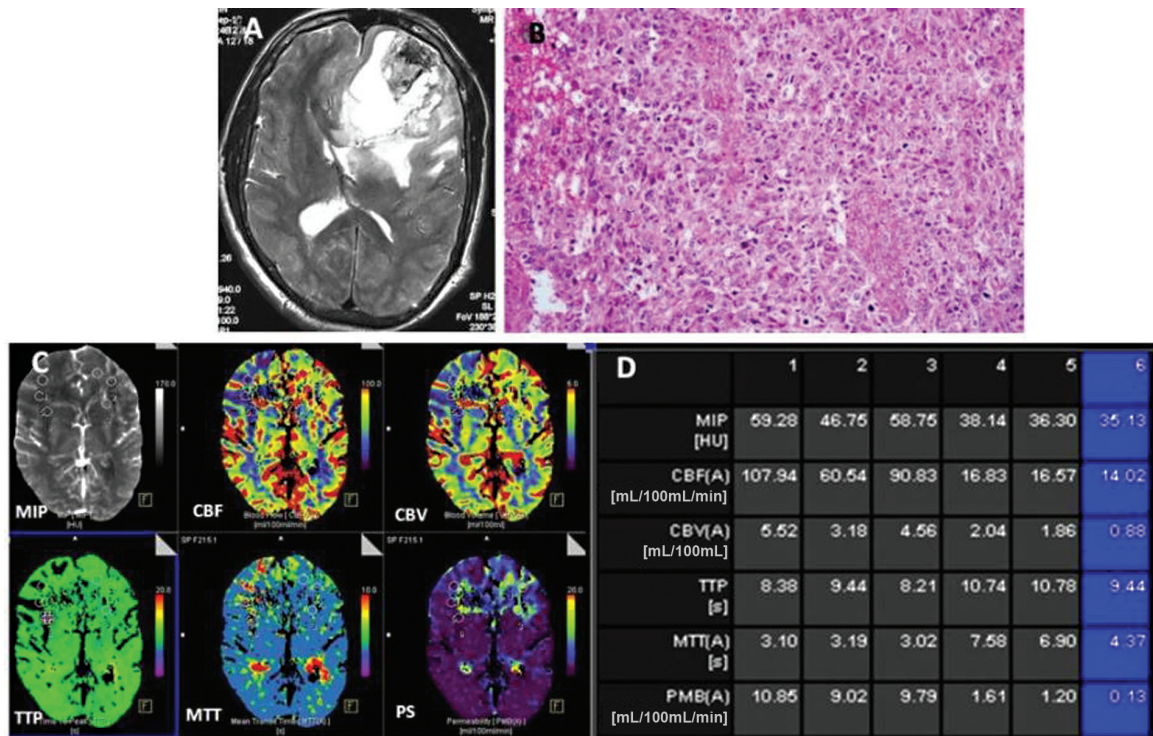
Subsequently, relative values of all the parameters were calculated by dividing the values from the tumor and control region, respectively. These relative perfusion values were compared to differentiate high- and low-grade glioma. Relative PS (rPS; with *p*-value  $< 0.0001$ ) and relative CBV (rCBV;



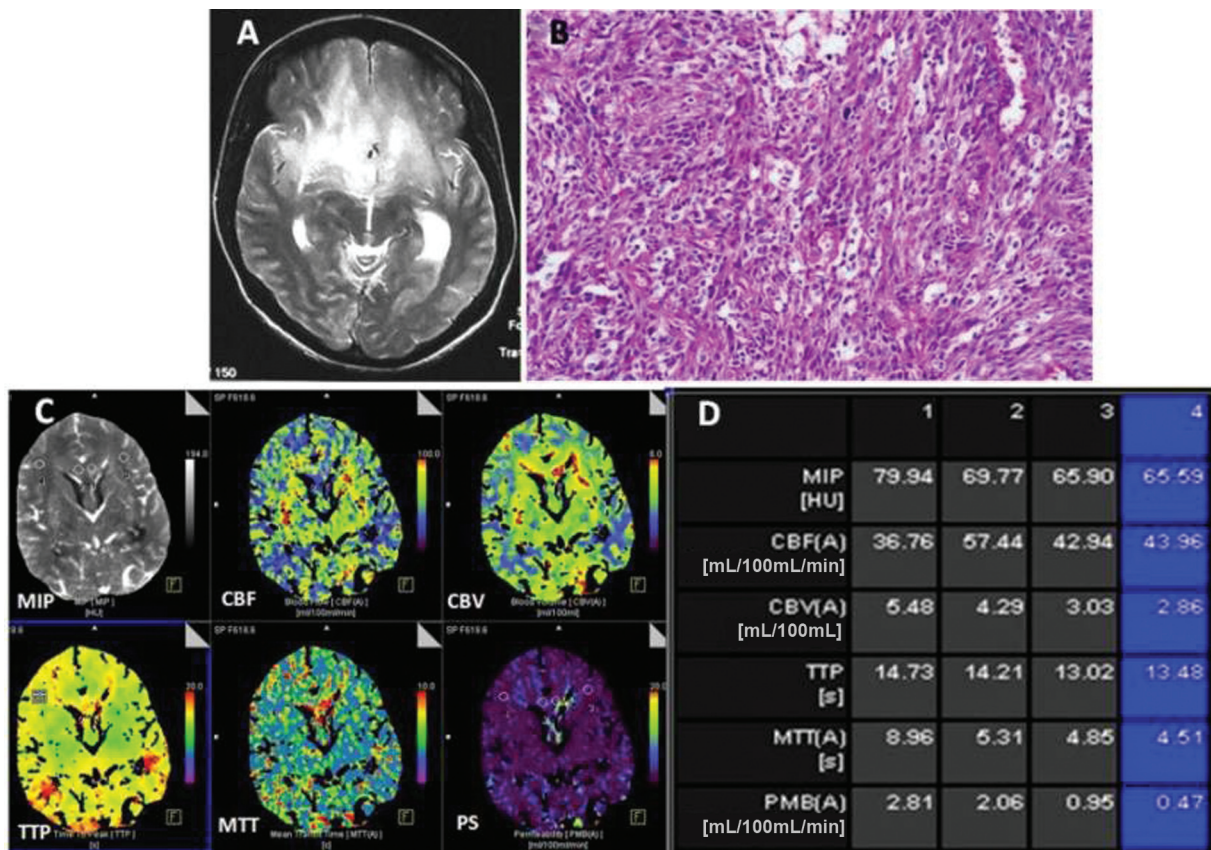
**Fig. 2** (A) A 46-year-old male presented with diffuse astrocytoma (World Health Organization grade II). T2-weighted imaging, (B) histopathology, (C) computed tomography perfusion (CTP) maps, (D) and CTP parameters. CBF, cerebral blood flow; CBV, cerebral blood volume; MIP, maximum intensity projection; MTT, mean transit time; PMB, permeability; TTP, time to peak.



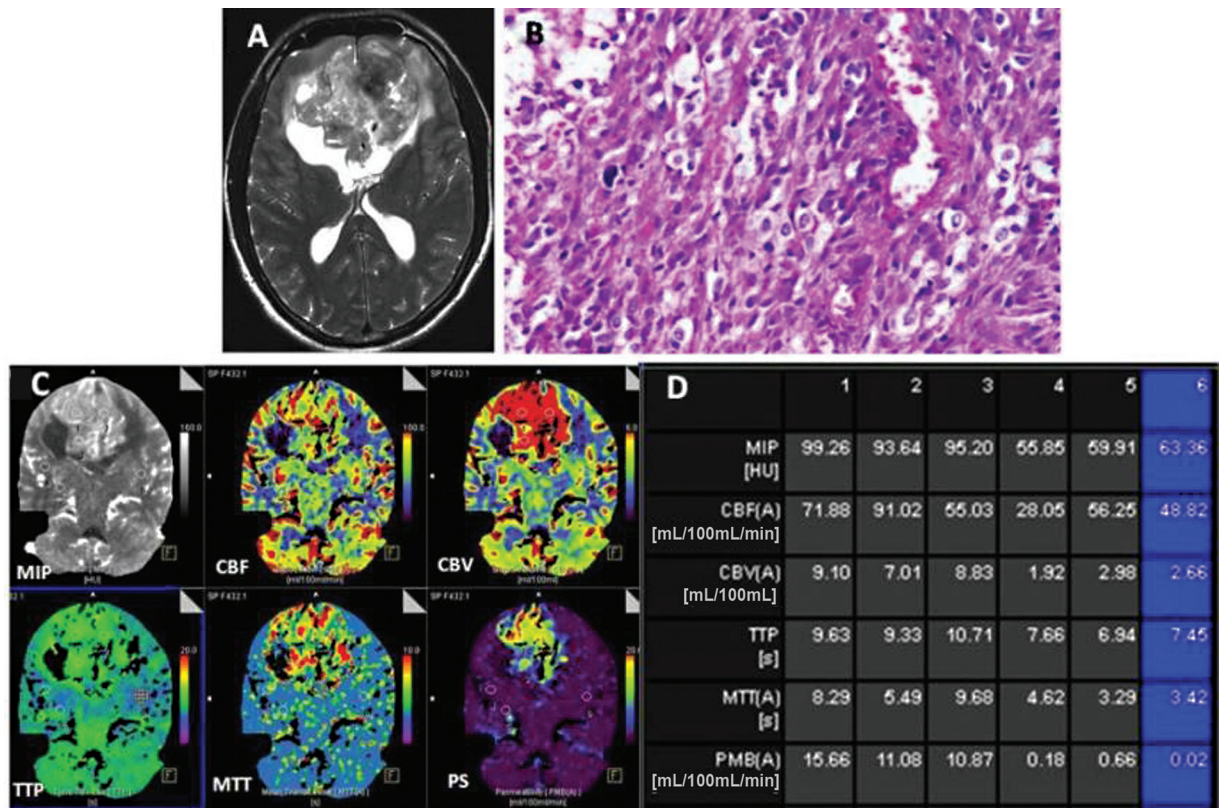
**Fig. 3** (A) A 58-year-old female presented with oligodendroglioma (World Health Organization grade II). T2-weighted imaging, (B) histopathology, (C) computed tomography perfusion (CTP) maps, (D) and CTP parameters. CBF, cerebral blood flow; CBV, cerebral blood volume; MIP, maximum intensity projection; MTT, mean transit time; PMB, permeability; TTP, time to peak.



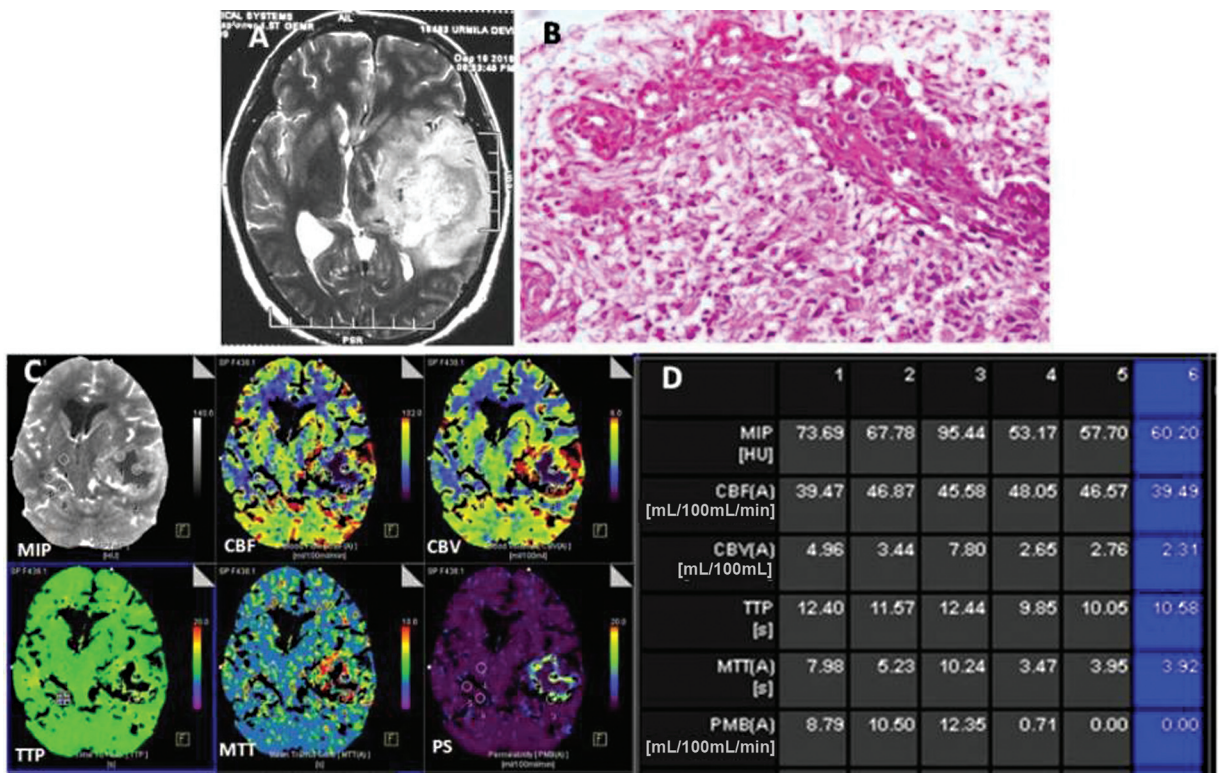
**Fig. 4** (A) A 42-year-old male presented with anaplastic oligodendroglioma (World Health Organization grade III). T2-weighted imaging, (B) histopathology, (C) computed tomography perfusion (CTP) maps, (D) and CTP parameters. CBF, cerebral blood flow; CBV, cerebral blood volume; MIP, maximum intensity projection; MTT, mean transit time; PMB, permeability; TTP, time to peak.



**Fig. 5** (A) A 21-year-old male presented with nonenhancing anaplastic astrocytoma (World Health Organization grade III). T2-weighted imaging, (B) histopathology, (C) computed tomography perfusion (CTP) maps, (D) and CTP parameters. CBF, cerebral blood flow; CBV, cerebral blood volume; MIP, maximum intensity projection; MTT, mean transit time; PMB, permeability; TTP, time to peak.



**Fig. 6** (A) A 60-year-old male presented with enhancing anaplastic astrocytoma (World Health Organization grade III). T2-weighted imaging, (B) histopathology, (C) computed tomography perfusion (CTP) maps, (D) and CTP parameters. CBF, cerebral blood flow; CBV, cerebral blood volume; MIP, maximum intensity projection; MTT, mean transit time; PMB, permeability; TTP, time to peak.



**Fig. 7** (A) A 45-year-old male presented with glioblastoma (World Health Organization grade IV). T2-weighted imaging, (B) histopathology, (C) computed tomography perfusion (CTP) maps, (D) and CTP parameters. CBF, cerebral blood flow; CBV, cerebral blood volume; MIP, maximum intensity projection; MTT, mean transit time; PMB, permeability; TTP, time to peak.

**Table 1** Comparison of relative value of perfusion parameters between high- and low-grade glioma

Normalized value of perfusion parameters	High (n = 19)	Low (n = 14)	p-Value	Test performed
<b>Relative PS</b>				
Mean ± SD	40.59 ± 27.53	4.58 ± 2.18	<0.0001	Mann–Whitney U test;7
Median (IQR)	35.16(18.405–56.797)	4.79(2.807–5.399)		
Range	4.68–94.81	1.6–9.01		
<b>Relative CBV</b>				
Mean ± SD	2.56 ± 1.06	1.57 ± 0.77	0.006	t-test; 2.94
Median (IQR)	2.45(1.991–3.165)	1.51(1.092–1.958)		
Range	1.08–5.06	0.48–3.45		
<b>Relative PS+ CBV</b>				
Mean ± SD	43.15 ± 27.53	6.15 ± 2.29	<0.0001	Mann–Whitney U test;4
Median (IQR)	39.09 (21.052–59.938)	5.7 (4.663–7.078)		
Range	6.78–96.69	3.25–11.46		
<b>Relative CBF</b>				
Mean ± SD	1.75 ± 1.08	1.47 ± 1.31	0.202	Mann–Whitney U test;98
Median (IQR)	1.53(1.058–2.133)	1.14(0.941–1.6)		
Range	0.61–5.47	0.32–5.78		
<b>Relative MTT</b>				
Mean ± SD	1.52 ± 0.52	1.24 ± 0.38	0.1	t-test; 1.692
Median (IQR)	1.53(1.176–1.849)	1.23(0.996–1.496)		
Range	0.49–2.65	0.54–1.88		
<b>Relative TTP</b>				
Mean ± SD	1.1 ± 0.13	1.07 ± 0.15	0.519	t-test; 0.652
Median (IQR)	1.09 (1.018–1.192)	1.05 (0.975–1.116)		
Range	0.84–1.36	0.84–1.42		

Abbreviations: CBF, cerebral blood flow; CBV, cerebral blood volume; IQR, interquartile range; MTT, mean transit time; TTP, time to peak; PS, permeability surface area; SD, standard deviation.

with *p*-value 0.006) were found to be significant in differentiating between high- and low-grade glioma (► **Table 1**).

After drawing the ROC curve for rPS and tumor grade, a sensitivity of 97.74% and specificity of 100% was calculated with a cut-off value of 9.0065. Positive predictive value was 100%, negative predictive value was 93.3% and diagnostic accuracy was 93.94% for differentiating high- and low-grade glioma for rPS. rCBV with a cut-off value of 2.0392 had 73.68% sensitivity, 78.57% specificity, 82.4% positive predictive value, 68.7% negative predictive value, and 75.76% diagnostic accuracy. The diagnostic accuracy of rCBV was lower than that of rPS (► **Table 2**).

Conjoint factor PS + CBV was also compared between high- and low-grade glioma. At a cut-off of 11.4573, rPS + CBV had 94.74% sensitivity, 100% specificity, 100% positive predictive value, 93.3% negative predictive value, and diagnostic accuracy of 96.67% (► **Table 2**).

On comparing area under the ROC curve for the perfusion parameters, it was found that PS was significantly better (*p*-value < 0.05) in predicting the tumor grade from CBV and all other perfusion parameters (► **Table 3**, ► **Fig. 8**).

Inter-rater kappa agreement was calculated for all the parameters and PS (*k*-value: 0.876) had a very good agreement with the tumor grade. Overall concordance rate was 93.94% and overall discordance rate was 6.06% between HPE grade and rPS. CBV (*k*-value 0.513) had a moderate agreement, while CBF, MTT, and TTP had a fair agreement. This again supported PS as the most useful parameter (► **Table 4**).

## Discussion

### CT Perfusion Values between Glioma versus Normal Brain Parenchyma

In our study, all five perfusion parameters, that is, PS, CBV, CBF, MTT, and TTP, had significantly higher values in the tumor region (in both high- and low-grade gliomas), when compared to the normal background brain parenchyma. This finding is supported by the fact that gliomas rely on neo-vascularization for their blood supply, hence exhibiting higher perfusion values. Even early low-grade gliomas are well vascularized by vascular co-option. As the grade progresses, other mechanisms of neoangiogenesis set into

**Table 2** ROC curve of perfusion parameters for predicting high-grade glioma

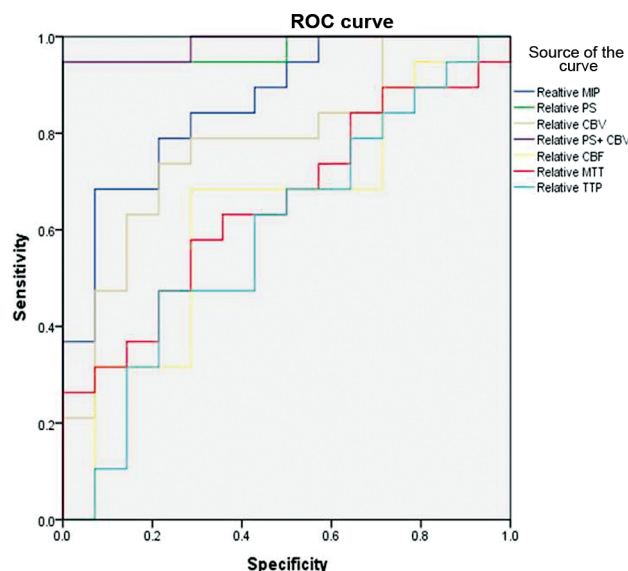
High HPE grade	Relative PS	Relative CBV	Relative PS+ CBV	Relative CBF	Relative MTT	Relative TTP
Area under the ROC curve (AUC)	0.974	0.778	0.985	0.632	0.654	0.594
Standard error	0.0273	0.0836	0.0164	0.103	0.0969	0.104
95% CI	0.849–1.000	0.600–0.904	0.867–1.000	0.446–0.792	0.469–0.810	0.410–0.761
<i>p</i> -Value	<0.0001	0.0009	<0.0001	0.2026	0.1116	0.3677
Cut-off	>9.0065	>2.0392	>11.4573	>1.1912	>1.3239	>1.118
Sensitivity (95% CI)	94.74% (74–99.9%)	73.68% (49–91%)	94.74% (74–99.9%)	68.42% (43–87%)	57.89% (34–80%)	47.37% (24–71%)
Specificity (95% CI)	100% (77–100%)	78.57% (49–95%)	100% (77–100%)	71.43% (42–92%)	71.43% (42–92%)	78.57% (49–95%)
PPV (95% CI)	100% (82–100%)	82.4% (57–96%)	100% (82–100%)	76.5% (50–93%)	73.3% (45–92%)	75% (43–95%)
NPV (95% CI)	93.3% (68–99.8%)	68.7% (41–89%)	93.3% (68–99.8%)	62.5% (35–85%)	55.6% (31–79%)	52.4% (30–74%)
Diagnostic accuracy	93.94%	75.76%	96.97%	66.67%	63.64%	60.61%

Abbreviations: AUC, area under the curve; CBV, cerebral blood volume; CBF, cerebral blood flow; CI, confidence interval; HPE, histopathological examination; MTT, mean transit time; NPV, negative predictive value; PPV, positive predictive value; PS, permeability surface area; ROC, receiver operating characteristic; TTP, time to peak.

**Table 3** Comparison of area under the curve of perfusion parameters with relative PS to predict high-grade glioma

Relative PS	Difference between areas	95% Confidence interval	<i>p</i> -Value
Relative CBF	0.342	0.123–0.561	0.0022
Relative CBV	0.195	0.0223–0.369	0.0269
Relative MTT	0.32	0.137–0.502	0.0006
Relative TTP	0.38	0.173–0.586	0.0003

Abbreviations: CBV, cerebral blood volume; CBF, cerebral blood flow; MTT, mean transit time; PS, permeability surface area; TTP, time to peak.



**Fig. 8** Comparison of area under curve of permeability surface area with other perfusion parameters to predict high-grade from low-grade gliomas. CBF, cerebral blood flow; CBV, cerebral blood volume; IQR, interquartile range; MTT, mean transit time; TTP, time to peak; PS, permeability surface area; ROC, receiver operating characteristic.

action, that is, angiogenesis, vasculogenesis, vascular mimicry, and glioblastoma–endothelial cell transdifferentiation, and lead to a substantial increase in the perfusion values.<sup>12</sup>

Our observation was fairly consistent with the findings of Xyda et al<sup>13</sup> who also found PS and CBV significantly higher in the tumor region (in both high- and low-grade gliomas) as compared to the normal brain parenchyma. However, in contrast to our study, Ding et al,<sup>14</sup> Maarouf et al,<sup>15</sup> and Kumar et al<sup>16</sup> reported high perfusion values only in high-grade gliomas and not in low-grade gliomas, when compared to the background normal brain parenchyma.

### Comparison of Perfusion Parameters in High- and Low-Grade Gliomas

In our study, both rPS and rCBV were found statistically significant in differentiating high- and low-grade glioma. CBF, TTP, and MTT were not found statistically significant. However, rPS had higher sensitivity (97.74%), specificity (100%), and diagnostic accuracy (93.94%) than rCBV. On comparing area under the ROC curve for the perfusion parameters, it was found that PS was significantly better (*p*-value < 0.05) in predicting the tumor grade from CBV and all other perfusion parameters.



**Table 4** Inter-rater kappa agreement of relative PS and HPE grade

Relative PS	HPE grade		Total	p-Value	Kappa
	Low (n = 14)	High (n = 19)			
≤9.0065	13 (39.39%)	1 (3.03%)	14 (42.42%)	<0.0001	0.876
>9.0065	1 (3.03%)	18 (54.55%)	19 (57.58%)		
Total	14 (42.42%)	19 (57.58%)	33 (100.00%)		

Abbreviations: HPE, histopathological examination; PS, permeability surface area.

The earlier studies<sup>9,13–17</sup> found PS, CBV, and CBF to be statistically significant in differentiating high- and low-grade glioma. However, we found only PS and CBV significant and not CBF.

Moreover, in the literature there is no consensus regarding the most sensitive and specific perfusion parameter in differentiating high- and low-grade glioma. Ding et al<sup>14</sup> found PS to be the most sensitive (100%) and specific (83.3%) parameter, as observed in our study. Maarouf et al<sup>15</sup> and Xyda et al<sup>13</sup> found CBV to be the most sensitive and specific parameter, while Kumar et al<sup>16</sup> found CBF to be the most sensitive and specific parameter.

In our study, the cut-off value of rPS for differentiating high- and low-grade glioma was 9.0006, which was higher than the cut-offs calculated in other studies.<sup>12–15</sup> The higher cut-off values observed by us could be attributed to higher contrast concentration and faster injection rate.<sup>18</sup> The contrast concentration and injection rate used in our study was 400 mg/mL at 5.5 mL/s, higher than aforementioned studies.<sup>12–15</sup> However, Xyda et al<sup>13</sup> demonstrated a lower cut-off value of 2.21 for PS at similar contrast concentration and injection rate. More studies are required to delineate the effect of contrast concentration on CT perfusion results in differentiating high- and low-grade glioma.

The sensitivity and specificity for PS to differentiate high- and low-grade glioma obtained in our study were higher than the studies done by Maarouf et al,<sup>15</sup> Kumar et al,<sup>16</sup> and Saleh et al.<sup>17</sup> Similar sensitivity and specificity profile was observed by Xyda et al<sup>13</sup> as obtained in our study, which probably could be attributed to the higher contrast concentration.

We calculated inter-rater kappa agreement for all the perfusion parameters. PS with *k*-value 0.876 had a very good agreement with the tumor grade on HPE. CBV with *k*-value 0.513 had a moderate agreement, while CBF, MTT, and TTP had a fair agreement. This again supported PS as the most useful parameter. Further studies are needed to corroborate the strength of agreement between CTP and HPE grading as seen in our case.

We also studied the conjoint factor PS + CBV that had a similar diagnostic profile as PS, with diagnostic accuracy (96.67%) marginally higher than PS (93.94%). PS and CBV are complimentary factors for tumor vascularity, with PS being a surrogate marker for microvascular cellular proliferation and CBV being a surrogate marker for microvascular density.<sup>19</sup> To best of our knowledge, only one study done by Shankar et al<sup>11</sup>

has evaluated the conjoint factor (PS + CBV) to differentiate grade III and grade IV gliomas, and it was found to be statistically significant. However, no study using conjoint factor to differentiate high- and low-grade glioma has been reported till date.

## Conclusion

Although both rPS and rCBV were helpful in differentiating high- and low-grade glioma, rPS exhibited best sensitivity and specificity profile and was found significantly better than the other perfusion parameters. rPS had a very good agreement with the HPE grade. The conjoint factor (PS + CBV) did not yield any significant diagnostic advantage over PS. The results of our study suggest that rPS alone can be helpful in grading brain gliomas, and can add crucial value in the management and prognostication of these tumors.

## Ethical Statement

The study was conducted after obtaining ethical clearance from the institutional ethical committee. Informed consent was obtained from all patients included in the study.

## Funding

None.

## Conflict of Interest

None declared.

## References

- Dasgupta A, Gupta T, Jalali R. Indian data on central nervous tumors: a summary of published work. *South Asian J Cancer* 2016;5(03):147–153
- Mesfin FB, Al-Dhahir MA. *Cancer, Brain Gliomas*. In: StatPearls. Treasure Island (FL): StatPearls Publishing; 2019
- Altwaigri AK, Raja S, Manzoor M, et al. Management and treatment recommendations for World Health Organization Grade III and IV gliomas. *Int J Health Sci (Qassim)* 2017;11(03):54–62
- Law M, Yang S, Wang H, et al. Glioma grading: sensitivity, specificity, and predictive values of perfusion MR imaging and proton MR spectroscopic imaging compared with conventional MR imaging. *AJNR Am J Neuroradiol* 2003;24(10):1989–1998
- Johnson DR, Guerin JB, Giannini C, Morris JM, Eckel LJ, Kaufmann TJ. 2016 updates to the WHO Brain Tumor Classification System: what the radiologist needs to know. *Radiographics* 2017;37(07):2164–2180
- Law M, Young RJ, Babb JS, et al. Gliomas: predicting time to progression or survival with cerebral blood volume

- measurements at dynamic susceptibility-weighted contrast-enhanced perfusion MR imaging. *Radiology* 2008;247(02):490–498
- 7 Jain RK, Munn LL, Fukumura D. Dissecting tumour pathophysiology using intravital microscopy. *Nat Rev Cancer* 2002;2(04):266–276
  - 8 Folkman J. The role of angiogenesis in tumor growth. *Semin Cancer Biol* 1992;3(02):65–71
  - 9 Jain R, Ellika SK, Scarpace L, et al. Quantitative estimation of permeability surface-area product in astroglial brain tumors using perfusion CT and correlation with histopathologic grade. *AJNR Am J Neuroradiol* 2008;29(04):694–700
  - 10 Ellika SK, Jain R, Patel SC, et al. Role of perfusion CT in glioma grading and comparison with conventional MR imaging features. *AJNR Am J Neuroradiol* 2007;28(10):1981–1987
  - 11 Shankar JJ, Woulfe J, Silva VD, Nguyen TB. Evaluation of perfusion CT in grading and prognostication of high-grade gliomas at diagnosis: a pilot study. *AJR Am J Roentgenol* 2013;200(05):W504–9
  - 12 Hardee ME, Zagzag D. Mechanisms of glioma-associated neovascularization. *Am J Pathol* 2012;181(04):1126–1141
  - 13 Xyda A, Haberland U, Klotz E, et al. Brain volume perfusion CT performed with 128-detector row CT system in patients with cerebral gliomas: a feasibility study. *Eur Radiol* 2011;21(09):1811–1819
  - 14 Ding B, Ling HW, Chen KM, Jiang H, Zhu YB. Comparison of cerebral blood volume and permeability in preoperative grading of intracranial glioma using CT perfusion imaging. *Neuroradiology* 2006;48(10):773–781
  - 15 Maarouf R, Sakr H. A potential role of CT perfusion parameters in grading of brain gliomas. *Egypt J Radiol Nucl Med* 2015;46:1119–1128
  - 16 Kumar S, Ramesh D, Kailasanathan N. The role of CT perfusion in grading of brain gliomas in correlation with histopathology. *Int J Contemp Med Res* 2017;4(02):540–544
  - 17 Saleh TMR, Zakaria YM, Elnekidey AA, Farhoud AH, Ismail AS. Role of CT perfusion in differentiation between high and low grade glioma. *Journal of Medical Science and Clinical Research* 2015;3(11):8392–8398
  - 18 Silvennoinen HM, Hamberg LM, Valanne L, Hunter GJ. Increasing contrast agent concentration improves enhancement in first-pass CT perfusion. *AJNR Am J Neuroradiol* 2007;28(07):1299–1303
  - 19 Jain R, Gutierrez J, Narang J, et al. In vivo correlation of tumor blood volume and permeability with histologic and molecular angiogenic markers in gliomas. *AJNR Am J Neuroradiol* 2011;32(02):388–394