

# Spontaneous Bag Mask Ventilation for Establishing Cardiopulmonary Bypass Via Mid-Sternotomy in Patients with Severe Tracheal Stenosis: A Series of Three Patients

## Abstract

In patients with critical tracheal stenosis, particularly involving the lower part of trachea, a highly experienced team of anesthesiologists to tackle the difficulties of securing and maintaining the ventilation, cardiac surgeon who can swiftly establish cardiopulmonary bypass, an experienced surgeon for tracheal reconstruction are a prerequisite for managing these highly complex cases. The present paper describes three patients suffering from severe tracheal narrowing wherein spontaneous bag-mask ventilation was used for establishing cardiopulmonary bypass via mid-sternotomy as a rare life-saving procedure for urgent tracheal reconstructive surgery. A highly experienced team of anesthesiologists to tackle the difficulties of securing and maintaining the ventilation, cardiac surgeon who can swiftly establish CPB, and an experienced surgeon for tracheal reconstruction are a prerequisite for managing these highly complex cases. The present paper describes three patients suffering from severe tracheal narrowing wherein spontaneous bag-mask ventilation was used for establishing CPB via mid-sternotomy as a rare life-saving procedure for urgent tracheal reconstructive surgery.

**Keywords:** *Cardiopulmonary bypass, mid-sternotomy, spontaneous bag-mask ventilation, tracheal reconstruction*

## Introduction

Tracheal reconstruction for tracheal stenosis (commonly occurring as a complication of endotracheal intubation or tracheostomy) and obstruction (extrinsic obstruction from nontracheal tumours or primary tumours of the trachea)<sup>[1]</sup> pose a challenge to both the anesthesiologist and the surgeon. Administration of general anesthesia and the use of muscle relaxants is fraught with the risk of further collapse of tracheal lumen leading to life threatening hypoxia. Various methods described for managing such patients include spontaneous ventilation under general anaesthesia, local or high thoracic epidural anesthesia, high frequency jet ventilation using a rigid bronchoscope or through a laryngeal mask airway.<sup>[2]</sup> In patients with critical tracheal stenosis, particularly with a large mass involving the lower part of trachea, extracorporeal membrane oxygenation using cardiopulmonary bypass (CPB) or extracorporeal lung assist devices have also been described.<sup>[2-8]</sup>

This is an open access journal, and articles are distributed under the terms of the Creative Commons Attribution-NonCommercial-ShareAlike 4.0 License, which allows others to remix, tweak, and build upon the work non-commercially, as long as appropriate credit is given and the new creations are licensed under the identical terms.

For reprints contact: reprints@medknow.com

## Case Report

### Case 1

A 32-year-old female weighing 28 kg presented in the ear, nose, and throat (ENT) department with a history of progressively increasing difficulty in breathing which aggravated on lying down, and recurrent cough for 2 years. There was no difficulty in swallowing, no history of chest pain, palpitation, hemoptysis, or hoarseness. Mouth opening was adequate and an indirect laryngoscopic examination revealed normal vocal cords. Computed Tomography (CT) scan revealed a well-defined, lobulated, heterogeneously enhancing mass seen projecting intraluminal and obstructing almost 90% of the tracheal lumen. A diagnosis of tracheal hemangioma arising 1 cm above the carina protruding into the tracheal lumen was made [Figure 1a and b]. Anticipating the need for CPB during surgery, the patient was referred to the cardiothoracic and vascular surgery (CTVS) department and was scheduled to undergo tumor resection and tracheal reconstruction.

**How to cite this article:** Virmani S, Datt V, Tempe DK, Minhas HS, Meher R, Goswami AD, *et al.* Spontaneous bag mask ventilation for establishing cardiopulmonary bypass via mid-sternotomy in patients with severe tracheal stenosis: A series of three patients. *Ann Card Anaesth* 2020;23:241-5.

**Sanjula Virmani,  
Vishnu Datt,  
Deepak K Tempe,  
Harpreet S Minhas<sup>1</sup>,  
Ravi Meher<sup>2</sup>,  
Aastha D Goswami,  
Shalini Sharma,  
Indira Malik**

*Departments of Anaesthesiology and Intensive Care and <sup>1</sup>Cardiothoracic Surgery, GIPMER, <sup>2</sup>Department of ENT and Head and Neck Surgery MAMC, New Delhi, India*

**Submitted:** 27-Dec-2018

**Revised:** 05-Mar-2019

**Accepted:** 17-Mar-2019

**Published:** 07-Apr-2020

### Address for correspondence:

*Dr. Sanjula Virmani,  
Department of Anaesthesiology and Intensive Care, G B Pant Institute of Postgraduate Medical Education and Research (GIPMER),  
New Delhi - 110 002, India.  
E-mail: drsanjulavirmani@yahoo.co.in*

### Access this article online

**Website:** www.annals.in

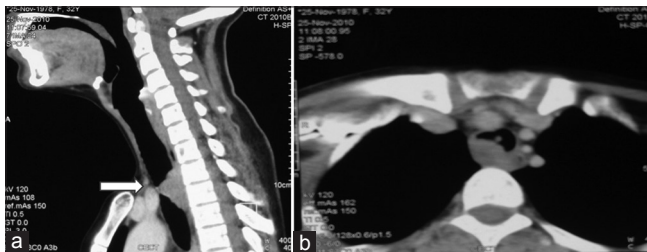
**DOI:** 10.4103/aca.ACA\_246\_18

### Quick Response Code:



Physical examination revealed difficulty in breathing with a respiratory rate of 20--25/min, and evident use of accessory muscles of respiration and nasal flaring. She was most comfortable in reclining position of 50--60°. When made supine, she became agitated and unable to breathe. Auscultation of the chest revealed bilateral inspiratory and expiratory wheeze. There was no other systemic abnormality. All hematological and laboratory tests were within normal limits. Arterial blood gas analysis (ABG) on room air showed saturation of 92% and respiratory alkalosis, while rest of the parameters were within acceptable limits. Due to severe respiratory distress in the lying down position, and the risk of aggravation of tracheal narrowing on administration of muscle relaxant and general anesthesia, establishing CPB via femoro--femoral route under local anesthesia was considered. However, it was rejected by the cardiothoracic surgeon due to technical reasons (femoral cannulation site was considered inaccessible because the patient was unable to lie supine even for a few seconds). Hence, it was decided to anesthetize the patient in a reclining position (that was most comfortable for the patient) using inhalational technique followed by sternotomy and quick establishment of CPB.

In the operating room, ECG, pulse oximetry, capnometry, and BIS monitoring was established while the patient was positioned reclining at an angle of about 50° wherein she was most comfortable. The operating table was positioned head up (reverse Trendelenburg) and then with pillows and head ring the patient was positioned at about 50° [Figure 2]. A wide bore intravenous line, arterial line (left radial), and central venous catheter were placed under local anesthesia in the reclining position. Patient was cleaned and partially draped before induction of anesthesia. Mapleson C circuit with pressure relief valve and disposable anesthesia face mask with inflatable cushion [Figure 2] were used to deliver the anesthetic gases, oxygen, nitrous oxide [fractional inspired oxygen concentration (FiO<sub>2</sub>) 0.5], and sevoflurane (gradually increased from 2 to 6%). Ketamine (0.5 mg/kg), fentanyl (1 µg/kg), and midazolam (1 mg) were administered once it was ensured that airway can be maintained adequately while breathing via mask. Intermittently ventilation was assisted to maintain end-tidal carbon dioxide (EtCO<sub>2</sub>) in the range of 30--40



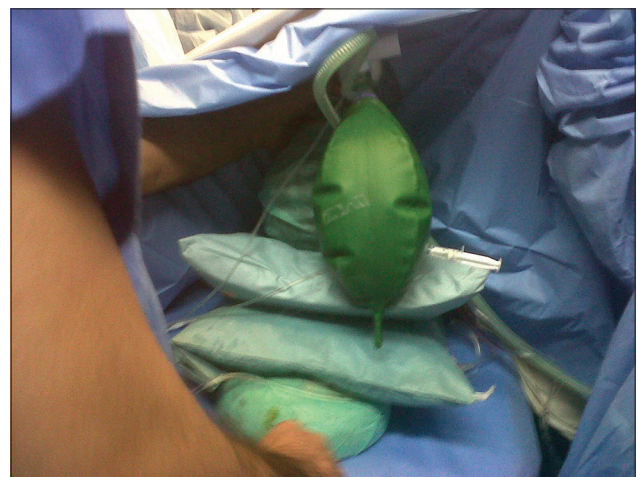**Figure 1:** Axial and coronal contrast CT (a and b) of case number 1 showing enhancing mass lesion protruding into the tracheal lumen arising from mucosa 1 cm above the carina (Arrow)

mm Hg, and arterial oxygen saturation (SaO<sub>2</sub>) >95%.

Once the patient was anesthetized, the reclining angle was decreased to about 30° and the surgeon proceeded with the sternotomy. Anticoagulation was accomplished by administering heparin 3 mg/kg and after cannulating the aorta and the right atrium (single 23 G cannula), CPB was established. Once the CPB was established, the patient was made supine, pancuronium bromide was administered and trachea was intubated with a 7 mm cuffed endotracheal tube. The time taken from anesthetic induction to establishment of CPB was 10 min. Flexible fiberoptic bronchoscopy was performed through the endotracheal tube to ensure that the position of the endotracheal tube was well above the tumor [Figure 3]. Normothermic CPB was maintained with a flow rate of 2--2.5 L/min/m<sup>2</sup> and a perfusion pressure of 60--80 mm Hg. Anesthesia was maintained with fentanyl, midazolam, and pancuronium bromide. Hemangioma was excised and the tracheal end-to-end anastomosis was performed. Tracheostomy was performed before separation from the CPB. Anticoagulation was reversed with protamine after separation from the CPB. Hemodynamics were maintained in the post-CPB period and the patient was transferred to the intensive care unit (ICU) for elective ventilation. The patient was weaned off the ventilator after 2 days. The further course was uneventful.

## Case 2

A 42-year-old female presented to the ENT department with a short history of severe breathlessness and stridor for 7 days with no history of hemoptysis, chest pain, or change in voice. She gave a history of being operated for uterine fibroids 2 months ago following which she had developed disseminated intravascular coagulation and septicaemia, for which she remained intubated and ventilated for 20 days. Indirect laryngoscopy showed normal vocal cords. Fiberoptic bronchoscopic examination under local anesthesia (performed in a reclining position) preoperatively



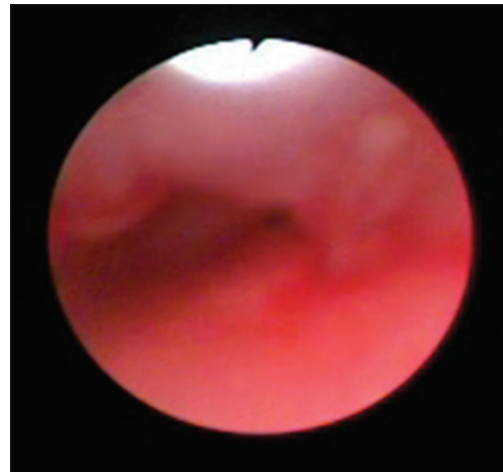
**Figure 2:** Real-time picture showing patient reclining at an angle of 50° (table tilted up, head supported on pillows and a head ring) while breathing spontaneously on Mapleson C Circuit and anesthesia face mask

revealed a tracheal stenosis and computerized tomographic scan (CT) confirmed it to be at the level of lower border of T3. The length of the narrowed segment was 8 mm with an anteroposterior diameter of 0.53 cm [Figure 4]. A diagnosis of tracheal stenosis following prolonged endotracheal intubation was made and anticipating the need for CPB during surgery, the patient was referred to the CTVS department for tracheal resection and end-to-end anastomosis.

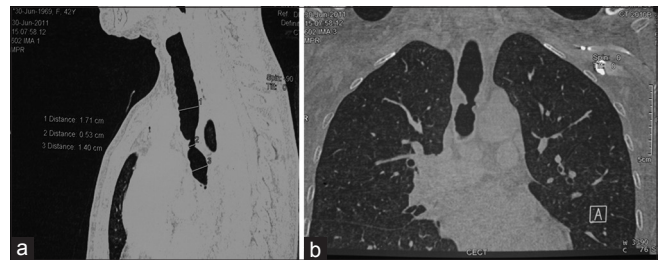
Physical examination revealed severe respiratory distress. The respiratory rate was 35–40/min, patient had stridor, and was unable to lie supine. She was somewhat comfortable at a reclining position of 60–70°. There was no swelling in the neck, she had an adequate mouth opening with a Mallampati grade I. All routine hematological and biochemical laboratory tests were within normal limits. Arterial blood gas analysis (ABG) was also acceptable with oxygen saturation of 90% and respiratory alkalosis when breathing room air. Institution of CPB via femoral route under local anesthesia was considered necessary, but was not executed due to technical difficulty posed by the patient not being able to lie supine. Hence, as in the first patient, it was planned to perform sternotomy in the reclining position using inhalational anesthetics. A thoracic epidural catheter was inserted before anesthetic induction in the sitting position at the level of T3–T4 (0.2% of ropivacaine with fentanyl was administered epidurally). The patient was managed similar to the first patient using inhalational anesthetics (oxygen, nitrous oxide, sevoflurane) supplemented with fentanyl (1 µg/kg), ketamine (0.5 mg/kg), and midazolam (1 mg). Intermittently, ventilation was assisted using bag-mask ensuring adequate ventilation parameters of EtCO<sub>2</sub> (from 35 to 40 mm Hg) and oxygen saturation (>92%). After the swift establishment of CPB (around 10 min) via mid-sternotomy, a cuffed endotracheal tube (7.5 mm) was negotiated up to the stenosed portion and secured. Fiberoptic bronchoscopy was performed through the endotracheal tube to visualize the position of the tube and the site of stenosis. Resection of the stenosed area with end-to-end anastomosis was performed under CPB and endotracheal tube was repositioned beyond the anastomosis before separation from the CPB. Total duration of surgery was 200 min with CPB time of 140 min. The patient was electively ventilated and weaned off after 72 h.

### Case 3

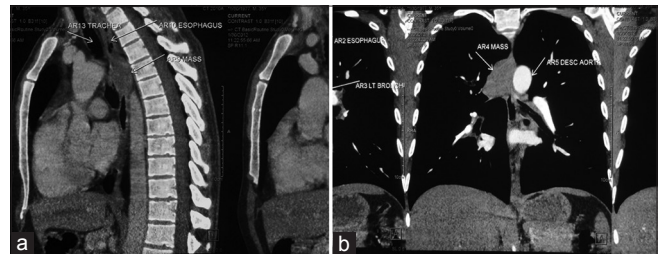
A 35-year-old male patient presented to the ENT department with a history of cough for 6 months, stridor and a progressive difficulty in breathing in lying down position. Fiberoptic bronchoscopy and CT scan confirmed a fleshy sessile growth intramurally in the distal 1/3<sup>rd</sup> of the trachea arising from the posterior tracheal wall and a solid homogenous enhancing mass lesions causing severe tracheal compression respectively [Figure 5]. Anticipating the need for CPB during surgery, the patient was referred to



**Figure 3:** Fiberoptic bronchoscopy performed after endotracheal intubation in case number 1 showing hemangioma obstructing the proximal tracheal lumen leading to a narrow opening



**Figure 4:** (a and b): Contrast enhanced computerized tomography of Neck and chest in case number 2 showing tracheal stenosis at the lower border of T3. The anteroposterior diameter of the tracheal lumen at the level of obstruction is 0.53 cm



**Figure 5:** Axial and coronal contrast tomographic images (a and b) of case number 3 showing a solid homogenous mass lesion arising from the posterior tracheal wall obstructing the lumen

the CTVS department. Physical examination revealed that the patient was in severe respiratory distress, (respiratory rate >30/min), nasal flaring, and inability to lie supine. He was however somewhat comfortable in a 50–60° reclining position, (wherein he maintained a saturation of 90–92% on air). There was no abnormality in the neck, mouth opening was adequate with Mallampatti grade of II. All routine hematological and laboratory tests were within normal limits. In the operating room, anesthetic technique was similar to the previous patients using inhalational anesthetics (oxygen, nitrous oxide, sevoflurane) and intravenous anaesthetic drugs fentanyl (1 µg/kg), ketamine (0.5 mg/kg), and midazolam (1 mg) with the

patient breathing spontaneously till the establishment of CPB. Debulking of the tumor was performed through a transverse incision on the trachea as the tumor was close to carina and invading the left bronchus. Trachea was intubated after debulking of the tumor. Tumor tissue was sent for frozen section and was diagnosed to be adenoid cystic carcinoma. Duration of CPB was 120 min and patient was weaned after 2 days of elective ventilation.

## Discussion

Establishing adequate gas exchange and allowing good surgical access can prove to be quite a challenge in patients with tracheal compression/obstruction, severe respiratory distress, presenting for tracheal reconstructive surgery. Preoperative assessment of the pulmonary function by way of assessing orthopnea, stridor, and exercise tolerance, airway assessment including, mouth opening, neck mobility, and ability to successfully mask ventilate is mandatory. The postural difficulty in breathing should also be investigated so that ideal position during anesthetic induction can be determined. Due to tracheomalacia, the airway of the patient is prone to collapse following administration of muscle relaxant. Indeed, there are reports in the literature that describe airway compression after successful endotracheal intubation, which could be relieved only after reversal of muscle blockade.<sup>[9]</sup> This is because during spontaneous respiration the pleural pressure is markedly negative compared with airway pressure. This transpleural pressure gradient tends to increase the airway diameter and minimizes the effect of intrathoracic airway obstruction. Once the patient is anesthetized, the distending pressure gradient is lost and the effect of extrinsic airway compression becomes greater and the relaxation of bronchial smooth muscles due to general anesthetics or muscle relaxants induces greater compressibility, thus increasing the difficulty to ventilate. Positive pressure ventilation may further worsen airway obstruction.<sup>[9]</sup> The airway management becomes even more challenging when the obstruction is in the distal trachea as in the present patients. The patients who have postural breathing difficulty and those with a flow volume loop showing severe expiratory limb plateauing in supine position are at a high risk of developing tracheal compression following induction of anesthesia and administration of muscle relaxant.<sup>[2]</sup> Anesthetic induction with inhalational agents maintaining spontaneous respiration and avoiding administration of muscle relaxants has been practised by some.<sup>[10]</sup> Keeping the CPB as standby or instituting CPB via femoral artery--femoral vein route under local anesthesia has been practised by others to circumvent such a problem.<sup>[11]</sup>

The present three patients had airway obstruction in distal trachea and all were having breathing difficulty in the supine position. Hence, institution of CPB under local anesthesia via femoral route was strongly considered before

anesthetic induction, but was technically not possible as the femoral area was inaccessible to the surgeon as the patients were unable to lie supine. A recent report has described similar difficulty in not being able to institute CPB via femoral route due to obesity and patient not being able to lie supine.<sup>[12]</sup> Instituting CPB via jugular vein and axillary artery or veno--venous extracorporeal membrane oxygenation via jugular vein was considered but the required cannulae and facilities were not available at that time.

Awake fiberoptic intubation is another way of managing the airway, however, it was not considered feasible in the present patients as the narrowing was in the lower trachea and negotiating the endotracheal tube beyond the obstruction in the presence of intratracheal mass (patients 1 and 3) was considered unsafe due to the risk of bleeding. In patient number 2, severe narrowing of the trachea could not have permitted introduction of adequate size endotracheal tube (at least 6 mm) beyond the narrowed segment. Therefore, awake fiberoptic intubation is generally performed in patients with extrinsic tracheal compression and/or tracheomalacia.

High frequency jet ventilation was also not considered feasible in the present patients due to difficulty in placing the catheter beyond the obstruction. In addition, jet ventilation carries the risk of barotrauma and hypercarbia.

The ideal method of managing such patients is to operate them early before tracheal compression progresses to a level that leads to breathing difficulty in supine position. This was perhaps applicable in patients number 1 and 3 who had a long history of symptoms, whereas the patient number 2 had a short history of only about 2 months. In India, perhaps due to social and economic reasons as well as ignorance, delayed and very delayed presentation is not uncommon.

The authors believe that anesthetic induction in reclining position using inhalational agents in spontaneous ventilation with intermittent assisted breaths seems to be an option in patients with lower tracheal narrowing/compression. Surgical rescue by establishing CPB via sternotomy or femoral route is described in the event of total airway collapse in patients with mediastinal masses.<sup>[13]</sup> The technique described in the present patients can be considered as elective surgical rescue. However, a close cooperation and extensive communication between the anesthesiologist and cardiac surgeon is necessary. In addition, an expert surgeon who can perform a swift sternotomy and cannulation to institute the CPB in as short time as possible seems to be mandatory.

## Declaration of patient consent

The authors certify that they have obtained all appropriate patient consent forms. In the form the patient(s) has/have given his/her/their consent for his/her/their images and

other clinical information to be reported in the journal. The patients understand that their names and initials will not be published and due efforts will be made to conceal their identity, but anonymity cannot be guaranteed.

### Financial support and sponsorship

Nil.

### Conflicts of interest

There are no conflicts of interest.

### References

1. Grillo HC, Donahue DM, Mathisen DJ, Wain JC, Wright CD. Postintubation tracheal stenosis. Treatment and results. *J Thorac Cardiovasc Surg* 1995;109:486-92.
2. Datt V, Tempe DK. Airway management in patients with mediastinal masses. *Indian J Anaesth* 2005;49:344-52.
3. Bouaggad A, Bennani F, Harrar R, Bouderkha MA, Harti A. Anesthesia for a patient with tracheal tumor using laryngeal mask airway. *Anesth Analg* 2006;103:258-9.
4. Chakravarthy M, Kamble P, Satish KS, Mehta RM, Krishnamoorthy J. Spontaneous respiration for endoscopic cauterization and stenting of a tracheal tumor under thoracic epidural anesthesia. *J Cardiothorac Vasc Anesth* 2008;22:872-4.
5. Tsuji M, Hamada H, Kawamoto M, Yuge O. Anesthetic management of laser surgery with bronchial stenting for a transtracheal tumor. *Masui* 2006;55:103-5.
6. Williams A, Patel A, Ferguson C. High frequency jet ventilation through laryngeal mask airway in a critically obstructed airway. *Anaesthesia* 2008;63:1369-71.
7. Smith IJ, Sidebotham DA, McGeorge AD, Dorman EB, Wilsher ML, Kolbe J. Use of extracorporeal membrane oxygenation during resection of tracheal papillomatosis. *Anesthesiology* 2009;110:427-9.
8. Nagamine Y, Harada T, Asada M, Sumitomo M. Anesthetic management of tracheobronchial stent insertion and extracorporeal lung assist (ECLA). *Masui* 2008;57:708-12.
9. Chen SH, Hsu JC, Lui PW, Chen CH, Yang CY. Airway obstruction by metastatic mediastinal tumor during anesthesia. *Chang Gung Med J* 2005;28:258-63.
10. Sibert KS, Biondi JW, Hirsch NP. Spontaneous respiration during thoracotomy in a patient with mediastinal mass. *Anesth Analg* 1987;66:904-7.
11. Tempe DK, Arya R, Dubey S, Khanna S, Tomar AS, Grover V, *et al.* Mediastinal mass resection: Femoro-femoral cardiopulmonary bypass before induction of anesthesia in the management of airway obstruction. *J Cardiothorac Vasc Anesth* 2001;15:233-6.
12. Lee PK, Booth AWG, Lloyd BS. When cardiopulmonary bypass is not an option – A case of massive retrosternal goiter with severe tracheal compression in an extremely obese patient. *J Cardiothorac Vasc Anesth* 2018;32:956-9.
13. Takeda S, Miyoshi S, Omori K, Okumura M, Matsuda H. Surgical rescue for life-threatening hypoxemia caused by mediastinal tumor. *Ann Thorac Surg* 1999;68:2324-6.