

Open Access

Warfarin-Induced Eosinophilic Pleural Effusion

Yong-Min Jo, MD, Tae-Ho Park, MD, Il-Hwan Jeong, MD, Hyun-Jeong Kim, MD, Ji-Hye Ahn, MD, Woo-Jae Kim, MD, Young-Rak Cho, MD, Hee-Kyung Baek, MD, Moo-Hyun Kim, MD and Young-Dae Kim, MD

Division of Cardiology, Department of Internal Medicine, Dong-A University College of Medicine, Busan, Korea

ABSTRACT

A 29-year-old man suffering from dyspnea and eosinophilic pleural effusion after being on warfarin for pulmonary thromboembolism for a period of one month, was readmitted to our hospital. Etiology of pleural effusion other than warfarin was excluded. To the best of our knowledge, this is the first case of warfarin-induced pleural effusion reported in Korea. (**Korean Circ J 2011;41:109-112**)

KEY WORDS: Warfarin; Pleural effusion.

Introduction

Drug-induced pleural disease is uncommon when compared to drug-induced parenchymal lung disease.¹⁾ Although the number of drugs that can cause pleural effusion is increasing, the diagnosis of drug-induced pleural effusion still remains a challenge because of the lack of diagnostic biological markers or specific pathological features currently. Eosinophilic pleural effusion has been reported in association with many drugs, including warfarin.^{2,3)} Although its pathogenesis remains unclear, eosinophilic inflammation is the most commonly proposed mechanism of warfarin-induced pleural effusion.

Case

A 29-year-old man was readmitted to our hospital because of development of a large right pleural effusion and dyspnea. One month before, he had been diagnosed with pulmonary thromboembolism of the right main pulmonary artery and

right middle and lower lobar artery (Fig. 1) and was discharged on warfarin 5 mg daily as an anticoagulant therapy and, a prothrombin time-international normalized ratio (PT-INR) was 2.65. He had a past history of atrial fibrillation and Graves' disease and there was no history of hypertension, diabetes, allergies, or pulmonary disease. In addition to warfarin, his other medications included methimazole, digoxin, furosemide, and amiodarone. On current hospital admission, his blood pressure was 130/70 mmHg, pulse was irregular and pulse rate was 90 beats per minute, respiratory rate was 18 breaths per minute, and temperature was 36.4°C. On physical examination, rales were heard in lower lung fields bilaterally. However, there was no cardiac murmur or friction rub or hepatomegaly or peripheral edema. Chest X-ray demonstrated a large right pleural effusion (Fig. 2A); there had been a history of a small pleural effusion before administration of warfarin was started (Fig. 2B). The laboratory findings were as follows: hemoglobin level 14.8 g/dL, total leucocyte count 10,550 cells/mm² (58% neutrophils, 28% lymphocytes, and 6% eosinophils), blood urea nitrogen 9 mg/dL, creatinine 0.9 mg/dL, aspartate aminotransferase 16 IU/L, alanine aminotransferase 16 IU/L, serum sodium 133 mmol/L, serum potassium 3.7 mmol/L, D-dimer >35 µg/mL. The PT-INR was 1.68 which was lower than the PT-INR at discharge. Prior to the current hospital admission, he had visited another hospital and was found to have a large right pleural effusion, which was suspected to be hemothorax and hence, warfarin was discontinued for 3 days. The tests for antinuclear antibodies, rheumatoid factor, hepatitis B surface antigen, and anti-human immunodeficiency virus antibody were negative. Sputum smear was negative for *Mycobacterium tuberculosis*.

Received: June 2, 2010

Revision Received: June 28, 2010

Accepted: June 29, 2010

Correspondence: Tae-Ho Park, MD, Division of Cardiology, Department of Internal Medicine, Dong-A University College of Medicine, 1 Dongdaesin-dong 3-ga, Seo-gu, Busan 602-715, Korea
Tel: 82-51-240-2964, Fax: 82-51-244-1713
E-mail: thpark65@dau.ac.kr

• The authors have no financial conflicts of interest.

© This is an Open Access article distributed under the terms of the Creative Commons Attribution Non-Commercial License (<http://creativecommons.org/licenses/by-nc/3.0>) which permits unrestricted non-commercial use, distribution, and reproduction in any medium, provided the original work is properly cited.

Blood and urine cultures were sterile. Cytological analysis of pleural fluid obtained at thoracentesis yielded the following results: red blood cell count 652 cells/mm², white blood cell count 2,930 cells/mm² (30% neutrophils, 20% lymphocytes, 26% eosinophils, 4% monocytes, 11% histiocytes), blood glucose level 118 mg/dL, total protein level 5.6 g/dL, albumin level 3.0 g/dL, lactate dehydrogenase level 857 IU/L, adenosine deaminase (ADA) level 24 U/L, pH 7.5, and carcinoem-

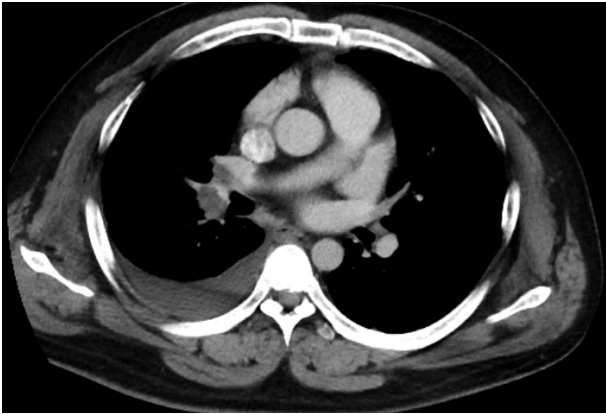


Fig. 1. Chest computed tomography showed pulmonary thromboembolism of the right main pulmonary artery and right middle and lower lobar artery.

bryonic antigen (CEA) level 1.57 µg/mL. Pleural fluid Gram stain, acid-fast bacilli (AFB) smear and cytology were all negative. The pathological diagnosis established on pleural biopsy was chronic inflammation. The pleural fluid could not be removed completely by thoracentesis, and a chest tube was inserted. Warfarin was discontinued prior to chest tube insertion, while the other drugs including amiodarone, digoxin and methimazole were continued. After insertion of the chest tube, 750 mL of an amber colored pleural fluid was drained initially. On the second day, the amount of pleural fluid drained was 350 mL. 320 mL of pleural fluid was drained on the third day, and on the fourth day 280 mL of pleural fluid was drained. After discontinuation of warfarin, PT-INR progressively decreased from 1.68 to 1.04 (Fig. 4). As the quantity of drained pleural fluid decreased, 2 mg warfarin daily was restarted as anticoagulant therapy. However, on the following day after warfarin administration was restarted, 280 mL of pleural fluid was drained on the ninth day and the amount of drained pleural fluid did not decrease while the patient was on warfarin treatment (Fig. 3). PT-INR was also slightly increased and was in a range between 1.21 and 1.38 (Fig. 4).

After exclusion of the other possible causes of pleural effusion, warfarin was suspected to have induced the pleural

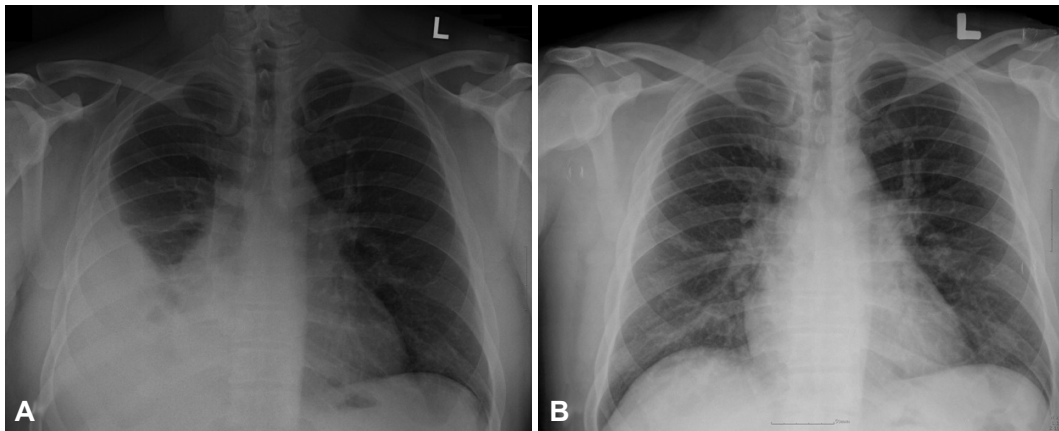


Fig. 2. Chest X-ray demonstrated a large right pleural effusion on current admission (A) and scanty pleural effusion before the warfarin administration (B).

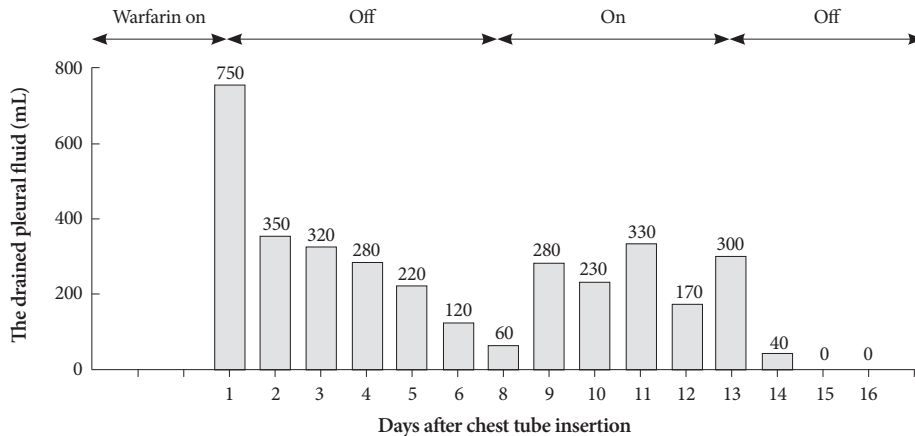


Fig. 3. The quantity of the drained pleural fluid changed after the administration of warfarin.

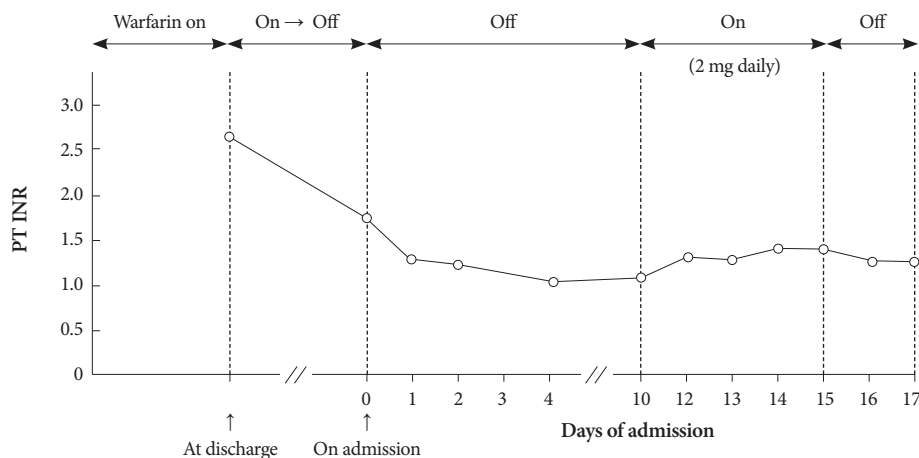


Fig. 4. The change in PT-INR and dosage of warfarin during admission. PT-INR: prothrombin time-international normalized ratio.

effusion, and after it was discontinued the quantity of pleural fluid drained decreased, symptoms resolved, and the chest tube was removed 16 days after its insertion.

Discussion

A large number of drugs are associated with the development of pleural inflammation. The presentation of drug-induced pleural disease may vary from an asymptomatic pleural effusion to acute pleuritis and to symptomatic pleural effusion. Except in some cases of drug-induced lupus pleuritis, the pathogenic mechanism for most drug-induced pleural disease remains speculative. These mechanisms include hypersensitivity, allergic reaction, direct toxic effect, increased oxygen free radical production, suppression of the antioxidant defense mechanism, and chemical-induced inflammation.^{4,5)} Approximately 30 drugs are believed to cause pleural disease, and development of pleural fluid eosinophilia has been reported in association with therapy with the following drugs: dantrolene, nitrofurantoin, fluoxetine, warfarin, glimepiride, propylthiouracil, isotretinoin, mesalamine, bromocriptine, valproic acid, tinazidine, and antibiotics such as penicillin, ceftriaxone, and streptomycin.^{2,3)} The presence of eosinophilia in pleural fluid may provide a clinical clue to the presence of drug-induced pleural disease but its presence or absence is not specific. Pleural fluid eosinophilia is defined as a proportion of eosinophils greater than ten percent of total nucleated cells in the pleural fluid.²⁾ Eosinophilia is seen in about 5 to 8% of exudative pleural effusions.⁶⁾ The important causes of pleural fluid eosinophilia include pneumothorax, hemothorax, benign asbestos pleural effusion, fungal disease, malignancy, pulmonary emboli with pulmonary infarction, parasitic infection, connective tissue diseases, and hypersensitivity reaction.^{7,8)}

In this case pleural effusion was first considered to have developed secondary to pulmonary thromboembolism. However, most pleural effusions associated with pulmonary em-

boli are small, and it is uncommon for the effusion to occupy more than one third of the hemithorax.⁹⁾ Therefore, pulmonary thromboembolism can be excluded as the cause of pleural effusion. It was observed that the volume of pleural effusion changed after the use of warfarin. Therefore, warfarin was suspected to be the cause of pleural effusion. Warfarin therapy might cause a hemothorax,¹⁰⁾ and warfarin-induced hemothorax may induce simultaneous pleural fluid and blood eosinophilia, because the presence of red blood cells in the pleural space may trigger a cellular reaction.¹¹⁾ In this case, blood eosinophilia was also noted and at 1 month prior to the current admission, maximum eosinophilia was 11% (1,142/mm³). On admission, blood eosinophil percentage decreased to 6% (633/mm³) and on the fourth day after admission it decreased to 5% (394/mm³), along with a decreased PT-INR and improved symptomatology. Although, amiodarone could have also been the cause of pleural effusion in this case, warfarin was discontinued first while amiodarone was still being continued, and subsequently there was an improvement in the patient's symptoms and a decrease in the quantity of the drained pleural fluid. Similarly, after warfarin administration was restarted, the symptoms aggravated and the quantity of the drained pleural fluid increased. Thus again, pulmonary thromboembolism and amiodarone were excluded as the causes of pleural effusion. The possibility of aspiration trauma being a cause of the exudative picture could be excluded in view of the fact that the pleural fluid was uniformly amber colored and was not hemorrhagic in nature. Using the criteria of pleural fluid ADA activity of more than 40 IU/L,¹²⁾ the possibility of tuberculosis pleurisy in this case was low. In addition, the negative AFB stain and the absence of tuberculous mycobacterial growth in culture were also helpful in excluding pleural tuberculosis in this case.

Malignancy as the cause of pleural effusion was excluded since the pleural biopsy and pleural fluid aspiration cytology were negative for malignancy, and the pleural fluid CEA level was within the normal range.

After excluding all the possible causes of exudative eosinophilic pleural effusion, warfarin was singled out to be the most probable cause of pleural effusion in this case.

Although there are several reports of drug-induced pleural effusions, warfarin-induced pleural effusion has not been reported in Korea. Warfarin-induced pleural effusion is very rare, but consideration of this possibility is important in clinical practice. Whenever a pleural effusion increases in size during warfarin use, one should consider this to be a warfarin-induced side effect.

REFERENCES

- 1) Cooper JA Jr, White DA, Matthay RA. *Drug-induced pulmonary disease (part I & II)*. *Am Rev Respir Dis* 1986;133:488-505.
- 2) Moufarrege G, Frank E, Carstens DD. *Eosinophilic exudative pleural effusion after initiation of tizanidine treatment: a case report*. *Pain Med* 2003;4:85-90.
- 3) Anshelevich IV, Svistunova AA. *Eosinophilic exudative pleurisy as a manifestation of drug allergy*. *Ter Arkh* 1986;58:142-3.
- 4) Huggins JT, Sahn SA. *Drug-induced pleural disease*. *Clin Chest Med* 2004;25:141-53.
- 5) You SH, Hong SJ, Ahn CM, Lim DS. *Eosinophilic endomyocarditis combined with pericardial and pleural effusion*. *Korean Circ J* 2009;39:545-7.
- 6) Krenke R, Nasilowski J, Korczynski P, et al. *Incidence and aetiology of eosinophilic pleural effusion*. *Eur Respir J* 2009;34:1111-7.
- 7) Martinez-Garcia MA, Cases-Viedma E, Cordero-Rodriguez PJ, et al. *Diagnostic utility of eosinophils in the pleural fluid*. *Eur Respir J* 2000;15:166-9.
- 8) Kalomenidis I, Light RW. *Eosinophilic pleural effusions*. *Curr Opin Pulm Med* 2003;9:254-60.
- 9) Stein PD, Henry JW. *Clinical characteristics of patients with acute pulmonary embolism stratified according to their presenting syndromes*. *Chest* 1997;112:974-9.
- 10) Simon HB, Daggett WM, DeSanctis RW. *Hemothorax as a complication of anticoagulant therapy in the presence of pulmonary infarction*. *JAMA* 1969;208:1830-4.
- 11) Kuwahara T, Hamada M, Inoue Y, Aono S, Hiwada K. *Warfarin-induced eosinophilic pleurisy*. *Intern Med* 1995;34:794-6.
- 12) Mo EK, Oh YM, Jung MP, et al. *A prospective study on the diagnostic value of adenosine deaminase activity in tuberculous pleural effusion*. *Korean J Med* 1995;48:625-33.