

# Usher syndrome associated with Fuchs' heterochromic uveitis: a case report

Ece Turan-Vural  
Banu Torun-Acar  
Nejla Tükenmez  
M Şahin Sevim  
Bulent Buttanri  
Suphi Acar

Ophthalmology Clinic, Haydarpaşa  
Numune Education and Research  
Hospital, Istanbul, Turkey

**Abstract:** We report a case of Usher syndrome in association with unilateral Fuchs' heterochromic uveitis.

**Keywords:** Fuchs' heterochromic uveitis, Usher syndrome, deafness, blindness

## Introduction

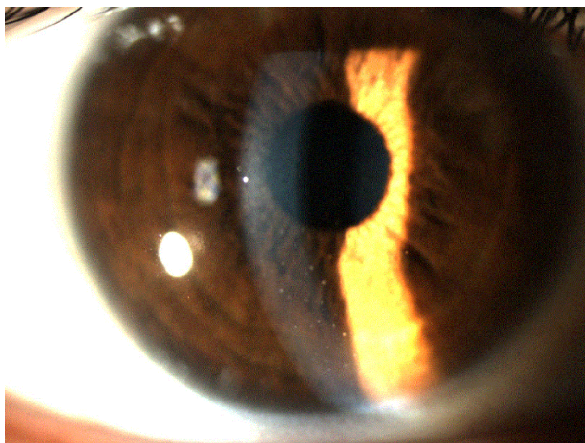
Usher syndrome is the most common cause of deafness and blindness.<sup>1</sup> The disorder has been reported to have various presentations according to age of onset, severity, hearing tests, ocular symptoms, and, more recently, electroretinographic findings. The presentations of Usher syndrome are defined as type 1, type 2, and type 3. Type 1 is the most severe, type 2 is of moderate severity (and the most common), and type 3 is of the mildest severity and has the slowest progression.<sup>1,2</sup>

Fuchs' heterochromic uveitis is a chronic nongranulomatous uveitis which is seen most commonly in patients aged 20–40 years.<sup>3</sup> Its reported incidence is 0.2%.<sup>3,4</sup> Fuchs' heterochromic uveitis accounts for 1%–6% of all cases of uveitis.<sup>4</sup> It has been associated with various retinal diseases, including toxoplasmosis and traumatic scars.<sup>3,4</sup> In this case report, we report the case of a patient with Usher syndrome in association with Fuchs' heterochromic uveitis.

## Case report

A 35-year-old woman presented to our clinic in October 2010 because of progressive bilateral reduction of vision and hearing since childhood. Systemic examination demonstrated no remarkable findings, except for hearing loss. Family history revealed that other members of the family were unaffected. Visual acuity was reduced to counting fingers at 1 m for the right eye and 2 m for the left eye. Biomicroscopic examination showed normal conjunctiva, flattened iridic crypts in the right eye, endothelial stellate keratic precipitates, a mild uveitic reaction in the anterior chamber, and bilateral intensive posterior subcapsular cataract (Figure 1). There were no associated posterior synechiae in either eye. Mild vitreous condensation was observed. Her intraocular pressures were 14 mmHg in the right eye and 16 mmHg in the left eye. Gonioscopy showed no vascular abnormality in the angle. Examination of the dilated binocular fundus demonstrated waxy pallor in the papillae, marked vasoconstriction in the retinal vessels, and retinal bone spicule pigment formation, with a normal macula (Figure 2). Optical coherence tomography showed normal macular volume and thickness. The pattern electroretinogram

Correspondence: Ece Turan-Vural  
Ophthalmology Clinic, Haydarpaşa  
Numune Education and Research  
Hospital, Haydarpaşa, Numune Eğitim  
ve Araştırma Hastanesi 2, Göz Kliniği  
Uskudar 34668 Istanbul, Turkey  
Tel +90 505 400 4628  
Fax +90 216 337 7877  
Email dreceturan76@yahoo.com

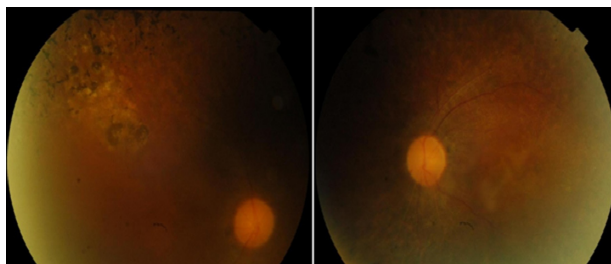


**Figure 1** Anterior segment photography of patient showing keratic precipitates.

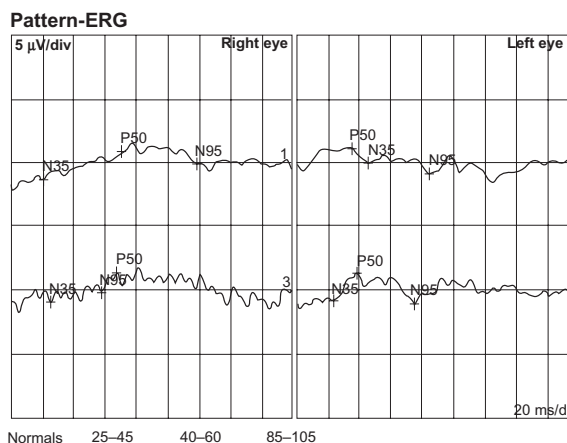
displayed a reduced response (Figure 3). A threshold hearing test showed total bilateral hearing loss. In light of these findings, we made a diagnosis of type 2 Usher syndrome associated with Fuchs' heterochromic uveitis. Relatives of the patient were not affected.

## Discussion

Usher syndrome is the most common form of combined hearing and vision loss.<sup>1,2</sup> Its frequency is reported to be 1/20000.<sup>1</sup> Usher syndrome is the most common syndrome associated with retinitis pigmentosa,<sup>5</sup> and is known to accompany 14% of cases.<sup>4</sup> There are many reports of the association of Fuchs' heterochromic uveitis and retinitis pigmentosa.<sup>4,9</sup> The etiology of Fuchs' heterochromic uveitis is not clear, and definitions involve many concurrent retinal diseases.<sup>3-6</sup> The association of retinitis pigmentosa and Fuchs' heterochromic uveitis was first reported in 1940,<sup>4</sup> and assumed to be coincidental. Since then, there have been 14 reported cases of retinitis pigmentosa associated with Fuchs' heterochromic uveitis, and the association is no longer regarded as a coincidence.<sup>4,7</sup> An autoimmune process is believed to facilitate the ocular inflammation in retinitis pigmentosa.<sup>7</sup> The association of Usher syndrome



**Figure 2** Fundus photograph right and left eye; showing bone spicule pigmentation, pale disc, and attenuated retinal vessels.



**Figure 3** Pattern ERG of the patient showing reduced response.

and Fuchs' heterochromic uveitis has only been reported twice in the literature.<sup>4</sup> Both were in patients with type 2 Usher syndrome.

In retinitis pigmentosa, retinal antigens may lead to an autoimmune antigenic reaction in the anterior chamber.<sup>4</sup> In many forms of hereditary degeneration and uveitis, autoimmune reactions have been shown against retinal S antigen, a protein of the outer segment of the retinal rod. A B cell reaction against retinal S antigen has been demonstrated in patients with retinitis pigmentosa. While S antigen reactivity is found in 15% of patients with retinitis pigmentosa, it has been found to occur in 80% of patients with Usher syndrome.<sup>4-10</sup> All the abovementioned data indicate that the association of Fuchs' heterochromic uveitis and Usher syndrome is not coincidental, and represents an autoimmune reaction.

## Disclosure

The authors report no conflicts of interest in this work.

## References

1. Kremer H, van Wijk E, Märker T, Wolfrum U, Roepman R. Usher syndrome: Molecular links of pathogenesis, proteins and pathways. *Hum Mol Genet.* 2006;15:262-270.
2. Yan D, Liu XZ. Genetics and pathological mechanisms of Usher syndrome. *J Hum Genet.* 2010;55:327-335.
3. Tugal-Tutkun İ, Güney-Tefekli E, Kamaci-Duman F, Corum I. A cross-sectional and longitudinal study of Fuchs' uveitis syndrome in Turkish patients. *Am J Ophthalmol.* 2009;148:510-515.
4. Lichtinger A, Chowers I, Amer R. Usher syndrome associated with Fuchs' heterochromic uveitis. *Graefes Arch Exp Ophthalmol.* 2010; 248:1481-1485.
5. Rosenberg T, Haim M, Haunch AM, Parving A. The prevalence of Usher syndrome and other retinal dystrophy-hearing impairment associations. *Clin Genet.* 1997;51:314-321.
6. Chowers I, Zamir E, Banin E, Merin S. Retinitis pigmentosa associated with Fuchs' heterochromic uveitis. *Arch Ophthalmol.* 2000;118: 800-802.

7. Sandinha T. Retinitis pigmentosa associated with Fuchs' heterochromic uveitis. *Eye*. 2003;14:778-779.
8. Yalvaç IS, Altıntaş AK, Gökdere A, Duman S. Fuchs' heterochromic uveitis associated with retinitis pigmentosa. *Acta Ophthalmol Scand*. 1998;76:243-244.
9. Van den Born LI, van Schooneveld MJ, de Jong PT, Bleeker-Wagemakers EM. Fuchs' heterochromic uveitis associated with retinitis pigmentosa in a father and son. *Br J Ophthalmol*. 1994;78:504-505.
10. Ruukonen PC, Metzner S, Ucer A, Torun N, Hofmann J, Pleyer U. Intraocular antibody synthesis against rubella virus and other microorganisms in Fuchs' heterochromic cyclitis. *Graefes Arch Clin Exp Ophthalmol*. 2010;248:565-571.

### Clinical Ophthalmology

## Publish your work in this journal

Clinical Ophthalmology is an international, peer-reviewed journal covering all subspecialties within ophthalmology. Key topics include: Optometry; Visual science; Pharmacology and drug therapy in eye diseases; Basic Sciences; Primary and Secondary eye care; Patient Safety and Quality of Care Improvements. This journal is indexed on

Submit your manuscript here: <http://www.dovepress.com/clinical-ophthalmology-journal>

Dovepress

PubMed Central and CAS, and is the official journal of The Society of Clinical Ophthalmology (SCO). The manuscript management system is completely online and includes a very quick and fair peer-review system, which is all easy to use. Visit <http://www.dovepress.com/testimonials.php> to read real quotes from published authors.