

OPEN

LAMS for Creation of an Anastomosis Between the Native and Donor Duodenum to Bypass a Proximal Jejunal Obstruction in a Pancreas Transplant Recipient

Jonathan A. Fridell, MD,¹ John A. Powelson, MD,¹ Andrew J. Lutz, MD,¹ and Mohammad A. Al-Haddad, MD²

INTRODUCTION

Outcomes for simultaneous pancreas and kidney transplantation (SPK) have improved in recent years, but this remains a very challenging operation, particularly in the context of reoperative surgery. Like any major abdominal operation, pancreas transplantation is associated with potential postoperative complications including bowel obstruction. Bowel obstruction is seen both early and late after pancreas transplantation and may be secondary to adhesions or internal hernia behind the pancreas.^{1,2} In terms of timing, reexploration for bowel obstruction can be performed easily and safely within the first 1–2 wk after the original surgery and there should never be any hesitation at any time interval if there is concern for bowel compromise or internal hernia. Beyond 3–4 wk, it becomes progressively more difficult to reexplore and many would recommend delaying if possible to allow postsurgical inflammation to subside and to mitigate difficult dissection owing to intraabdominal adhesions. In

these cases, patients may be maintained long-term with decompression and parenteral nutrition until surgery. In addition to being uncomfortable and frustrating for the patient, this approach is expensive and does not permit the patient to resume a normal life throughout therapy. For these reasons, an alternative nonsurgical approach would be appealing.

Endoscopic ultrasound (EUS)-guided gastroenteric anastomosis using lumen-apposing metal stents (LAMS) is an emerging, minimally invasive technique described mainly for the creation of gastrojejunostomy in patients with malignant gastric outlet obstruction.³ The use of this device to bridge other segments of the small bowel in general, and particularly in patients with surgically altered anatomy, has not been described. In this case report, we describe a complex case of proximal small bowel obstruction successfully managed with LAMS.

CASE REPORT

The patient was a 56-y-old male diagnosed at age 28 with type 2 diabetes mellitus but did not initiate insulin until age 51 y. He developed end-stage renal disease and started home hemodialysis 4 mo before evaluation and 6 mo before transplant. On presentation, this patient had a BMI of 30.6 kg/m² and a c-peptide of 0.6 ng/mL. At this time, he was on an insulin pump and was having issues with hypoglycemia.

His past medical history includes a motor vehicle accident approximately 40 y ago complicated by a pancreatic pseudocyst. Without prior records and based on current assessment of his anatomy on imaging, it seems that this was managed initially with a Roux-en-Y enteric drainage procedure and ultimately with distal pancreatectomy and splenectomy.

The patient underwent SPK on March 3, 2020. The operation was particularly difficult due to the presence of extensive dense adhesions from his prior surgeries. Ultimately, all adhesions were lysed with the exception of several particularly dense adhesions in the proximal jejunum. On imaging, it appears that this represented the enteric anastomosis portion of the Roux-en-Y, which now ends in a blind limb traveling upwards toward the stomach. The allografts were implanted ipsilaterally with pancreas allograft systemic venous drainage to the vena cava and enteric exocrine drainage created

Received 16 September 2020. Revision received 20 November 2020.

Accepted 21 November 2020.

¹ Department of Surgery, Division of Abdominal Transplant Surgery, Indiana University School of Medicine, Indianapolis, IN.

² Department of Medicine, Division of Gastroenterology, Indiana University School of Medicine, Indianapolis, IN.

M.A.A.-H. disclosed that he received teaching and research support from Boston Scientific, Inc. The other authors of this manuscript have no conflicts of interest to disclose.

J.A.F. was involved in the clinical decision making and drafted the article. J.A.P. and A.J.L. were involved in the clinical management and in the writing of the article. M.A.A.-H. was involved in the clinical decision making and in the writing of the article.

Correspondence: Jonathan A. Fridell, MD, Department of Surgery, Division of Abdominal Transplant Surgery, Indiana University School of Medicine, 550N University Blvd, Room 4601, Indianapolis, IN 46202. (fridell@iupui.edu).

Copyright © 2021 The Author(s). Transplantation Direct. Published by Wolters Kluwer Health, Inc. This is an open-access article distributed under the terms of the Creative Commons Attribution-Non Commercial-No Derivatives License 4.0 (CCBY-NC-ND), where it is permissible to download and share the work provided it is properly cited. The work cannot be changed in any way or used commercially without permission from the journal.

ISSN: 2373-8731

DOI: 10.1097/TXD.0000000000001114

using an end-to-end anastomosis stapler device between the donor duodenum and recipient proximal jejunum distal to the adhered loops of bowel as previously described.^{4,5} The donor duodenum segment typically extends from beyond the proximal staple line placed just beyond the donor pylorus in the first stage of the duodenum to the third stage about half way along the mesentery with the anastomosis created in the distal third of this segment. There were excellent pulsations in the splenic and superior mesenteric arteries and the glucoses normalized promptly. Per protocol, a postoperative contrast-enhanced ultrasound was performed before waking the recipient in the operating room⁶ and this too was normal. Induction immunosuppression included rabbit antithymocyte globulin with steroid premedication. Initial maintenance immunosuppression included tacrolimus and sirolimus.

This patient required reexploration twice during the early postoperative period. First was a negative exploration to rule out leak, and the second was a failed thrombectomy for splenic artery thrombosis but with preserved perfusion through collaterals from the superior mesenteric artery. Despite these issues, the allograft was functioning well with euglycemia independent of exogenous insulin and serum lipases within normal range.

Following the 2 reexplorations, the patient developed what seemed to be a prolonged intestinal ileus and was started on parenteral nutrition with nasogastric tube decompression. CT enteroclysis demonstrated a high-grade bowel obstruction at the level of the adhesive proximal loops of jejunum including a large dilated segment containing a staple line suggesting a small bowel anastomosis. At this point in his recovery (approximately 1 mo from the initial surgery), it was felt that relaparotomy would be very difficult due to inflammation and density of adhesions at this stage of healing in addition to the fact that we had not been successful in lysing these adhesions on prior attempts. We decided to proceed with push enteroscopy to examine this proximal jejunum with plans to place a venting gastrostomy tube. As predicted, the endoscope was not able to pass beyond these adhesive loops of jejunum. A venting gastrostomy tube was placed endoscopically, but this was later found on imaging to have traversed a segment of small intestine, which was later determined to be the previously constructed Roux-en-Y limb (now likely a blind limb). After careful review of cross-sectional imaging which confirmed proximity of the native and donor duodena, we explored the option of placing a LAMS to bypass this segment of obstructed bowel.

Under fluoroscopic and EUS guidance, the donor duodenum was accessed from the native second part of the duodenum. Saline and contrast injection using a 19G EUS needle confirmed donor duodenal anatomy and proximity to scope tip on fluoroscopy confirming that there was plenty of duodenum distal to the enteric anastomosis to accommodate the LAMS stent. Using the free-hand technique, a 15-mm × 10 mm Axios (Boston Scientific, Natick, MA) stent was placed under endosonographic, fluoroscopic, and direct endoscopic visualization effectively bypassing the obstructed segment and allowing flow through the pancreas enteric anastomosis (Figures 1 and 2). Shortly after, using the existing gastrostomy as a portal for endoscopy, a feeding jejunostomy was introduced through the LAMS and then advanced 25 cm beyond the transplanted pancreas enteric anastomosis. After slow and careful titration of tube feeds, we were able to wean the parenteral nutrition. The gastrostomy tube was used to vent as needed until gradually this was no longer required and

we were able to advance his diet with the gastrostomy tube continuously clamped. Once the patient was able to meet all caloric requirements on a nonrestricted oral diet, the gastrojejunostomy feeding tube was removed. To enhance closure and limit continued gastric fluid drainage to the roux limb previously traversed during gastrostomy placement, an over the scope clip (12/6GC, Ovesco, Tuebingen, Germany) was placed on the gastric side with complete closure (Figure 3). There was no output noted from the percutaneous fistula after this endoscopy, and the skin site healed appropriately. Currently after >7 months following the LAMS placement, the patient has completely recovered, is tolerating a regular diet and both allografts are functioning normally.

DISCUSSION

Timing and indication for reexploration for small bowel obstruction after an abdominal surgery, including abdominal transplant surgery, is a controversial issue. Many would recommend a period of nonoperative treatment including nasogastric decompression, parenteral nutrition, and hydration reserving urgent surgery for cases where there is concern regarding strangulation, vascular compromise, or closed loop obstruction. There is a brief period of several weeks following surgery where exploration is not yet complicated by the presence of inflammation and dense adhesions, but reoperation is thought to become increasingly more technically challenging and hazardous beyond this 2 wk period due to maturation of adhesions.⁷ In fact, those who had late (>13 d) reexploration had an enterotomy rate of 17% versus 5% when the reexploration occurred before 13 d.⁸ Certainly, in cases where patients REQUIRE a planned second surgery, for example, colostomy reversal following a Hartmann's procedure for diverticulitis, operating earlier (<15 wks) is associated with similar outcome in terms of morbidity and mortality, but the graded operative degree of difficulty, incidence of enterotomy and length of stay are increased.⁹ In these instances, it is typically recommended to wait for several months with a colostomy before attempting reexploration to allow postsurgical inflammation to subside and to mitigate difficult reoperations owing to intraabdominal adhesions. Complicating matters in the case presented here was the fact that, even in the absence of fresh abdominal adhesions, the obstructed loops involved included a Roux-en-Y enteric anastomosis and prior attempts to free these adhesions were unsuccessful, so the required operation would likely include either a bypass or an extensive resection in this area.

Due to the physical characteristics of LAMS, including wide flanges and a thin saddle, their off-label use for a variety of indications continues to grow. The most appealing of these is conceptually their ability to create fistulae between bowel segments under EUS guidance. In the example of EUS guided gastrojejunostomy for gastric outlet obstruction, a recent metaanalysis reported a predictably high-technical success rate of 92% and clinical success rate of 90%.¹⁰ Due to technical issues related to the thickness and stiffness of the deployment catheter and the need for a 13-mm EUS echoendoscope, placement of LAMS beyond the duodenal bulb can be very challenging. As this is a new application for LAMS, it is unknown what the risk of long-term complications may be. Certainly, the stent may occlude with time or dislodge and were the patient to require allograft pancreatectomy at some point the stent would certainly complicate this procedure. At 7 months of follow-up, however,

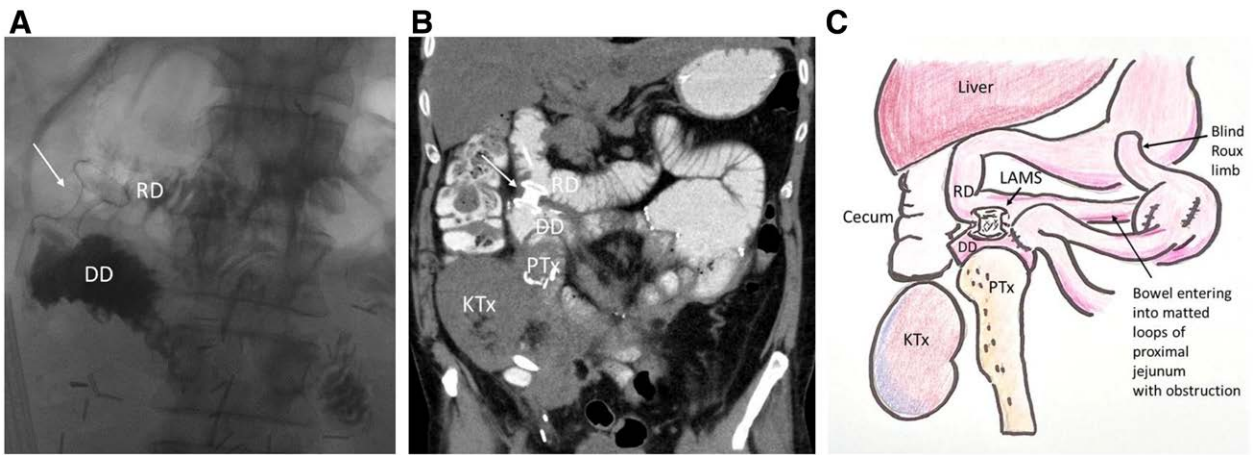


FIGURE 1. Fluoroscopic (A) and coronal cross-sectional (B) imaging and schematic representation (C) appearance of the LAMS deployed between the RD and the DD. DD, donor duodenum; KTx, kidney transplant allograft; LAMS, lumen-apposing metal stent; PTX, pancreas transplant allograft. RD, recipient duodenum.

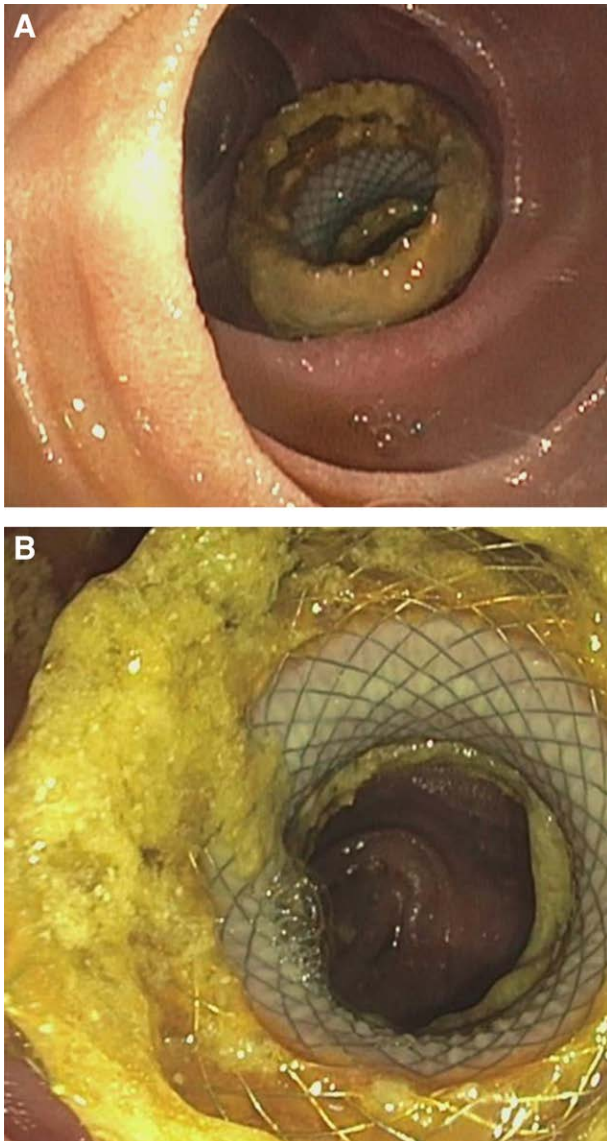


FIGURE 2. A and B, Endoscopic appearance of the LAMS as visualized from the native duodenum. LAMS, lumen-apposing metal stent.

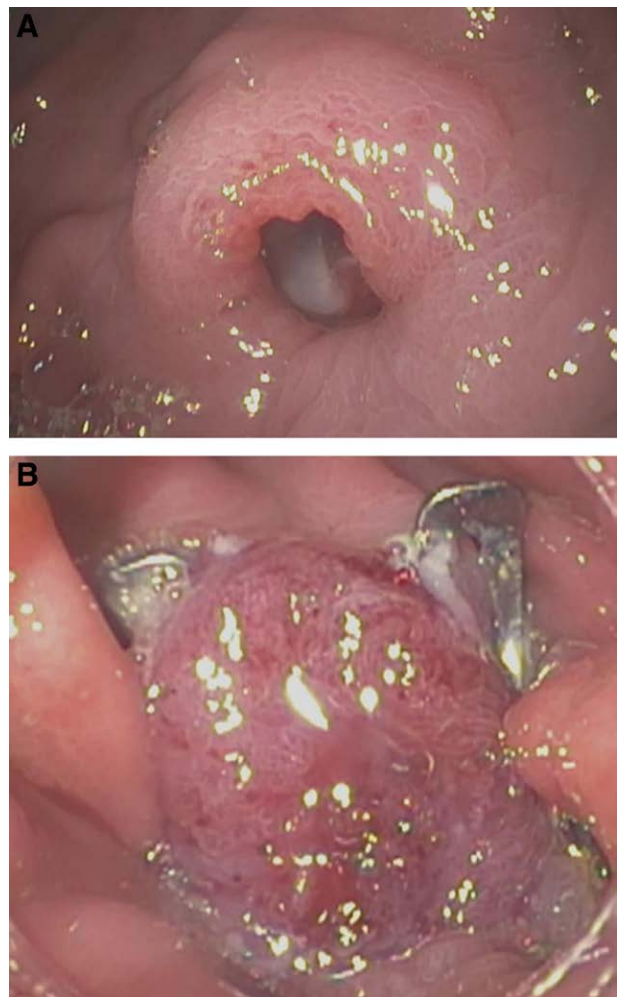


FIGURE 3. Closure of the gastric side of the gastroenteric fistula using an OTSC before (A) and after (B) the OTSC clip deployment. OTSC, over the scope clip.

there has been no evidence of any complication directly related to the use of this stent in this situation.

We report here the first case of native to donor duodenoduodenostomy accomplished in a minimally invasive

fashion to bypass a high-grade jejunal obstruction in a pancreas transplant recipient. The sustainable nature of this anastomosis saved the patient from a difficult reoperation and allowed for the ultimate resumption of oral diet with discontinuation of parenteral nutrition. A major and complex revisional surgery to take down dense adhesions in the proximal jejunum or a surgical bypass of the obstructed area was also avoided.

REFERENCES

1. Agarwal A, Maglinte DD, Goggins WC, et al. Internal hernia after pancreas transplantation with enteric drainage: an unusual cause of small bowel obstruction. *Transplantation*. 2005;80:149–152.
2. Lall CG, Sandrasegaran K, Maglinte DT, et al. Bowel complications seen on CT after pancreas transplantation with enteric drainage. *AJR Am J Roentgenol*. 2006;187:1288–1295.
3. Antonelli G, Kovacevic B, Karstensen JG, et al. Endoscopic ultrasound-guided gastro-enteric anastomosis: a systematic review and meta-analysis. *Dig Liver Dis*. 2020;52:1294–1301.
4. Fridell JA, Shah A, Milgrom ML, et al. Ipsilateral placement of simultaneous pancreas and kidney allografts. *Transplantation*. 2004;78:1074–1076.
5. Fridell JA, Milgrom ML, Henson S, et al. Use of the end-to-end anastomotic circular stapler for creation of the duodenoenterostomy for enteric drainage of the pancreas allograft [corrected]. *J Am Coll Surg*. 2004;198:495–497.
6. Swensson J, Nagaraju S, O'Brien D, et al. Contrast-enhanced ultrasound of the transplant pancreas in the post-operative setting. *Clin Transplant*. 2019;33:e13733.
7. Ong AW, Myers SR. Early postoperative small bowel obstruction: a review. *Am J Surg*. 2020;219:535–539.
8. Goussous N, Kemp KM, Bannon MP, et al. Early postoperative small bowel obstruction: open vs laparoscopic. *Am J Surg*. 2015;209:385–390.
9. Keck JO, Collopy BT, Ryan PJ, et al. Reversal of Hartmann's procedure: effect of timing and technique on ease and safety. *Dis Colon Rectum*. 1994;37:243–248.
10. McCarty TR, Garg R, Thompson CC, et al. Efficacy and safety of EUS-guided gastroenterostomy for benign and malignant gastric outlet obstruction: a systematic review and meta-analysis. *Endosc Int Open*. 2019;7:E1474–E1482.