

# A Case of CD4<sup>+</sup>T-Cell Large Granular Lymphocytic Leukemia

Jaewook Kim, M.D.<sup>1</sup>, Chan Jeoung Park, M.D.<sup>1</sup>, Seongsoo Jang, M.D.<sup>1</sup>, Young-Uk Cho, M.D.<sup>1</sup>, Sang Hyuk Park, M.D.<sup>1</sup>, Eul-Ju Seo, M.D.<sup>1</sup>, Hyun-Sook Chi, M.D.<sup>1</sup>, and Cheolwon Suh, M.D.<sup>2</sup>

Departments of Laboratory Medicine<sup>1</sup> and Internal Medicine<sup>2</sup>, University of Ulsan College of Medicine, Asan Medical Center, Seoul, Korea

We report here a case of a 59-yr-old man with CD4<sup>+</sup> T-cell large granular lymphocytic leukemia (T-LGL). Peripheral blood examination indicated leukocytosis ( $45 \times 10^9$  cells/L) that consisted of 34% neoplastic lymphoid cells. Other laboratory results indicated no specific abnormalities except for serum antinuclear antibody titer (1:640), glucose (1.39 g/L), and hemoglobin A1c (7.7%) levels. Computed tomography indicated multiple small enlarged lymph nodes (<1 cm in diameter) in both the axillary and inguinal areas, a cutaneous nodule (1.5 cm in diameter) in the left suboccipital area, and mild hepatosplenomegaly. Bone marrow examination revealed hypercellular marrow that consisted of 2.4% neoplastic lymphoid cells. The neoplastic lymphoid cells exhibited a medium size, irregularly shaped nuclei, a moderate amount of cytoplasm, and large granules in the cytoplasm. Immunohistochemical analysis indicated CD3<sup>+</sup>, CD4<sup>+</sup>, T-cell receptor  $\beta$ F1<sup>+</sup>, granzyme B<sup>+</sup>, and TIA1<sup>+</sup>. Flow cytometric analysis of the neoplastic lymphoid cells revealed CD3<sup>+</sup>, cytoplasmic CD3<sup>+</sup>, CD4<sup>+</sup>, and CD7<sup>+</sup>. Cytogenetic analysis indicated an abnormal karyotype of 46,XY,inv(3)(p21q27),t(12;17)(q24.1;q21),del(13)(q14q22)[2]/46,XY[28]. The patient was diagnosed with CD4<sup>+</sup> T-LGL and received chemotherapy (10.0 mg methotrexate). This is the second case of CD4<sup>+</sup> T-LGL that has been reported in Korea.

**Key Words:** CD4<sup>+</sup> T-LGL skin lesion, Leukocytosis

**Received:** June 27, 2012

**Revision received:** August 7, 2012

**Accepted:** November 20, 2012

**Corresponding author:** Chan Jeoung Park  
Department of Laboratory Medicine, Asan Medical Center, University of Ulsan College of Medicine, 86 Asanbyeongwon-gil, Songpa-gu, Seoul 138-736, Korea  
Tel: +82-2-3010-4508  
Fax: +82-2-478-0884  
E-mail: cjpark@amc.seoul.kr

© The Korean Society for Laboratory Medicine.

This is an Open Access article distributed under the terms of the Creative Commons Attribution Non-Commercial License (<http://creativecommons.org/licenses/by-nc/3.0>) which permits unrestricted non-commercial use, distribution, and reproduction in any medium, provided the original work is properly cited.

## INTRODUCTION

T-cell large granular lymphocytic leukemia (T-LGL) is a heterogeneous disorder that is characterized by the expansion of a discrete or monoclonal population of large granular lymphocytes in the peripheral blood (PB) [1].

T-LGL usually expresses CD3, CD8, and T-cell receptor (TCR)  $\alpha/\beta$ . CD5 and/or CD7 are variably expressed and are often aberrantly diminished on malignant circulating LGL cells [2, 3]. T-LGL typically expresses cytotoxic granular proteins such as TIA1, granzyme B, and granzyme M [4, 5]. Immunohistochemical analysis of bone marrow (BM) biopsies with antibodies to these antigens

and CD8 can be used to confirm a diagnosis of T-LGL [4-6].

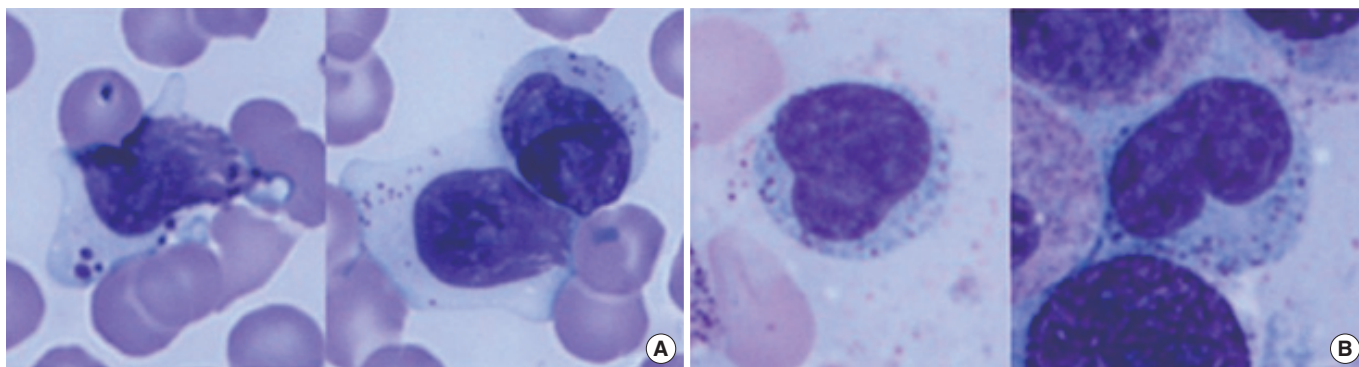
The clinical course of T-LGL is indolent in most cases [7]. CD8<sup>+</sup> T-LGL is associated with mild to moderately stable lymphocytosis, neutropenia, splenomegaly, and occasionally anemia [8]. Lymphadenopathy is very rare [9]. In addition, T-LGL demonstrates a strong association with autoimmune diseases, especially rheumatoid arthritis [8].

In contrast, the monoclonal expansion of CD4<sup>+</sup> T-LGL has been reported only sporadically in the literature [7]. It is marked by its association with malignant diseases and characteristically shows the absence of cytopenia, splenomegaly, and autoimmune disease [7]. Here, we report a case of CD4<sup>+</sup> T-LGL.

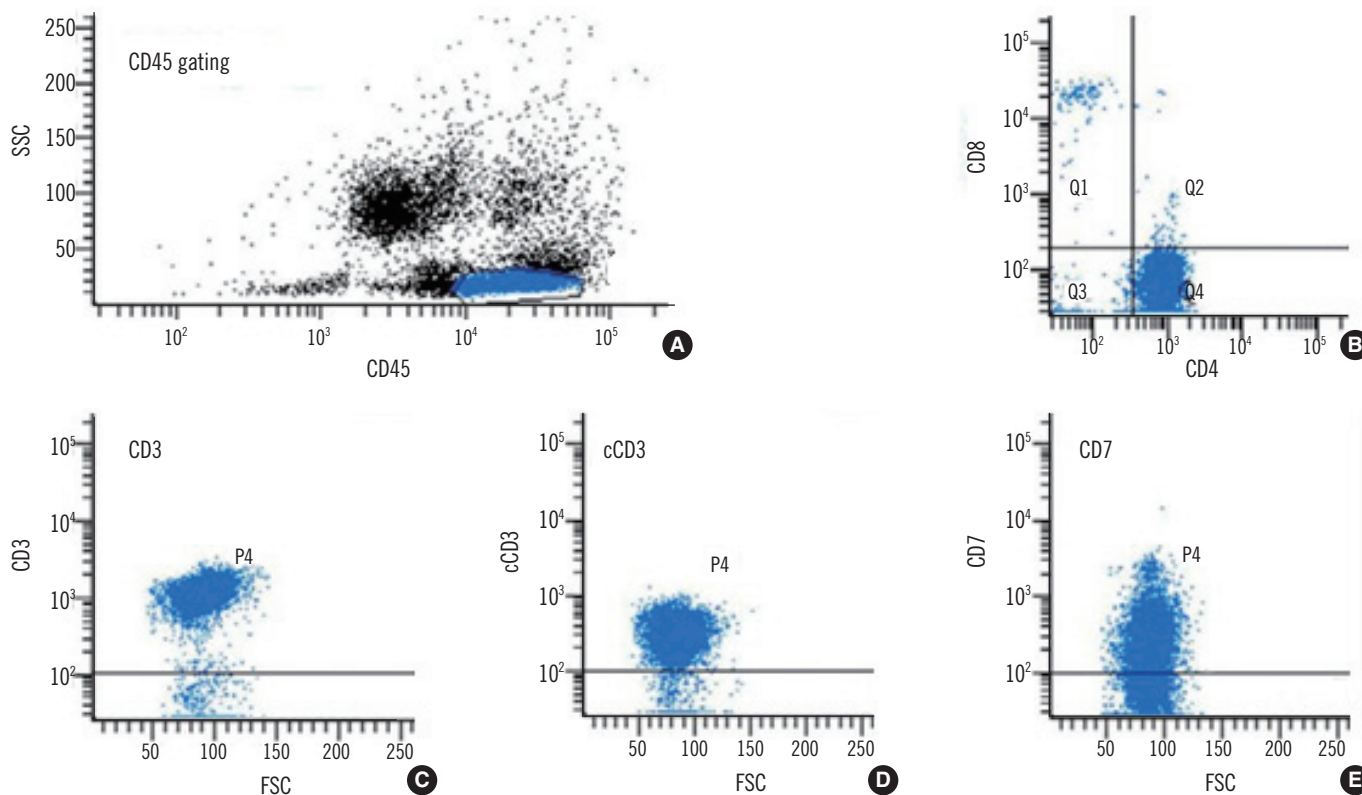
## CASE REPORT

A 59-yr-old man with a skin rash that had been present for 6 months was admitted to the hospital for an evaluation. He was diagnosed with hypertension and diabetes mellitus. PB examination revealed the following: white blood cell count,  $45 \times 10^9$

cells/L (consisting of 34% neoplastic lymphoid cells, 10% segmented neutrophils, 47% lymphocytes, 6% monocytes, and 3% eosinophils); hemoglobin, 131 g/L; mean corpuscular volume, 90.9 fL; and  $419 \times 10^9$  platelets/L. Neoplastic lymphoid cells displayed large granules (Fig. 1). PB neoplastic lymphoid cells were surface CD3<sup>+</sup>, cytoplasmic CD3<sup>+</sup>, CD4<sup>+</sup>, CD7<sup>+</sup>, CD8<sup>-</sup>, CD16<sup>-</sup>,



**Fig. 1.** Neoplastic lymphoid cells. (A) The neoplastic lymphoid cells with large cytoplasmic granules in the peripheral blood (Wright-Giemsa stain,  $\times 1,000$ ). (B) The neoplastic lymphoid cells in bone marrow aspirates with a medium, irregularly shaped nuclei, a moderate amount of cytoplasm, and large cytoplasmic granules (Wright-Giemsa stain,  $\times 1,000$ ).



**Fig. 2.** Immunophenotyping of neoplastic lymphoid cells in peripheral blood by flow cytometry. (A) Gating of neoplastic lymphoid cells with bright CD45 expression and low SSC, (B) CD4 positivity (96% among gated cells) and CD8 negativity, (C) surface CD3 positivity (95%), (D) cytoplasmic CD3 positivity (93%), and (E) CD7 positivity (73%).

Abbreviations: SSC, side scatter characteristics; FSC, forward scatter characteristics.

CD19<sup>-</sup>, CD20<sup>-</sup>, and CD56<sup>-</sup> (Fig. 2). Other laboratory results included the following: serum antinuclear antibody titer, 1:640; glucose, 1.39 g/L; hemoglobin A1c, 7.7%; total protein/albumin, 7.1/3.9 g/dL; AST/ALT, 12/12 IU/L; and total bilirubin, 5 g/L. Multiple small enlarged lymph nodes (<1 cm in diameter) in both the inguinal and axillary areas, and mild hepatosplenomegaly were noted on the abdominal and pelvic computed tomography (CT) scans. A cutaneous nodule (1.5 cm in diameter) was also observed in the left suboccipital area, but this seemed to be a reactive enlargement of the lymph nodes. BM study revealed hypercellular marrow that consisted of 2.4% neoplastic lymphoid cells. The neoplastic lymphoid cells exhibited a medium size, irregularly shaped nuclei, a moderate amount of cytoplasm, and large granules in the cytoplasm (Fig. 1). Immunohistochemical analysis of the BM biopsy showed CD3<sup>+</sup>, CD4<sup>+</sup>, TCR  $\beta$ F1<sup>+</sup>, granzyme B<sup>+</sup>, and TIA1<sup>+</sup> (Fig. 3). TCR  $\gamma$  gene rearrangement by BIOMED-2 PCR assays (InVivoScribe, San Diego, CA, USA) was negative. Cytogenetic analysis indicated an abnormal karyotype: 46,XY,inv(3)(p21q27),t(12;17)(q24.1;q21),del(13)(q14q22)[2]/46,XY[28]. The patient was diagnosed with CD4<sup>+</sup> T-LGL and received chemotherapy (10.0 mg methotrexate/week for 4 months). After the treatment, PB examination indicated the following values: white blood cell count,  $24 \times 10^9$  cells/L with 25% neoplastic lymphoid cells; hemoglobin, 137 g/L; and

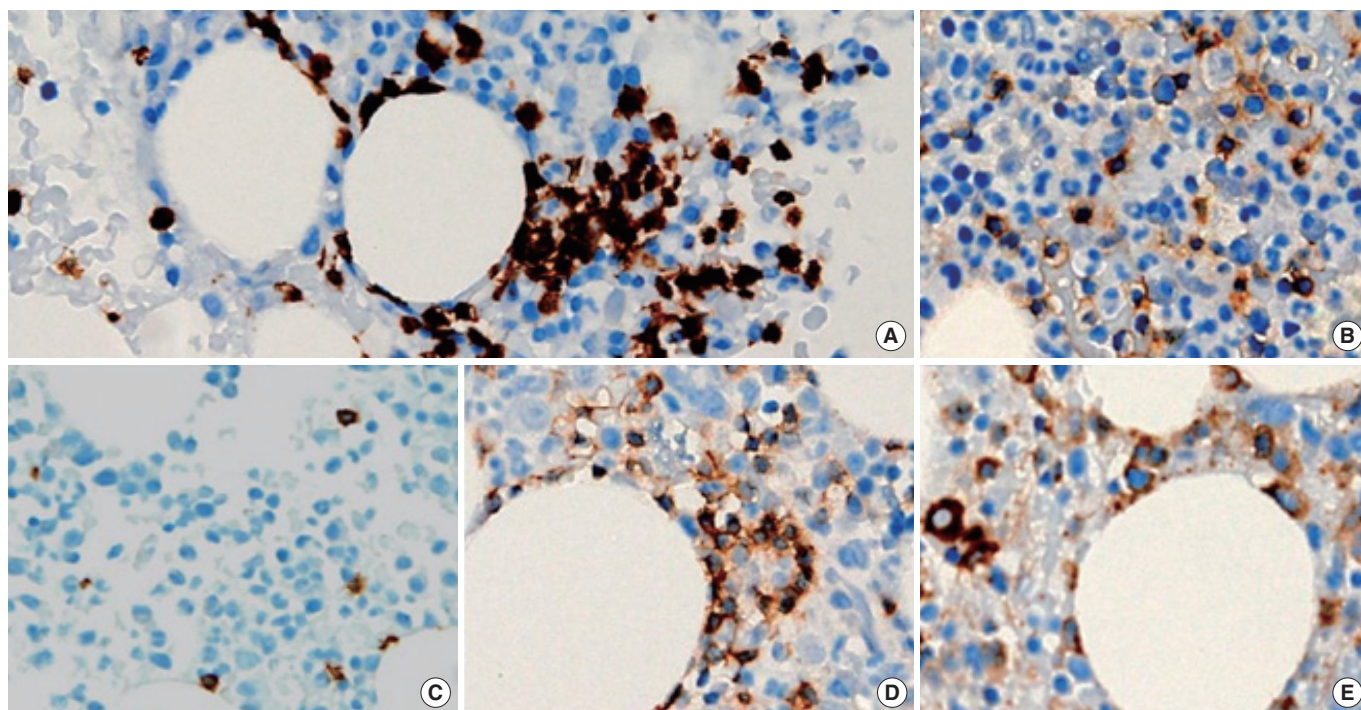
$395 \times 10^9$  platelets/L. The patient tolerated the treatment well, and his skin lesions improved.

## DISCUSSION

T-LGL represents 2% of the cases of monoclonal proliferation of B cell, T cell, and natural killer cell mature lymphocytic leukemia in Western countries [7, 9]. The male:female ratio of the reported cases is approximately one, and the majority of cases occur in the 38-72 yr age group [9, 10]. The patient described here was a 59-yr-old man.

Despite their indolent clinical behavior, clear clinical differences exist between CD4<sup>+</sup> T-LGL and the classical CD8<sup>+</sup> T-LGL, particularly with regard to the absence of neutropenia, anemia, splenomegaly, rheumatoid arthritis, or other autoimmune diseases, and the higher incidence of association with malignant diseases in the former group [7, 11]. In our case, neutropenia, anemia, rheumatoid arthritis, and other autoimmune diseases were absent. Although the patient demonstrated mild splenomegaly and was not diagnosed with any associated malignant diseases, our results support the notion that CD4<sup>+</sup> T-LGL is a clonal disorder with clinicopathological characteristics that are distinct from the more common CD8<sup>+</sup> T-LGL.

Only one case of CD4<sup>+</sup> T-LGL displaying skin lesions has been



**Fig. 3.** Immunohistochemical findings in the bone marrow biopsy. (A) CD3<sup>+</sup>, (B) CD4<sup>+</sup>, (C) CD8<sup>+</sup>, (D) T-cell receptor  $\beta$ F1<sup>+</sup>, and (E) granzyme B<sup>+</sup> (immunohistochemical stain,  $\times 400$ ).

reported so far [7]. In our case, the patient presented with a skin lesion, and this skin lesion demonstrated atypical T-cell infiltration on skin biopsy. Generally, T-LGL involves the PB, BM, liver, and spleen, but our case supports the notion that CD4<sup>+</sup> T-LGL can also involve the skin.

In our case, clonal T-cell proliferation was diagnosed after antinuclear antibodies were discovered, which suggests a role for the immune system in preferentially developing and expanding cytotoxic CD4<sup>+</sup> T-cell clones. There are data that support the hypothesis that T-LGL arises from sustained immune stimulation and associated tumors [7, 9, 12, 13], but further studies are required to establish both the relationship between CD4<sup>+</sup> T-LGL and classical CD8<sup>+</sup> T-LGL, and the clinicopathological characteristics that distinguish these leukemias.

In conclusion, in this report we described a 59-yr-old man with CD4<sup>+</sup> T-LGL. To the best of our knowledge, only one case of CD4<sup>+</sup> T-LGL has been reported in Korea so far [14], and ours is the second.

### Authors' Disclosures of Potential Conflicts of Interest

No potential conflicts of interest relevant to this article were reported.

### REFERENCES

1. Semenzato G, Zambello R, Starkebaum G, Oshimi K, Loughran TP Jr. The lymphoproliferative disease of granular lymphocytes: updated criteria for diagnosis. *Blood* 1997;89:256-60.
2. Morice WG, Kurtin PJ, Leibson PJ, Tefferi A, Hanson CA. Demonstration of aberrant T-cell and natural killer-cell antigen expression in all cases of granular lymphocytic leukaemia. *Br J Haematol* 2003;120:1026-36.
3. Lundell R, Hartung L, Hill S, Perkins SL, Bahler DW. T-cell large granular lymphocyte leukemias have multiple phenotypic abnormalities involving pan-T-cell antigens and receptors for MHC molecules. *Am J Clin Pathol* 2005;124:937-46.
4. Morice WG, Jevremovic D, Hanson CA. The expression of the novel cytotoxic protein granzyme M by large granular lymphocytic leukaemias of both T-cell and NK-cell lineage: an unexpected finding with implications regarding the pathobiology of these disorders. *Br J Haematol* 2007;137:237-9.
5. Morice WG, Kurtin PJ, Tefferi A, Hanson CA. Distinct bone marrow findings in T-cell granular lymphocytic leukemia revealed by paraffin section immunoperoxidase stains for CD8, TIA-1, and granzyme B. *Blood* 2002;99:268-74.
6. Osuji N, Beiske K, Randen U, Matutes E, Tjonnfjord G, Catovsky D, et al. Characteristic appearances of the bone marrow in T-cell large granular lymphocyte leukaemia. *Histopathology* 2007;50:547-54.
7. Lima M, Almeida J, Dos Anjos Teixeira M, Alguero Md Mdel C, Santos AH, Balanzategui A, et al. TCR $\alpha\beta$ <sup>+</sup>/CD4<sup>+</sup> large granular lymphocytosis: a new clonal T-cell lymphoproliferative disorder. *Am J Pathol* 2003;163:763-71.
8. Melenhorst JJ, Sorbara L, Kirby M, Hensel NF, Barrett AJ. Large granular lymphocyte leukaemia is characterized by a clonal T-cell receptor rearrangement in both memory and effector CD8(+) lymphocyte populations. *Br J Haematol* 2001;112:189-94.
9. Swerdlow SH, Campo E, et al. eds. WHO classification of tumors of haematopoietic and lymphoid tissues. 4th ed. Lyon: IARC, 2008:272-3.
10. Olteanu H, Karandikar NJ, Eshoa C, Kroft SH. Laboratory findings in CD4(+) large granular lymphocytoses. *Int J Lab Hematol* 2010;32:e9-16.
11. Garrido P, Ruiz-Cabello F, Bárcena P, Sandberg Y, Cantón J, Lima M, et al. Monoclonal TCR-V $\beta$ <sub>13.1</sub><sup>+</sup>/CD4<sup>+</sup>/NKa<sup>+</sup>/CD8<sup>+</sup><sup>+</sup><sup>dim</sup> T-LGL lymphocytosis: evidence for an antigen-driven chronic T-cell stimulation origin. *Blood* 2007;109:4890-8.
12. Bigouret V, Hoffmann T, Arlettaz L, Villard J, Colonna M, Ticheli A, et al. Monoclonal T-cell expansions in asymptomatic individuals and in patients with large granular leukemia consist of cytotoxic effector T cells expressing the activating CD94: NKG2C/E and NKD2D killer cell receptors. *Blood* 2003;101:3198-204.
13. Wlodarski MW, O'Keefe C, Howe EC, Risitano AM, Rodriguez A, Warsawsky I, et al. Pathologic clonal cytotoxic T-cell responses: nonrandom nature of the T-cell-receptor restriction in large granular lymphocyte leukemia. *Blood* 2005;106:2769-80.
14. Song SH, Chung SM, Hwang DW, Choi JY, Yoo KD, Hong HS, et al. T-cell large granular lymphocytic leukemia: A case report. *Korean J Hematol* 2009;44:139-43.