

Secondary Torsion of Vermiform Appendix with Mucinous Cystadenoma

Maki Kitagawa^a Tatsuya Kotani^a Takeshi Yamano^b
Hideaki Tsurudome^a Tomoya Hatakeyama^a
Yoshiaki Kuriu^a Hiroshi Nishi^a Masaharu Yabe^a

Departments of ^aSurgery and ^bPathology, Saiseikai Kyoto Hospital, Nagaokakyo, Kyoto, Japan

Key Words

Torsion · Appendix · Mucinous cystadenoma

Abstract

Torsion of the vermiform appendix is a rare disorder, which causes abdominal symptoms indistinguishable from acute appendicitis. We report a case (a 34-year-old male) of secondary torsion of the vermiform appendix with mucinous cystadenoma. This case was characterized by mild inflammatory responses, pentazocine-resistant abdominal pain, and appendiceal tumor, which was not enhanced by the contrast medium on computed tomography presumably because of reduced blood flow by the torsion. These findings may be helpful for the preoperative diagnosis of secondary appendiceal torsion.

Introduction

The vermiform appendix is a blind ended gastrointestinal tract, which is connected to the cecum. It averages 6.5 cm (ranging from 1 to 20 cm) in length. The longest appendix ever reported measured 23.5 cm in length. Diseases of the appendix are the most common causes of acute abdomen. Among them, torsion of the vermiform appendix is a rare disorder, which causes abdominal symptoms indistinguishable from acute appendicitis, the most common disorder of the appendix. In 1918, Payne et al. reported the first case of torsion of the appendix [1]. Since then, more than thirty cases have been described in the English language literature along with several cases in the non-English language literature (table 1) [1–13]. Torsion of the appendix may occur at any age (mean 23 years; range 3–60 years). Fourteen cases in children and seventeen cases in adults are reported. In children (mean 9.1 years; range 3–18 years), eleven cases are male and three cases are female. In adults, seven cases are male and ten cases are female. Primary and secondary

torsion are recognized in the appendiceal torsion. Twenty-five among thirty-two cases are found to be primary torsion. In primary torsion, specimen examination shows secondary ischemic or necrotic change and luminal dilatation distal to the torsion site without any primary lesion. Secondary torsion caused by appendiceal abnormality is much rarer. Only 6 cases (one cystadenoma, three simple mucoceles, one fecalith impaction and one malformation) have been reported to date. Here, we report a case of secondary torsion of the vermiform appendix with mucinous cystadenoma, and review the literature on appendiceal torsion.

Case Report

A 34-year-old male complained of periumbilical abdominal pain continuing for two days. The pain persisted despite administration of pentazocine. There was no significant previous medical history. On physical examination, his body temperature was 36.7°C, pulse 78 beats/min, and blood pressure 110/70 mm Hg. Bowel sounds were diminished. There were tenderness and rebound tenderness in the right lower quadrant area with muscular guarding. Peripheral blood examination showed a white blood cell (WBC) count of 8,600/mm³ (78% neutrophils, 15% lymphocytes, and 7% monocytes) and C-reactive protein (CRP) of 4.35 mg/dl. Hemoglobin and hematocrit values were 14.6 g/dl and 44.9%, respectively. Carcinoembryonic antigen (1.5 ng/ml) and serum electrolyte levels were within normal limits [14]. Abdominal X-ray examination revealed small-intestinal dilatation with air-fluid level. Abdominal computed tomography (CT) examination suggested a fluid-filled cyst originating in the vermiform appendix (fig. 1a–c). The cyst wall was not enhanced by the contrast medium. This finding contrasted well with that in a case of acute appendicitis caused by fecalith, in which thickened appendiceal wall was enhanced by the contrast medium (fig. 1i). After 6 h, peripheral blood was reexamined, giving a WBC count of 8,100/mm³ and CRP of 4.42 mg/dl. Laparotomy was done on the suspected diagnosis of appendiceal tumor, which may be complicated by inflammation. Through a pararectus incision, a small amount of serosanguinous fluid and a deep purple cystic tumor came out. The cytological examination of the ascites revealed no malignancy. The tumor was 10 cm in length and 4 cm in diameter, and originated in the appendix. It was twisted 180° in a clockwise direction with ischemic change (fig. 1d). The abdominal pain was abruptly relieved before the laparotomy presumably because of spontaneous relief of the torsion as indicated by mild rotation (180°) of the tumor observed at laparotomy. A simple appendectomy was performed. Histological examination of the specimen revealed that the proximal 1 cm was normal appendix and the distal 10 cm was a monocystic mucinous cystadenoma, which was filled with yellow-colored degenerated mucin (fig. 1e, f). The inner surface was lined by pseudostratified columnar epithelium with slight nuclear atypia. Subepithelial tissue showed dense fibrosis and mild inflammation (fig. 1g, h). Subserosal adipose tissue showed some hemorrhage and necrosis, and there was perivascular inflammatory cell infiltration. The histological findings were compatible with the ischemic and necrotic changes caused by the torsion. Postoperative recovery was uneventful, and postoperative total colonoscopy revealed no abnormality in the cecum.

Discussion

Acute appendicitis is the most common disorder in patients complaining of right lower abdominal pain. By contrast, torsion of the vermiform appendix is a rare disorder. Primary and secondary torsion of the vermiform appendix are recognized. Primary torsion appears to be often associated with long appendix. Secondary torsion is reported to be associated with cystadenoma, mucocele, fecalith impaction, and malformation of the appendix (table 1). Here, we report a case of secondary torsion of the appendix, which is associated with mucinous cystadenoma. Cystadenoma of the appendix is also a rare condition, and is usually diagnosed intraoperatively or postoperatively on the pathology report. To our knowledge, this is the second case of secondary torsion of the vermiform

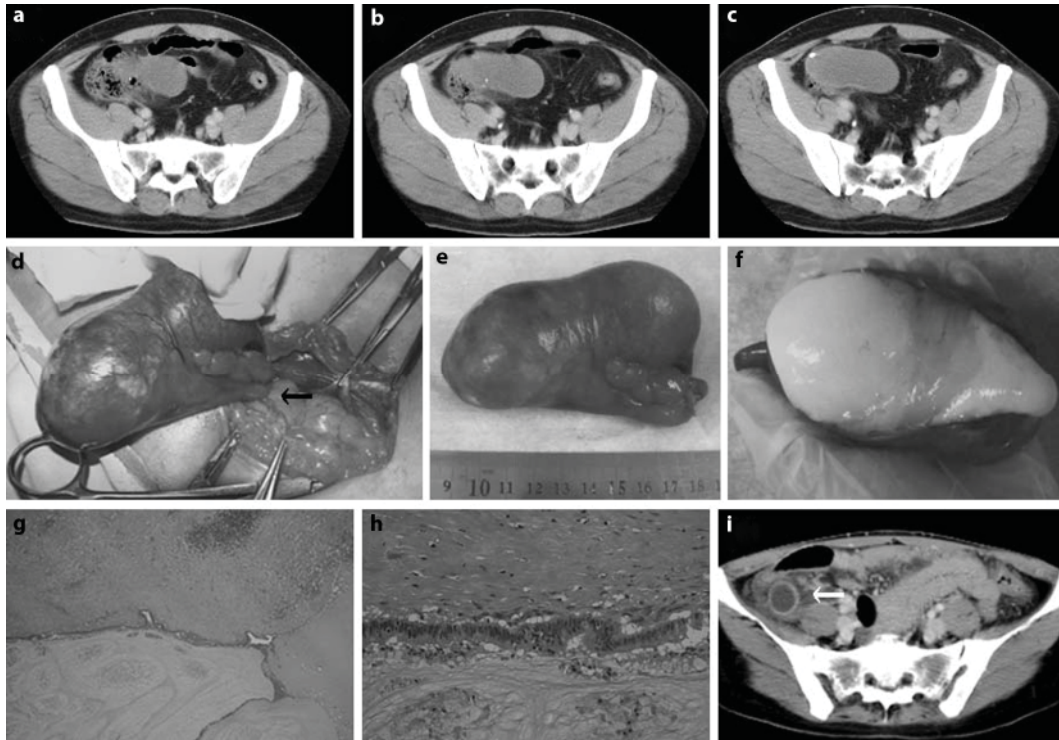
appendix associated with appendiceal cystadenoma. This case showed abdominal pain indistinguishable from acute appendicitis, and was characterized by mild inflammatory responses on the basis of the values of a WBC count and CRP, pentazocine-resistant abdominal pain, and appendiceal tumor, which was not enhanced by the contrast medium on CT presumably because of impaired or reduced blood flow by the torsion. Mild inflammatory responses [3, 5, 7–11, 13] and pentazocine-resistant abdominal pain [3] have been reported in some cases of appendiceal torsion. In this case, besides mild inflammatory responses and pentazocine-resistant abdominal pain, CT examination was helpful for the preoperative diagnosis of secondary appendiceal torsion and appendiceal tumor complicated by inflammatory events including torsion.

Table 1. Cases of appendiceal torsion reported in the English literature

Authors	Year	Age	Sex	Degree/direction of rotation	Length of appendix, cm	Etiology or complication
Payne	1918	37	F	1,080/–	7	Fecalith impaction*
Beyers	1920	35	F	720/–	7.6	UD
Mcfadden	1926	UD	M	180/–	12.7	UD
Flatley	1936	22	F	900/–	10.8	UD
Dickson	1953	60	F	720/–	11.5	Simple mucocele*
Carter	1959	8	F	>360/AC	–	UD
King-Pan	1965	18	F	–/–	10	Simple mucocele*
Ghent	1966	21	M	450/AC	–	Primary
		12	M	>360/C	7	Primary
Killam	1969	47	M	–/–	–	Mesoappendiceal lipoma
De Bruin	1969	28	F	360/–	10.5	UD
Legg	1973	29	M	360/–	10	UD
Finch	1974	38	F	360/–	–	UD
		12	M	270/AC	–	UD
Won	1977	35	M	–/–	12	UD
William	1983	4	M	270/AC	–	UD
Dewan	1986	3	M	720/AC	–	UD
		6	F	1080/C	7	UD
		16	M	–/–	–	UD
Waters	1986	3	M	720/–	–	UD
Abu Zidan	1992	32	F, pregnant	–/C	5.9	Mucocele*
Merret	1992	14	M	720/AC	14	Normal appendix
Fernando	1995	6	M	>360/AC	13.5	UD
Petersen	1998	44	M	540/–	5.5	UD
Uroz-Tristan	1998	5	M	360/AC	–	Absent mesoappendix
Tzilinis	2002	44	M	540/C	5.5	Primary
Moten	2002	44	F	360/AC	–	Cystadenoma*
Oguzkurt	2004	2	M	270/AC	10	Duplicated colon and appendix*
Bowling	2006	Adult	F	–/–	8	UD
Bestman	2006	35	F	–/–	7.5	Primary
Sarin	2006	9	M	270/C	8	Normal appendix
Present case	2007	34	M	180/C	10	Mucinous cystadenoma*

C = Clockwise; AC = anticlockwise; M = male; F = female; UD = undefined. * Secondary torsion.

Fig. 1. **a–c** Enhanced abdominal CT examination showed a cyst originating in the vermiform appendix. The cyst wall was not enhanced by the contrast medium. **d** The tumor originated in the appendix and was twisted 180° in a clockwise direction (arrow). **e** The resected tumor was 10 cm in length and 4 cm in diameter. **f** The specimen contained yellow-colored degenerated mucin. **g**, **h** Histological examination. The inner surface was lined by pseudostratified columnar epithelium with slight nuclear atypia. Subepithelial tissue showed dense fibrosis and mild inflammation. Original magnification: **g** ×20; **h** ×200. **i** Enhanced abdominal CT examination in a case of acute appendicitis caused by fecalith. Appendiceal lumen distal to fecalith was dilated and the thickened appendiceal wall was enhanced by the contrast medium (arrow).



References

- 1 Payne LE: A case of torsion of the appendix. *Br J Surg* 1918;6:327.
- 2 Val-Bernal JF, Gonzalez-Vela C, Garijo MF: Primary acute torsion of the vermiform appendix. *Pediatr Pathol Lab Med* 1996;16:655–661.
- 3 Tzilinis A, Vahedi MH, Wittenborn WS: Appendiceal torsion in an adult: case report and review of the literature. *Curr Surg* 2002;59:410–411.
- 4 Moten AL, Williams RS: Torsion of the appendix. *Med J Aust* 2002;177:632.
- 5 Bestman TJ, van Cleemput M, Detournay G: Torsion of the vermiform appendix: a case report. *Acta Chir Belg* 2006;106:228–229.
- 6 Oguzkurt P, Oguzkurt L, Kayaselcuk F, Oz S: An unusual cause of acute abdomen: torsion of colonic duplication over a duplicated appendix. *Pediatr Surg Int* 2004;20:722–723.
- 7 Uroz-Tristan J, Garcia-Urgelles X, Poenaru D, Avila-Suarez R, Valenciano-Fuentes B: Torsion of vermiform appendix: value of ultrasonographic findings. *Eur J Pediatr Surg* 1998;8:376–377.
- 8 Mazza D, Fabiani P, Casaccia M, Baldini E, Gugenheim J, Mouiel J: A rare laparoscopic diagnosis in acute abdominal pain: torsion of epiploic appendix. *Surg Laparosc Endosc* 1997;7:456–458.
- 9 Merrett ND, Lubowski DZ, King DW: Torsion of the vermiform appendix: a case report and review of literature. *Aust N Z J Surg* 1992;62:981–983.
- 10 Abu Zidan FM, al-Hilaly MA, al-Atrabi N: Torsion of a mucocele of the appendix in a pregnant woman. *Acta Obstet Gynecol Scand* 1992;71:140–142.
- 11 Killam AR: An unusual cause of appendicitis: torsion produced by a mesoappendiceal lipoma. *Am Surg* 1969;35:648–649.
- 12 Ghent WR, Carnovale BV: Primary volvulus of the appendix. *Can Med Assoc J* 1966;95:926–927.
- 13 King-Pan C: Volvulus complicating mucocele of the appendix. *Br J Surg* 1965;52:9.
- 14 Shimizu T, Shimizu M, Kawaguchi K, Yomura W, Ihara Y, Matsumoto T: Mucinous cystadenoma of the appendix with raised serum carcinoembryonic antigen concentration: clinical and pathological features. *J Clin Pathol* 1997;50:613–614.