

Clinical Paper

# Metastasis of Renal Cell Carcinoma to the Stomach Twenty One Years from Initial Diagnosis

Stuart McIlwaine,<sup>1</sup> Mark Haynes,<sup>2</sup> Neal Morgan,<sup>3</sup> Rajeev Shah,<sup>4</sup> James Doyle<sup>5</sup>

## ABSTRACT

A female in her 80's presented to our Emergency Department following a fall. She reported general malaise, weight loss and raised inflammatory markers. Background included renal cell carcinoma 21 years previous, managed with radical nephrectomy. During her inpatient stay she had an episode of haematemesis. Upper GI endoscopy revealed a 3cm polypoidal lesion on the greater curve of the upper stomach. This had an irregular pit pattern endoscopically and was friable. Multiple biopsies revealed metastatic clear cell carcinoma of renal origin; the same sub-type as her previous renal tumour. This is a rare manifestation of metastatic renal cell carcinoma and from literature review, is only the 2<sup>nd</sup> case we can find with a lag time of >20 years from the initial diagnosis to presenting with metastatic gastric disease.

**Keywords:** Gastric Disease, Gastrointestinal Bleeding

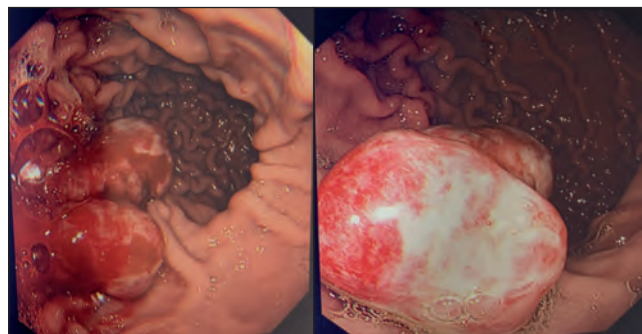
## CASE REPORT

A female patient in her 80's was admitted to hospital following a fall, with general malaise, weight loss and raised inflammatory markers. She was commenced on broad-spectrum antimicrobial therapy. A CT A/P revealed no evidence of any intra-abdominal sepsis.

In 1999 she underwent radical left sided total nephrectomy for Renal Cell Carcinoma (RCC). The histopathology confirmed clear cell renal cell carcinoma showing nested aggregates of cells with abundant clear finely granular cytoplasm and areas showing tubular differentiation. Images of these slides were unfortunately not obtainable. Her background co-morbidities include.

- Previous Renal Cell Carcinoma (as mentioned above).
- Atrial fibrillation on Warfarin
- End stage renal disease of multifactorial origin managed on peritoneal dialysis
- Hypertension
- Hypothyroidism

During the admission she suffered an acute episode of haematemesis. An OGD revealed a friable 3cm polypoidal lesion on the greater curve (Figures 1 and 2) with an irregular pit pattern. Multiple biopsies were obtained revealing nests of tumour cells with clear cytoplasm and stained positive for PAX 8, AE1/AE3 and EMA. The morphological and



**Figures 1 and 2** Polypoidal lesion on greater curve

immunohistochemical features were entirely in keeping with metastatic clear cell adenocarcinoma of renal origin, notably the same cellular subtype as her previous RCC. (Figures 3,4,5, and 6).

A staging CT chest showed bilateral pulmonary lesions consistent with metastatic disease. The CT abdomen and pelvis done just after admission showed the remaining kidney to be slightly atrophic with simple cysts, but no new primary site identified. In 2015 two small pulmonary nodules had been detected incidentally during a CT pulmonary angiogram study. These lesions were not biopsied but followed up by serial CT PET and CT imaging. They had changed minimally in size over a 5 year surveillance period and may well have represented foci of pulmonary metastatic disease. Our patient did not wish for further investigation or consideration of therapy and she was discharged from hospital with her family.

## DISCUSSION

Renal cell carcinoma is the seventh most common cancer in the UK, with Clear Cell Carcinoma accounting for more than 80% of these cases<sup>1</sup>. Multiple risk factors are

<sup>1</sup> Core Medical Trainee, Daisy Hill Hospital

<sup>2</sup> Consultant Urologist, Daisy Hill Hospital

<sup>3</sup> Consultant Nephrologist, Daisy Hill Hospital

<sup>4</sup> Consultant Pathologist, Craigavon Area Hospital

<sup>5</sup> Consultant Gastroenterologist, Daisy Hill

**Correspondence to:** James Doyle  
Daisy Hill Hospital,  
Southern Health and  
Social Care Trust,  
Newry, UK

**Email:** James.Doyle@southerntrust.hscni.net



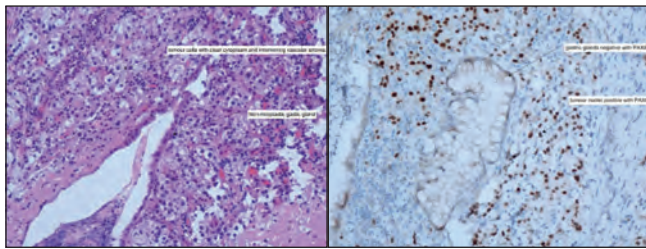


Figure 3 – H&amp;E stain

Figure 4 – Positive PAX 8 Immunostain

associated, including increased age, obesity, smoking, long-term dialysis and exposure to compounds including asbestos, cadmium or petroleum products. Genetic syndromes are also involved such as von Hippel-Lindau and tuberous sclerosis<sup>1</sup>. Recurrence is common after nephrectomy with 60% of patients suffering distant relapse within 5 years of surgical intervention<sup>2</sup>. Leibovich scoring has been utilized in Clear Cell Renal Carcinoma to predict the risk of disease progression following radical nephrectomy. It classifies patients into low, medium or high risk based on the clinical and pathological features present at the time of nephrectomy, and estimates metastasis free survival in years. Low risk cases have a mean metastasis-free survival of 7.4 years vs high risk at 1.7 years<sup>3</sup>. Clear Cell Renal Carcinoma is thought to spread by lymphatic, hematogenous, transcoelomic routes, or through direct invasion<sup>4</sup>.

Gastric Metastases are relatively rare findings shown by autopsy cases with solid malignancies. Oda et al, found that Gastric metastatic lesions were present in 5.4% of patients: with lung, breast, and oesophagus being the most common primary sites. Renal Cell Carcinoma metastasised to the stomach in 6.2% of cases<sup>5</sup>.

Specifically in relation to RCC one review reported the average age at presentation of gastric metastases is 59.1 years with an extensive lag period before metastasis averaging 7 years (range 0-20 years) since the diagnosis of the primary RCC. The interval in our patient was 21 years. From our literature review this is nearly the longest ever

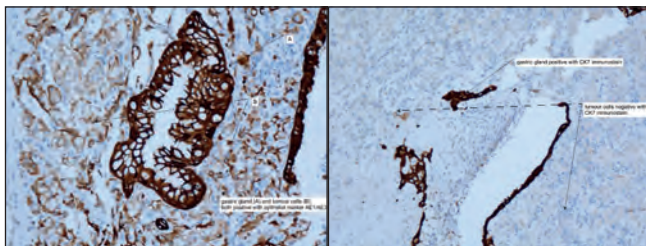


Figure 5 – Positive AE1/ AE3 Immunostain

Figure 6 – Negative CK7 Immunostain

reported interval between RCC diagnosis and discovery of gastric metastatic disease, only surpassed by a single report of a case 23 years after initial RCC diagnosis<sup>6,7,8</sup>. This shows the importance of considering all possible diagnoses with histopathology sampling when endoscopic findings are similar to that of a primary gastric malignancy.

It is important to recognise that the most common presenting signs associated with gastric metastasis from RCC are upper gastrointestinal bleeding and iron deficient anaemia. The most common site of lesion is reported as the gastric body and more likely to be a solitary mass or ulcer. These findings are in keeping with our case<sup>9</sup>.

This case highlights a few key points.

1. It is important to be vigilant when performing diagnostic endoscopy and consider appropriate differential diagnoses of any findings that may prompt further investigation. Renal cell carcinoma metastases are typically vascular and whilst histologic diagnosis is most valuable, biopsy must be undertaken with care. In the event of haemorrhage, embolisation has been cited as first line management for these gastrointestinal sites due to vascular supply<sup>10</sup>.
2. Metastatic malignancy (in this case from RCC) is an uncommon finding during endoscopy but is an important diagnosis to be made. Renal cell carcinoma can recur late - up to 23 years after initial remission from primary disease.

## REFERENCES

1. Cancer Research UK . Kidney cancer statistics. [monograph on the Internet]. Oxford: Cancer Research UK. [Cited: 2020 Jul 31]. Available from: <https://www.cancerresearchuk.org/health-professional/cancer-statistics/statistics-by-cancer-type/kidney-cancer#heading=Zero>.
2. Janzen NK, Kim HL, Figlin RA, Beldegrun AS. Surveillance after radical or partial nephrectomy for localized renal cell carcinoma and management of recurrent disease. *Urol Clin North Am*. 2003;30(4):843–52
3. Leibovich BC, Blute ML, Cheville JC, Lohse CM, Frank I, Kwon ED, et al. Prediction of progression after radical nephrectomy for patients with clear cell renal cell carcinoma: a stratification tool for prospective clinical trials. *Cancer*. 2003;97(7):1663–71.
4. Tiwari P, Tiwari A, Vijay M, Kumar S, Kundu AK. Upper gastrointestinal bleeding - Rare presentation of renal cell carcinoma. *Urol Ann*. 2010;2(3):127–9
5. Oda I, Kondo H, Yamao T, Saito D, Ono H, Gotoda T, et al. Metastatic tumors to the stomach: analysis of 54 patients diagnosed at endoscopy and 347 autopsy cases. *Endoscopy*. 2001;33(6):507–10.
6. Onorati M, Petracco G, Ubaldi P, Redaelli DG, Romagnoli S, Albertoni M, et al. A solitary polypoid gastric metastasis 20 years after renal cell carcinoma: an event to be considered, and a brief review of the literature. *Pathologica*. 2013;5(4):132–6.
7. Kim MY, Jung HY, Choi KD, Song HJ, Lee JH, Kim DH, et al. Solitary synchronous metastatic gastric cancer arising from T1b renal cell carcinoma: a case report and systematic review. *Gut Liver*. 2012;6(3):388–94.
8. Namikawa T, Iwabu J, Kitagawa H et al. Solitary gastric metastasis from a renal cell carcinoma, presenting 23 years after radical nephrectomy. *Endoscopy*. 2012;44 Suppl 2 UCTN:e177–8. doi: 10.1055/s-0031-1291751.
9. Xu J, Latif S, Wei S. Metastatic renal cell carcinoma presenting as gastric polyps: a case report and review of the literature. *Int J Surg Case Rep*. 2012;3(12):601–4.



10. Ohmura Y, Ohta T, Doihara H, Shimizu N. Local recurrence of renal cell carcinoma causing massive gastrointestinal bleeding: a report of two patients who underwent surgical resection. *Jpn J of Clin Oncol.* 2000;30(5):241-5

