

Chronic total coronary occlusion recanalization: Current techniques and new devices



Jan-Erik Gülker^{a,b,*}, Lars Bansemir^{a,b}, Heinrich G. Klues^{a,b}, Alexander Bufe^{a,b,c}

^a Heart Centre Niederrhein, Department of Cardiology, HELIOS Clinics Krefeld, Krefeld

^b Institute for Heart and Circulation Research, University of Cologne, Kerpener Straße 62 50937, Cologne

^c Witten/Herdecke University, Witten

^{a,b,c} Germany

Percutaneous coronary intervention (PCI) of total chronic coronary occlusion (CTO) still remains a major challenge. The prevalence of a CTO has been reported to be up to 30% among patients with a clinical indication for coronary angiography. Progress has been made with further advanced interventional techniques and continuously sophisticated interventional tools. Nevertheless the number of interventions carried out to recanalize a CTO is less than 10% of all procedures. Benefits of a successful CTO recanalization include relief of angina pectoris and ischemia-related dyspnea, substantial improvement in left ventricular function and, avoidance of surgery treatment. A vast variety of new CTO PCI techniques and materials has been introduced into clinical practise and pushed success rates of reopening a CTO up to around 90% in experienced hands. Particular the introduction of the retrograde technique was a milestone. New developed microcatheters and special polymer coated wires allow to recanalize via small collaterals and vessels. Other tools such as intravascular ultrasound (IVUS) and multislice computertomography (MSCT) help to identify the anatomy and the characteristic of the lesions. Any invasive cardiac center should adopt CTO PCI procedures as standard therapy.

Objective: This review wants to assess and describe the latest development in CTO recanalization strategies.

© 2016 The Authors. Production and hosting by Elsevier B.V. on behalf of King Saud University. This is an open access article under the CC BY-NC-ND license (<http://creativecommons.org/licenses/by-nc-nd/4.0/>).

Keywords: Latest development, Chronic total occlusion, Coronary artery disease, Technical innovation, Recanalization strategies

Contents

Introduction	111
Benefits	111
New techniques	112
Parallel wire strategy and see-saw technique	112
Anchor wire and anchor balloon techniques	112

Disclosure: Authors have nothing to disclose with regard to commercial support.

Received 28 June 2016; revised 5 August 2016; accepted 12 August 2016.
Available online 20 August 2016

* Corresponding author at: Heart Centre Niederrhein, Department of Cardiology, HELIOS Clinics Krefeld, Lutherplatz 40, 47805 Krefeld, Germany.

E-mail address: jan-erik.guelker@helios-kliniken.de (J.-E. Gülker).



P.O. Box 2925 Riyadh – 11461KSA
Tel: +966 1 2520088 ext 40151
Fax: +966 1 2520718
Email: sha@sha.org.sa
URL: www.sha.org.sa



1016–7315 © 2016 The Authors. Production and hosting by Elsevier B.V. on behalf of King Saud University. This is an open access article under the CC BY-NC-ND license (<http://creativecommons.org/licenses/by-nc-nd/4.0/>).

Peer review under responsibility of King Saud University.
URL: www.ksu.edu.sa
<http://dx.doi.org/10.1016/j.jsha.2016.08.003>



Production and hosting by Elsevier

IVUS-guided wiring.....	112
The true retrograde technique	112
The controlled antegrade and retrograde tracking and reverse controlled antegrade and retrograde tracking techniques.....	113
New materials and tools	114
Complications	114
Conclusions	114
References.....	114

Introduction

Chronic total coronary occlusion (CTO) is defined as an occlusion lasting longer than 3 months following thrombolysis in myocardial infarction flow grade 0 within the occluded segment [1]. The prevalence of a CTO has been reported to be up to 30% among patients with a clinical indication for coronary angiography [2]. Despite this high prevalence, the number of interventions carried out to recanalize a CTO is <10% of all procedures [3].

The main reasons for this mismatch are significant technical challenges, a huge shortage of sophisticated and specialized interventionalists, the considerable time resources needed for the revascularization procedures, and a comparatively low level of reimbursement [4].

An additional barrier is an overestimated increased risk of CTO-percutaneous coronary intervention (PCI) with suspected severe complications as well as the fear of overirradiation. Thus, according to a large U.S. database analysis, attempts at performing a CTO-PCI are decreasing (from 9.4% to 5.7% between 1997 and 2004) although much progress has been made with further advanced interventional techniques and sophisticated interventional tools [3].

In patients with chronically occluded coronary arteries who are symptomatic with angina pectoris and/or display exercise-related myocardial ischemia, coronary artery bypass grafting (CABG) is still considered the routine method of treatment [5-7]. This strategy has to be questioned because CTO intervention is a much less invasive and equally effective procedure with a significantly low rate of relevant major adverse cardiac events in hospital [8]. The success rates of CTO recanalization increased up to 90% in experienced hands in recent years. The time has therefore come to implement CTO in all coronary laboratories as an alternative to CABG.

This review will assess and describe the latest development in CTO recanalization strategies and try to outline new materials and methods.

Abbreviations

CABG	coronary artery bypass graft
CART	controlled antegrade and retrograde tracking
CTO	chronic total occlusion
IVUS	intravascular ultrasound
J-CTO	japanese CTO score
MACE	Major Adverse Cardiac Events
MI	myocardial infarction
MSCT	multislice computertomography
OTW	over-the-wire
PCI	percutaneous coronary intervention
TIMI	thrombolysis in myocardial infarction

Benefits

Relief of angina pectoris and ischemia-related dyspnea, substantial improvement in left ventricular function, and avoidance of major surgery, such as CABG, are the main benefits of CTO recanalization [9-11]. The Total Occlusion Angioplasty Study-Società Italiana di Cardiologia Invasiva (TOAST-GISE) trial proved that successful CTO-PCI was associated with 86% freedom from angina pectoris compared with 70% in the control group.

Regional wall motion and wall thickening of the myocardium improved significantly within 6 months of CTO-PCI (68% vs. 55%) [12]. Meanwhile, there is also evidence that complete CTO revascularization increases the survival of patients with at least one CTO significantly [13].

Multivessel coronary artery disease is associated with an increased risk of mortality in the control of acute myocardial infarction and the majority of this risk is attributable to the presence of a CTO [14]. Through several studies it has been possible to show that successful percutaneous revascularization of a CTO leads to a significantly improved survival rate and a reduction in major adverse cardiac and cerebrovascular events at 5 years compared with unsuccessful CTO-PCI; furthermore, prospective study registries have indicated a large impact of a successful intervention, compared with an unsuccessful intervention, of a CTO on total mortality [15,16].




Fig. 1. Parallel wire technique.

Nevertheless, it is quite important to mention that the benefit of CTO-PCI remains controversial because all data are based on registries. The need for randomized trials is enormous like the ongoing EURO-CTO study, which evaluates in a randomized multicenter trial the utilization of revascularization or optimal medical therapy for the treatment of CTO.

New techniques

A vast variety of new CTO-PCI techniques and a continuous improvement in the range and applicability of new materials have now increased the success rates of CTO up to around 90% and created a wide spectrum for extension of indications for CTO-PCI.

However, the basis is still the antegrade approach. Bilateral injections allow a simultaneous antegrade and retrograde filling of the target vessel in the case of intercoronary artery collaterals. A wire escalation strategy from intermediate to stiff guidewires supports a safe and feasible procedure [17].

The main strategies include the *see-saw wire* and the *parallel wire* technique, and the balloon anchoring and intravascular ultrasound (IVUS)-guided wiring. They are landmark improvements and established in routine use [18].

Parallel wire strategy and see-saw technique

If a wire enters the subintimal space, it should be left in position to act as a marker. A second wire is then inserted along this wire to find a new channel (Fig. 1). If the second wire enters the subintimal space, the first wire is pulled back and an attempt is made to advance this wire into the true lumen. This maneuver is known as the *see-saw wire* technique. A third wire can also be introduced to penetrate the CTO into the true lumen.

Anchor wire and anchor balloon techniques

To improve the back-up force of the guiding catheter, this technique can be necessary if the

wire and/or the microcatheter cannot pass the occlusion. In this technique, it is necessary to use a second, supporting wire in a side branch proximal to the occlusion to increase support from the guiding catheter.

IVUS-guided wiring

It is sometimes difficult to access the precise entry point of the CTO just using the angiogram. The IVUS-guided wiring technique can be used to identify the local anatomy and to adjust the exploring wire more precisely. IVUS guidance is also important in a variety of CTO interventions.

If the antegrade access fails, the retrograde approach is a useful alternative with high success rate and low significant complications [19]. Kato et al. [20] demonstrated that the use of septal or epicardial collaterals may increase success rates significantly without enhancing the risk of the procedure.

The tortuosity and the calcification of the lesion, the length of the occlusion, and information about the stump are important to create a useful recanalization strategy. This information is combined in the Japanese CTO score, which is used to characterize lesion complexity in a standardized way. Three main strategies have been established for the retrograde approach.

The true retrograde technique

In the true retrograde technique, the retrograde wire is advanced through septal or epicardial collaterals and the occlusion. The main objective is to

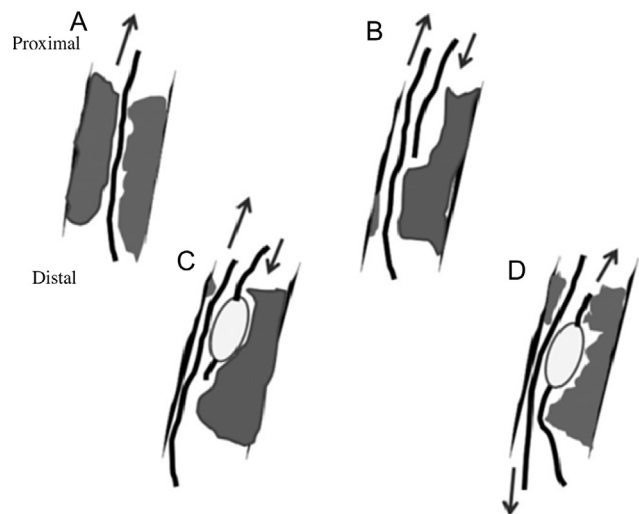


Fig. 2. Retrograde CTO crossing techniques: (A) retrograde wiring, (B) kissing wire technique, (C) reverse CART technique, and (D) CART technique [32]. CART = controlled antegrade and retrograde tracking; CTO = chronic total coronary occlusion.

Table 1. Overview of currently available CTO wires.

Wire	Manufacturer	Design	Coating	Tip load (g)	Penetration force (kg/in. ²)
Fielder XT	Asahi	Tapered tip 0.009 in.; shaft 0.014 in.	Hydrophilic, polymer jacket	0.8	N/A
Fielder XT-A	Asahi	Tapered tip 0.009 in.; shaft 0.014 in.	Hydrophilic, polymer jacket	1.0	N/A
Fielder XT-R	Asahi	Tapered tip 0.009 in.; shaft 0.014 in.	Hydrophilic, polymer jacket	0.6	N/A
Sion	Asahi	Nontapered tip 0.014 in.	Hydrophilic, nonjacketed over spring coil and tip	0.7	N/A
Sion Blue	Asahi	Nontapered tip 0.014 in.	Hydrophilic, nonjacketed over spring coil. Hydrophobic tip	0.5	N/A
Gaia First	Asahi	Tapered tip 0.010 in.; shaft 0.014 in.	Hydrophilic, nonjacketed. Tip hydrophilic	1.5	N/A
Gaia Second	Asahi	Tapered tip 0.011 in.; shaft 0.014 in.	Hydrophilic, nonjacketed. Tip hydrophilic	3.5	N/A
Gaia Third	Asahi	Tapered tip 0.011 in.; shaft 0.014 in.	Hydrophilic, nonjacketed. Tip hydrophilic	4.5	N/A
Miracle 3	Asahi	Nontapered tip 0.014 in.	Hydrophobic	3.0	20
Confianza Pro 12	Asahi	Tapered tip 0.009 in.; shaft 0.014 in.	Hydrophilic nonjacketed over spring coil. Hydrophobic tip and shaft	12.0	189
Progress 40	Abbott	Nontapered tip 0.014 in.	Hydrophilic, nonjacketed	4.8	30
Progress 120	Abbott	Nontapered tip 0.014 in.	Hydrophilic, nonjacketed	13.9	90
Progress 140T	Abbott	Tapered tip 0.0105 in.; shaft 0.014 in.	Hydrophilic, nonjacketed	12.5	144
Pilot 50	Abbott	Nontapered tip 0.014 in.	Hydrophilic, polymer jacket	1.5	N/A
Pilot 150	Abbott	Nontapered tip 0.014 in.	Hydrophilic, polymer jacketed	2.7	N/A

G. Touma et al.
CTO = chronic total coronary occlusion; N/A = not available.

cross retrograde into the proximal true lumen by taking possible advantage of more favorable characteristics of the distal cap. After crossing the lesion, the wire should be oriented into the antegrade guide so that it can be trapped there with balloon inflation. Externalization is the next step. The retrograde wire used to cross the occlusion is exchanged for a longer wire, like the RG3 wire (Asahi Intecc, Nagoya-shi, Aichi, Japan) and the R350 wire (Vascular Solutions, Minneapolis, MN, USA), with the objective of converting the recanalization procedure to an antegrade fashion [21,22].

If this maneuver is not possible, then the kissing wire strategy can be used (Fig. 2). In this method, the retrograde wire can serve as a landmark. The proximal cap is penetrated with one wire via the antegrade route and the distal cap with another wire via the retrograde guide. The wires meet in the middle of the occlusion, and the antegrade wire is then advanced along the path of the retrograde wire to complete lesion crossing.

The controlled antegrade and retrograde tracking and reverse controlled antegrade and retrograde tracking techniques

By creating a controlled subintimal dissection, the controlled antegrade and retrograde tracking (CART) and reverse CART techniques with or without a knuckle wire can be employed (Fig. 2). The basic concept of the CART technique is to create a subintimal dissection. A balloon is inflated in the retrograde-created subintimal space. The antegrade wire is then used to reenter the true lumen, often with IVUS guidance [23]. In reverse CART, a small balloon is inflated in the CTO over an antegrade guidewire to create a subintimal or intimal dissection, which then facilitates the retrograde guidewire to pass into the proximal true lumen [24].

What is known as a *hybrid* approach has been developed in North America over the past few years for antegrade and retrograde recanalization. The main goal of this algorithm is to create a comprehensive procedural strategy. First, dual coronary injection should be performed and then four angiographic parameters are assessed. This looks at the anatomy of the proximal cap using angiography or intravascular ultrasonography. The length of the CTO and the presence of branches, as well as the size and quality of the target vessel at the distal cap are also looked at. Furthermore, the suitability of collaterals for the retrograde techniques is assessed [25]. A minimal number of wire choices are available to simplify methodology, minimize costs, and allow adoption

of the technique in a variety of catheter laboratory environments. The main goals are procedural efficiency and minimizing the amount of radiation and contrast medium as well as a fast transition to alternative plans if failure occurs.

New materials and tools

New materials and tools contribute substantially to increasing success rates in CTO recanalization. Progress was made in particular with the use of atraumatic coronary wires supported by microcatheters and channel dilators.

- Microcatheters avoid a twisting of the wires in case of a parallel wire access and maintain a stable guidewire maneuverability. They facilitate a change of guidewires and can support the identification of intracoronary collaterals much easier. A variety of tapered and angled microcatheters are available and can be individually selected to navigate through the lesion even in case of a complex morphology and anatomy.
- Because of newly created hydrophilic wires with graduated tip stiffness, some of them with a high penetration power, the crossing of a CTO through microchannels has become more effective. A new generation of tapered guidewires such as the preshaped Gaia wire (Asahi Intecc) has also been introduced into clinical routine use. An overview of some available CTO wires is shown in [Table 1](#).
- An alternative is the use of the newly developed reentry CrossBoss/Stingray systems (Boston Scientific, Marlborough, MA, USA) [26]. These are special dissection/reentry devices that allow to safely deliver a guidewire via the true lumen or subintimal pathways. The CrossBoss, which is an over-the-wire catheter, creates a subintimal space until it is adjacent to a normal true lumen where reentry can occur. The Stingray device reenters the true lumen from a subintimal position.
- The GuideLiner mother-and-child catheter (Vascular solutions, USA) is an adjunctive device for difficult CTO-PCI, where despite standard measures it is not possible to deliver an initial balloon or microcatheter across the occluded segment. In case of an insufficient back up, support from the guiding catheter of this tool can help to expand the stent in the correct position [27].
- IVUS guidance has become increasingly important. It allows for more detailed insights into the anatomy of the lesion, the proximal cap, and the

side branches. It also provides the advantage of reducing the quantity of contrast medium used, thus preventing the risk of renal failure.

- In selected cases a multislice computer tomography can be helpful to give a better understanding of the plaque structure of the CTO and the anatomy of the occluded artery [28].

The development of new materials is on the rise steadily, such as new microcatheters with increased lower profile and increased flexibility like the LP turnpike microcatheter (Vascular Solutions) or the caravel microcatheter (Asahi Intecc), and new wires of the neo series, which are designed with one-piece core (Asahi Intecc).

Complications

A profound knowledge of complication management is essential before starting CTO recanalization. Death may occur in up to 1% of patients, and in-hospital myocardial infarction may occur in up to 5% of cases [29]. Other main complications include collateral rupture, coronary artery perforation, cardiac tamponade (up to 2%), vascular complications (up to 2%), radiation injury, and contrast-induced nephropathy [30,31]. Covered stents and a high level of operator experience in routine instant pericardial drainage are essential. The activated clotting time must be monitored closely.

Conclusions

Huge progresses in techniques and materials make CTO-PCI an essential option for any modern coronary catheter laboratory. It not only allows the reopening of a CTO but regular use also enhances the interventional standards of a catheter laboratory substantially in all complex interventions.

A deep understanding and extended use of CTO techniques and materials is a quantum leap in interventional cardiology and can be considered as the most modern current method.

Techniques and use of materials are not easy to learn. Acquiring the different techniques requires training from experienced interventionalists. Highly qualified cardiac centers offer this service in workshops and courses. Any invasive cardiac center should adopt CTO-PCI procedures as standard therapy.

References

- [1] Di Mario C, Werner GS, Sianos G, Galassi AR, Büttner J, Dudek D, et al. European perspective in the recanalisation

- of chronic total occlusions (CTO): consensus document from the EuroCTO Club. *EuroIntervention* 2007;3:30-43.
- [2] Werner GS, Gitt AK, Zeymer U, Juenger C, Towae F, Wienbergen H, et al. Chronic total coronary occlusions in patients with stable angina pectoris: impact on therapy and outcome in present day clinical practice. *Clin Res Cardiol* 2009;98:435-41.
 - [3] Abbott JD, Kip KE, Vlachos HA, Sawhney N, Srinivas VS, Jacobs AK, et al. Recent trends in the percutaneous treatment of chronic total coronary occlusions. *Am J Cardiol* 2006;97:1691-6.
 - [4] Werner GS. Therapie des chronischen Koronararterienverschlusses. *Herz* 2011;36:222-31 [Article in German].
 - [5] Delacrétaiz E, Meier B. Therapeutic strategy with total coronary artery occlusions. *Am J Cardiol* 1997;79:185-7.
 - [6] Bourassa MG, Roubin GS, Detre KM, Sopko G, Krone RJ, Attabuto MJ, et al. Bypass angioplasty revascularization investigation: patient screening, selection, and recruitment. *Am J Cardiol* 1995;75:3C-8C.
 - [7] Christofferson RD, Lehmann KG, Martin GV, Every N, Caldwell JH, Kapadia SR. Effect of chronic total coronary occlusion on treatment strategy. *Am J Cardiol* 2005;95:1088-91.
 - [8] Han YL, Wang SL, Jing QM, Li Y, Zhang J, Ma YY, et al. Percutaneous coronary intervention for chronic total occlusion in 1263 patients: a single-center report. *Chin Med J (Engl)* 2006;119:1165-70.
 - [9] Sirnes PA, Myreng Y, Mølsted P, Bonarjee V, Golf S. Improvement in left ventricular ejection fraction and wall motion after successful recanalization of chronic coronary occlusions. *Eur Heart J* 1998;19:273-81.
 - [10] Warren RJ, Black AJ, Valentine PA, Manolas EG, Hunt D. Coronary angioplasty for chronic total occlusion reduces the need for subsequent coronary bypass surgery. *Am Heart J* 1990;120:270-4.
 - [11] Kirschbaum SW, Baks T, van den Ent M, Sianos G, Krestin GP, Serruys P, et al. Evaluation of left ventricular function three years after percutaneous recanalization of chronic total coronary occlusions. *Am J Cardiol* 2008;101:179-85.
 - [12] Cheng AS, Selvanayagam JB, Jerosch-Herold M, van Gaal WJ, Karamitsos TD, Neubauer S, et al. Percutaneous treatment of chronic total coronary occlusions improves regional hyperemic myocardial blood flow and contractility: insights from quantitative cardiovascular magnetic resonance imaging. *JACC Cardiovasc Interv* 2008;1:44-53.
 - [13] Valenti R, Migliorini A, Signorini U, Vergara R, Parodi G, Carrabba N, et al. Impact of complete revascularization with percutaneous coronary intervention on survival in patients with at least one chronic total occlusion. *Eur Heart J* 2008;29:2336-42.
 - [14] van der Schaaf RJ, Vis MM, Sjaauw KD, Koch KT, Baan Jr J, Tijssen JG, et al. Impact of multivessel coronary disease on long-term mortality in patients with ST-elevation myocardial infarction is due to the presence of a chronic total occlusion. *Am J Cardiol* 2006;98:1165-9.
 - [15] Hoye A, van Domburg RT, Sonnenschein K, Serruys PW. Percutaneous coronary intervention for chronic total occlusions: the Thoraxcenter experience 1992-2002. *Eur Heart J* 2005;26:2630-6.
 - [16] Joyal D, Afilalo J, Rinfret S. Effectiveness of recanalization of chronic total occlusions: a systematic review and meta-analysis. *Am Heart J* 2010;160:179-87.
 - [17] Sumitsuji S, Inoue K, Ochiai M, Tsuchikane E, Ikeno F. Fundamental wire technique and current standard strategy of percutaneous intervention for chronic total occlusion with histopathological insights. *JACC Cardiovasc Interv* 2011;4:941-51.
 - [18] Ochiai M, Ashida K, Araki H, Ogata N, Okabayashi H, Obara C. The latest wire technique for chronic total occlusion. *Ital Heart J* 2005;6:489-93.
 - [19] Galassi AR, Sianos G, Werner GS, Escaned J, Tomasello SD, Boukhris M, et al. Retrograde recanalization of chronic total occlusions in Europe: procedural, in-hospital, and long-term outcomes from the multicenter ERCTO registry. *J Am Coll Cardiol* 2015;65:2388-400.
 - [20] Rathore S, Katoh O, Matsuo H, Terashima M, Tanaka N, Kinoshita Y, et al. Retrograde percutaneous recanalization of chronic total occlusion of the coronary arteries: procedural outcomes and predictors of success in contemporary practice. *Circ Cardiovasc Interv* 2009;2:124-32.
 - [21] Grantham JA, Marso SP, Spertus J, House J, Holmes Jr DR, Rutherford BD. Chronic total occlusion angioplasty in the United States. *JACC Cardiovasc Interv* 2009;2:479-86.
 - [22] Joyal D, Thompson CA, Grantham JA, Buller CE, Rinfret S. The retrograde technique for recanalization of chronic total occlusions: a step-by-step approach. *JACC Cardiovasc Interv* 2012;5:1-11.
 - [23] Dai J, Katoh O, Kyo E, Tsuji T, Watanabe S, Ohya H. Approach for chronic total occlusion with intravascular ultrasound-guided reverse controlled antegrade and retrograde tracking technique: single center experience. *J Interv Cardiol* 2013;26:434-43.
 - [24] Dai J, Katoh O, Zhou H, Kyo E. First reported revascularization of complex occlusion of the right coronary artery using the IVUS-guided reverse CART technique via a gastroepiploic artery graft. *Heart Vessels* 2016;31:251-5.
 - [25] Brilakis ES, Grantham JA, Rinfret S, Wyman RM, Burke MN, Karpaliotis D, et al. A percutaneous treatment algorithm for crossing coronary chronic total occlusions. *JACC Cardiovasc Interv* 2012;5:367-79.
 - [26] Werner GS. The BridgePoint devices to facilitate recanalization of chronic total coronary occlusions through controlled subintimal reentry. *Expert Rev Med Devices* 2011;8:23-9.
 - [27] Kovacic JC, Sharma AB, Roy S, Li JR, Narayan R, Kim DB, et al. GuideLiner mother-and-child guide catheter extension: a simple adjunctive tool in PCI for balloon uncrossable chronic total occlusions. *J Interv Cardiol* 2013;26:343-50.
 - [28] Muramatsu T. Current technical and clinical features of the antegrade and retrograde approaches to percutaneous transluminal coronary intervention for chronic total occlusion. *Egypt Heart J* 2013;66:1-10.
 - [29] Stone GW, Reifart NJ, Moussa I, Hoye A, Cox DA, Colombo A, et al. Percutaneous recanalization of chronically occluded coronary arteries: a consensus document: part II. *Circulation* 2005;112:2530-7.
 - [30] Morino Y, Abe M, Morimoto T, Kimura T, Hayashi Y, Muramatsu T, et al. Predicting successful guidewire crossing through chronic total occlusion of native coronary lesions within 30 minutes: the J-CTO (Multicenter CTO Registry in Japan) score as a difficulty grading and time assessment tool. *JACC Cardiovasc Interv* 2011;4:213-21.
 - [31] Favero L, Penzo C, Nikas D, Pacchioni A, Pasquetto G, Saccà S, et al. Cardiac and extracardiac complications during CTO interventions: prevention and management. *Interv Cardiol (Lond)* 2010;2:355-67.
 - [32] Muramatsu T, Tsukahara R, Ito Y, Ishimori H, Park SJ, de Winter R, et al. Changing strategies of the retrograde approach for chronic total occlusion during the past 7 years. *Catheter Cardiovasc Interv* 2013;81:E178-85.