

## Successful treatment of total occluded innominate artery in a patient with subclavian steal syndrome

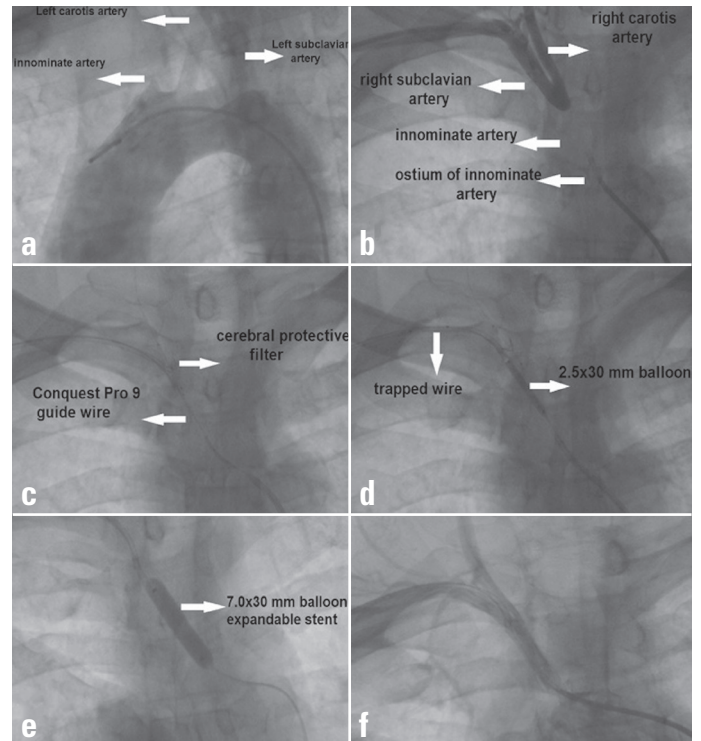
Taner Şeker, Hazar Harbaloğlu, Mustafa Gür, Murat Çaylı<sup>1</sup>  
 Department of Cardiology, Adana Numune Training and Research Hospital, Adana-Turkey  
<sup>1</sup>Department of Cardiology, Faculty of Medicine, Dicle University, Diyarbakır-Turkey

### Introduction

The innominate and subclavian arteries are the most common locations for stenotic lesions in the upper extremities (1). Innominate artery occlusive disease is often associated with cerebrovascular symptoms such as subclavian steal syndrome, arm claudication, distal embolization, and stroke. In some patients, subclavian steal syndrome can present with symptoms of arterial insufficiency afflicting the brain, typically manifesting as transient brain ischemia (2). Percutaneous interventions have evolved as an effective and safe treatment modality for occlusive lesions of the subclavian and innominate arteries (3). Current guidelines recommend the endovascular-first strategy in patients with atherosclerotic lesions of the upper extremities (1). Herein we report a case of successful percutaneous stent implantation to innominate artery in a symptomatic patient.

### Case Report

A 50-year-old man was admitted with complaints of repeated syncope episodes, dizziness when tilting his head back, and numbness in the right upper arm while working. His blood pressure in the left arm was 130/70 mm Hg and in the right arm was 85/50 mm Hg. Physical examination, laboratory tests, and electrocardiography showed no abnormality. Two-dimensional echocardiography revealed slight left ventricular hypertrophy. Brain computed tomography did not show any abnormal findings. Subclavian steal phenomenon was suspected, and it was confirmed using aortography (Fig. 1a, Video 1). A 6F sheath was placed in the right femoral artery, and a 6F JR4 guiding catheter was delivered to the ostium of the innominate artery. A 6F JR4 guiding catheter was placed into the proximal part of the subclavian artery via the right radial artery access. Dual injection showed total occlusion of the innominate artery (Fig. 1b, Video 2). We distally protected the common carotid artery because of the neighborhood of the occluded segment (Fig. 1c). We used 7.2-mm Emboshield NAV6 Embolic Protection System (Abbot vascular, United States). We initially choose antegrade approach. We tried cross occlusion using a 1.5x15 mm over-the-wire (OTW) balloon and Fielder XT through the 6F JR4 guiding catheter antegradely. Nevertheless, we could not pass the occluded segment using the Fielder XT



**Figure 1. (a) Aortography show total occlusion of the innominate artery. (b) Dual injection showed total occlusion of the innominate artery. (c) Placement of cerebral embolism protective filter and passing through the lesion using Conquest Pro 9.0. (d) Dilatation using a bigger balloons after the wire was trapped in the catheter that was placed via the right radial artery access. (e) Excellent final result. (f) A 7.0x30 mm balloon expandable stent implantation**

guidewire and replaced the Fielder XT guidewire with Conquest Pro 9.0. After this, the Conquest Pro 9.0 guidewire passed through the totally occluded segment (Fig. 1c). We pushed the guidewire into the catheter, which was placed via the right radial artery access, and trapped it using a 2.0x15 mm balloon. Then we succeeded to cross the OTW balloon (Fig. 1d, Video 3). We measured the lesion length using quantitative coronary angiography. Then we placed a 7.0x30 mm balloon expandable stent (Fig. 1e). Final angiography with antegrade contrast injections showed an excellent result (Fig. 1f, Video 4). There were no complications during or after the procedure.

### Discussion

Percutaneous intervention with or without the placement of a stent and surgical approaches are treatment modalities for subclavian steal syndrome (3). The results of the largest series suggested stenting as the treatment of choice in selected patients (4). In addition, Chatterjee et al. (5) showed that stenting is significantly superior to angioplasty alone. We chose endovascular stenting approach for this patient. Although endovascular stenting of innominate artery stenosis is a well-established mode of

treatment, total occlusion of the subclavian or innominate artery poses a special challenge and is technically demanding (6). Vascular access, inability to visualize the distal vessel, and achieving cerebral protection are the main obstacles for endovascular stenting of an occluded innominate artery. Dual injection technique is routinely performed to evaluate the length of the lesion and decide whether an antegrade or a retrograde approach is required (7). In this case, we initially choose antegrade approach because there was a significant narrowing in the proximal part. Although endovascular stenting is first-line treatment for subclavian stenosis, it can cause intraluminal hyperplasia, and the restenosis rates are higher than for extra-thoracic surgical revascularization (8). Surgical revascularization can be chosen when endovascular techniques fail.

## Conclusion

Primary stenting of the subclavian and innominate arteries occlusive lesions with percutaneous techniques should be considered as the first choice of treatment by experienced surgeons and centers because of the high clinical success and low complication rates.

## References

1. Brogneaux C, Sprynger M, Magnée M, Lancellotti P; European Society for Cardiology. 2011 ESC guidelines on the diagnosis and treatment of peripheral artery diseases. *Rev Med Liege* 2012; 67: 560-5.
2. Marc M, Iancu A, Molnar A, Bindea D. Coronary subclavian steal: Case series and review of the literature. *Clujul Med* 2015; 88: 79-82.
3. Salman R, Hornsby J, Wright LJ, Elsaid T, Timmons G, Mudawi A, et al. Treatment of subclavian artery stenosis: A case series. *Int J Surg Case Rep* 2015; 19: 69-74.
4. van de Weijer MA, Vonken EJ, de Vries JP, Moll FL, Vos JA, de Borst GJ. Technical and clinical success and long-term durability of endovascular treatment for atherosclerotic aortic arch branch origin obstruction: evaluation of 144 Procedures. *Eur J Vasc Endovasc Surg* 2015; 50: 13-20.
5. Chatterjee S, Nerella N, Chakravarty S, Shani J. Angioplasty alone versus angioplasty and stenting for subclavian artery stenosis—a systematic review and meta-analysis. *Am J Ther* 2013; 20: 520-3.
6. Kang WC, Han SH, Ahn TH, Shin EK. Percutaneous transluminal angioplasty and stent implantation for coronary subclavian steal syndrome: Unusual approach. *Int J Cardiol* 2005; 101: 335-7.
7. Martinez R, Rodriguez-Lopez J, Torruella L, Ray L, Lopez-Galarza L, Diethrich EB. Stenting for occlusion of the subclavian arteries. Technical aspects and follow-up results. *Tex Heart Inst J* 1997; 24: 23-7.
8. AbuRahma AF, Bates MC, Stone PA, Dyer B, Armistead L, Scott Dean L, et al. Angioplasty and stenting versus carotid-subclavian bypass for the treatment of isolated subclavian artery disease, *J Endovasc Ther* 2007; 14: 698-704.

**Video 1.** Aortography show total occlusion of the innominate artery.

**Video 2.** Dual injection showed total occlusion of the innominate artery.

**Video 3.** Placement of cerebral embolism protective filter and passing through the lesion using Conquest Pro 9.0 and balloon with the trapped wire in the distal catheter.

**Video 4.** Excellent final result.

**Address for Correspondence:** Dr. Taner Şeker  
Adana Numune Eğitim ve Araştırma Hastanesi  
Kardiyoloji Bölümü, Adana- Türkiye  
E-mail: atanerseker@hotmail.com

©Copyright 2016 by Turkish Society of Cardiology - Available online at [www.anatoljcardiol.com](http://www.anatoljcardiol.com)  
DOI:10.14744/AnatolJCardiol.2016.7008

