

## A Deadly Connection: Aortoenteric Fistula as a Cause of Acute Upper Gastrointestinal Bleeding

Shifat Ahmed, MD<sup>1</sup>, Chirag Patel, MD<sup>1</sup>, Christopher Schmitt, MD<sup>1</sup>, and Dipendra Parajuli, MD<sup>2</sup>

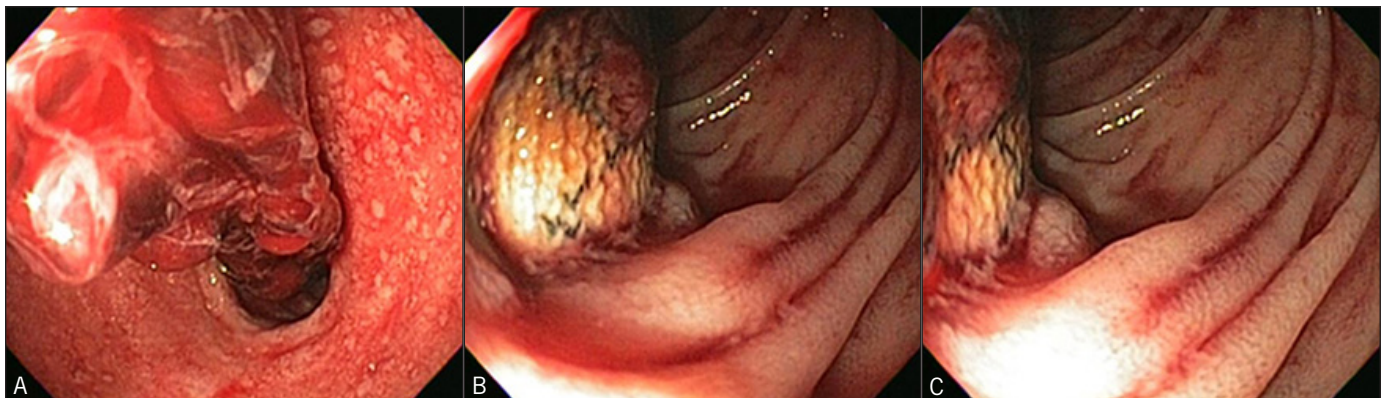
<sup>1</sup>Department of Internal Medicine, University of Louisville, Louisville, KY

<sup>2</sup>Department of Gastroenterology and Hepatology, University of Louisville, Louisville, KY

### Case Report

A 66-year-old white man with hypertension, hyperlipidemia, COPD, lung cancer, and aortoiliac bypass graft placed 6 years prior for peripheral vascular disease, presented with 3 days of melena and syncopal events associated with bowel movements. The patient reported having coffee ground emesis and dark, tarry stools with onset of his syncope. Physical exam showed bright red blood per rectum and melanic stools. Baseline hemoglobin was 14.5 g/dL, dropping to 7.1 g/dL at admission. He subsequently became hypotensive despite receiving 2 units of packed red blood cells and aggressive intravenous fluid hydration. Emergent esophagogastroduodenoscopy (EGD) showed red blood throughout the esophagus, pale stomach mucosae, and an exposed aortic graft with bright blood in the third part of the duodenum (Figure 1). He underwent emergent laparotomy for takedown of aortoduodenal fistula with repair of duodenal erosion and ligation of the distal aorta. The following day, the patient's lower extremities had increased pallor and he underwent axillofemoral and femoral-femoral bypass grafting. He went into cardiac arrest perioperatively and died.

Aortoenteric fistulae are a rare cause of upper gastrointestinal bleeding. Two types of fistulae have been described.<sup>1,2</sup> Type I graft enteric fistulae account for 75% of all aortoenteric fistulae, occurring with or without pseudoaneurysms, and typically form between bowel and the proximal aspect of the aortic suture line. Gastrointestinal bleeding occurs in 84% of patients, with melena, herald bleeding, hematochezia, and bright red blood per rectum occurring in 41%, 37%, 9%, and 7%, respectively. Signs of sepsis occur 35% of the time, with fever being the most common symptom (92%). Type II fistulae are erosions that present with sepsis (89% of patients), bleeding (55%), and abdominal pain (36%). Bleeding manifests as melena (81%) and, rarely, hematochezia (6%), or hematemesis (0%). Type II fistulae account for 15-20% of aortoenteric communications and are a result of mechanical pulsatility of the aortic graft with bleeding around the edge of eroded bowel. Conventional open surgical repair risks significant perioperative complications (i.e., bowel obstruction, mediastinal abscess,



**Figure 1.** (A) Blood clot in the duodenal bulb and (B and C) aortic graft eroding into duodenum. Note the change in size of the fistula between panels B and C due to pulsatile blood flow.

ACG Case Rep J 2016;3(3):152-153. doi:10.14309/crj.2016.32. Published online: April 15, 2016.

**Correspondence:** Shifat Ahmed, University of Louisville, 550 S Jackson St., Third floor, Internal Medicine Office, Louisville, KY, 40202 (s0ahme04@louisville.edu).



**Copyright:** © 2016 Ahmed et al. This work is licensed under a Creative Commons Attribution-NonCommercial-NoDerivatives 4.0 International License. To view a copy of this license, visit <http://creativecommons.org/licenses/by-nc-nd/4.0>.

and acute renal failure).<sup>3</sup> Patients undergoing endovascular procedures such as stenting tend to have persistent sepsis and infection-related complications (i.e., abscess and endocarditis). Endovascular stent-graft placement allows hemodynamic optimization as a result of blood loss and sepsis.<sup>4</sup> Overall, open repair patients have longer survival, but tend to have increased hospital stays when compared to their endovascular counterparts.<sup>3</sup>

## Disclosures

Author contributions: All authors wrote and edited the manuscript. S. Ahmed is the article guarantor.

Financial disclosure: None to report.

Informed consent was obtained for this case report.

Received December 3, 2015; Accepted December 9, 2015

## References

1. Dachas RJ, Berman J. Aortoenteric fistula. *Am Fam Physician*. 1992;45(6):2610–2616.
2. Chang MW, Chan YL, Hsieh HC, Chang SS. Secondary aortoduodenal fistula. *Chang Gung Med J*. 2002; 25(9):626–30.
3. Xiromeritis K, Dalainas I, Stamatakis M, Filis K. Aortoenteric fistulae: Present-day management. *Int Surg*. 2011;96(3):266–73.
4. Williams CA, Zatina MA. Endovascular stent graft deployment as the initial intervention for a bleeding aortoenteric fistula. *Am Surg*. 2014;80(7):e207–9.

## Publish your work in ACG Case Reports Journal

ACG Case Reports Journal is a peer-reviewed, open-access publication that provides GI fellows, private practice clinicians, and other members of the health care team an opportunity to share interesting case reports with their peers and with leaders in the field. Visit <http://acgcasereports.gi.org> for submission guidelines. Submit your manuscript online at <http://mc.manuscriptcentral.com/acgcr>.