



Case Report

# Contrast-induced neurotoxicity presented as transient cortical blindness after stent-assisted coiling of a medium-sized unruptured basilar artery aneurysm: A case report and review of the literature

Toma Spiriev<sup>1</sup>, Lili Laleva<sup>1</sup>, Nurfet Alioski<sup>1</sup>, Raicho Dobrikov<sup>2</sup>, Valeri Gelev<sup>3</sup>, Milko Milev<sup>1</sup>, Vladimir Nakov<sup>1</sup>

Departments of <sup>1</sup>Neurosurgery, <sup>2</sup>Imaging Diagnostics and <sup>3</sup>Cardiology, Acibadem CityClinic University Hospital Tokuda, Sofia, Bulgaria.

E-mail: \*Toma Spiriev - spiriev@gmail.com; Lili Laleva - lililaleva@gmail.com; Nurfet Alioski - nalioski@gmail.com; Raicho Dobrikov - rdobrikov@abv.bg; Valeri Gelev - vgelev@abv.bg; Milko Milev - milko.d.milev@gmail.com; Vladimir Nakov - vladimir\_nakov@yahoo.com



\*Corresponding author:

Toma Spiriev,  
Department of Neurosurgery,  
Acibadem City Clinic  
University Hospital Tokuda,  
Sofia, Bulgaria.

spiriev@gmail.com

Received : 16 November 2021

Accepted : 20 January 2022

Published : 11 February 2022

DOI

10.25259/SNI\_1143\_2021

Quick Response Code:



## ABSTRACT

**Background:** Contrast-induced neurotoxicity is a rare event after endovascular diagnostic procedures or interventions and presents as transient neurological deficit. Herewith, we present a case of reversible complete cortical blindness after uneventful stent-assisted coiling of a medium-sized unruptured basilar artery aneurysm.

**Case Description:** A 70-year-old woman with a medium-sized 10 mm/6 mm wide neck basilar tip aneurysm was planned for endovascular obliteration of the lesion. The procedure was done under general anesthesia. The contrast agent was iso-osmolar, nonionic. The aneurysm was coiled, and a stent was placed in the left posterior cerebral artery achieving sufficient aneurysm packing. No signs of vessel obliteration were observed during the procedure. On awakening of anesthesia, the patient reported complete visual loss. Ophthalmological examination was normal. The patient was brought back to the angio-suite but there were no signs of parent vessel compromise from the endovascular implants or distal vessel occlusion. An MRI of the brain was done showing no signs of brain ischemia, just mild brain edema in both occipital lobes. Given the results of the radiological studies and clinical presentation, the diagnosis of contrast-induced neurotoxicity was accepted. In 72 h, the patient had complete resolution of the visual loss and was discharged home with no additional neurological worsening.

**Conclusion:** Contrast-induced neurotoxicity is a rare event that can occur after uneventful endovascular interventions of the brain vessels. Knowledge of this rare complication, after exclusion of all other possible reversible causes, is important for the treatment and prognosis of the patient.

**Keywords:** Aneurysm, Contrast-induced neurotoxicity, Endovascular coiling, Endovascular stenting, Reversible neurological deficit

## INTRODUCTION

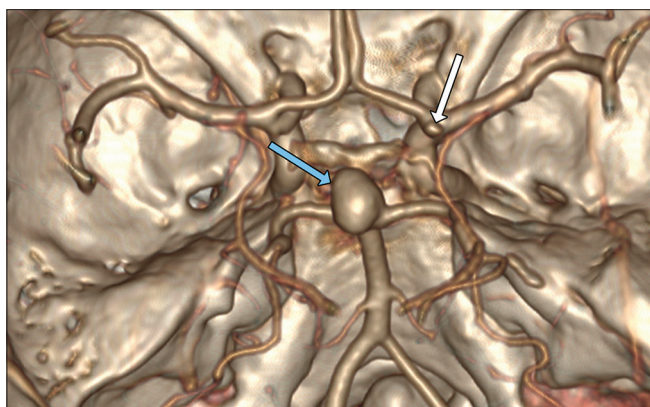
In recent years, the endovascular obliteration of intracranial aneurysms and vascular malformations has greatly advanced the management of cerebrovascular lesions as less invasive alternative to surgery.<sup>[1,2,5,7,12-14,19]</sup> Although minimally invasive, endovascular neurosurgery might have complication rates in the treatment of unruptured brain aneurysms ranging from 4.8% to 11%,<sup>[6,13,14]</sup> depending on size, morphology, and location of the aneurysm, patient

characteristics (age and comorbidity), and complexity of the technique used for obliteration of the aneurysm (balloon-assisted coiling, stent-assisted coiling, and flow diverter device implantation).<sup>[6,13,14]</sup> One rare type of complication is transient cortical blindness and other less frequent neurological deficits associated with neurotoxicity of the contrast agent.<sup>[9,10,15-18,20]</sup> Herewith, we describe such case, we present our management strategy and diagnostic workup, as well as give a short literature review of the possible mechanisms behind the pathophysiology of the event.

## CASE DESCRIPTION

A 70-year-old woman, diagnosed with unruptured medium-sized, 10 mm/6 mm, wide neck (7 mm diameter) basilar tip aneurysm was admitted in our department [Figure 1]. On the radiological examinations another small aneurysm on the right internal carotid artery-A1 bifurcation was diagnosed [Figure 1]. The patient had recent increased incidence of headaches, arterial hypertension reaching 180/100 mmHg. On calculation of the PHASES<sup>®</sup> score, a 17.8% cumulative risk of rupture of the aneurysm was projected for a 5-year period. Therefore, given the clinical characteristics, the age of the patient, and the location of the aneurysm in the posterior circulation, the patient was elected for endovascular obliteration of the lesion instead of microsurgical clipping. As the aneurysm was medium sized with wide neck, the patient was prepared for stent-assisted coiling with dual antiplatelet therapy with prasugrel 10 mg once in the morning and acetylsalicylic acid 100 mg in the evening for 5 days before the procedure.

The endovascular obliteration was performed under general anesthesia. The contrast agent was iso-osmolar, nonionic, water soluble. Bilateral femoral artery access was attained with 6F vascular access device on the right side and 5F vascular

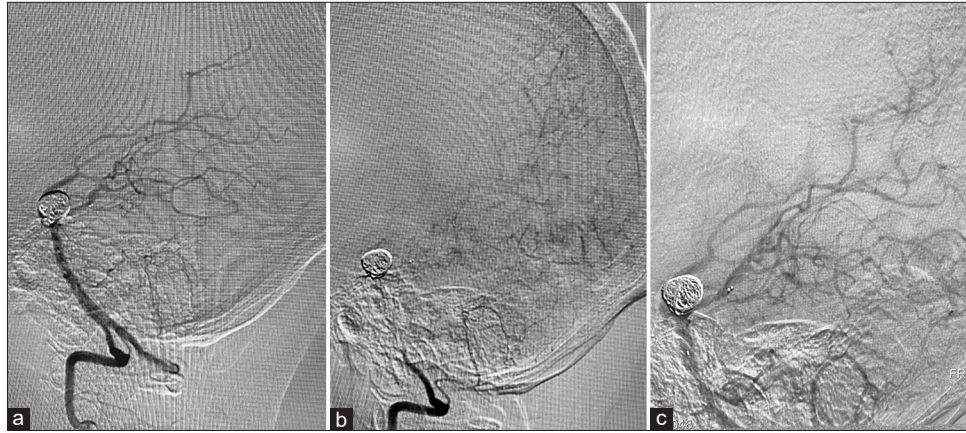


**Figure 1:** Preoperative CT angiography presenting the aneurysm of the basilar artery (blue arrow) as well as the aneurysm of the right internal carotid artery-A1 bifurcation (white arrow).

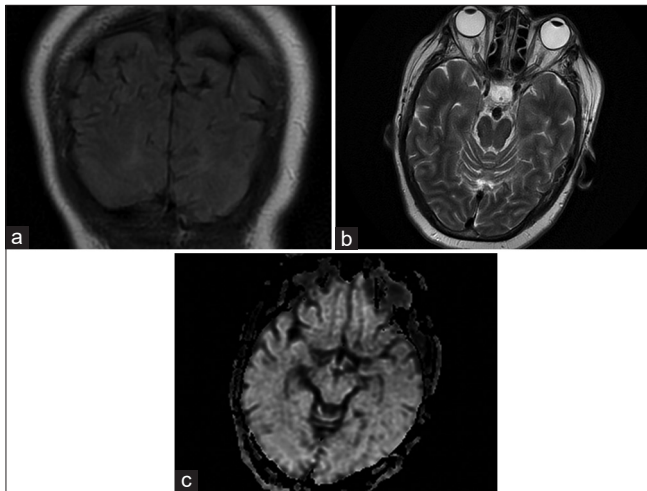
access device on the left side. A 6F Envoy DA (Codman Neuro<sup>®</sup>) catheter was introduced in the right vertebral artery and 5F Envoy (Codman Neuro<sup>®</sup>) catheter was introduced in the left vertebral artery. Using microwire Asahi Chikai<sup>®</sup> and microcatheter Phenom 27 (Medtronic<sup>®</sup>), the left posterior cerebral artery (PCA) was catheterized in the preparation of placement of Solitaire (Medtronic<sup>®</sup>). Another microcatheter Echelon 10 (Medtronic<sup>®</sup>) was jailed in the fundus of the aneurysm as the Solitaire AB 3 mm/20 mm (Medtronic<sup>®</sup>) was deployed. The aneurysm was filled with Axium framing coil 12 mm/30 cm (Medtronic<sup>®</sup>) followed by 7 mm/30 cm and 6 mm/20 cm helical coils achieving sufficient aneurysmal packing. No signs of vasospasm were observed during the procedure [Figures 2a and b]. A total of 200 ml contrast medium were administered for a period of 2½ h. The patient was extubated uneventfully. Shortly after the intervention, the patient reported completed visual loss. Ophthalmological examination was normal with no signs of optic nerve edema. As we suspected endovascular device problem or parent vessel compromise, the patient was brought back to the angiographic suite. On the posterior circulation angiography, there were no signs of parent vessel compromise from the endovascular implants. The distal branches of both posterior cerebral arteries were presented in normal fashion without any signs of thrombosis or vasospasm [Figure 2c]. Despite the lack of pathological findings, 2 mg of papaverine was injected intra arterially. A magnetic resonance imaging (MRI) of the brain followed the catheter angiography not showing any signs of brain ischemia [Figure 3]. The only abnormal findings were just mild brain edema in both occipital lobes [Figure 3]. Abdominal computed tomography (CT) scan showed no signs of retroperitoneal hematoma. Given the results of the radiological studies and the clinical data, the diagnosis of contrast-induced neurotoxicity was suggested. The patient continued to receive dual antiplatelet therapy as well as anticoagulation treatment with 9500 anti-Xa IU/ml 0.6 ml nadroparine calcium b.i.d.; intravenous saline hydration and anti-edematous treatment – dexamethasone in tapering dosage, were administered. In the evening of the 2<sup>nd</sup> day after the intervention the patient reported some visual improvement distinguishing only light. Forty-eight hours after the intervention the patient was able to perceive colors and silhouettes, and, at 72 h, the patient had fully restored visual functions. Several days later she was discharged at home with no additional neurological worsening.

## DISCUSSION

Endovascular neurosurgery, as minimally invasive alternative to microsurgical clipping, is a good option for the treatment of aneurysms in the posterior circulation taking in mind the depth of the vascular lesion and proximity of critical brainstem structures, vessels, and cranial nerves.<sup>[2,5,7,19]</sup> With



**Figure 2:** (a) Intraoperative angiography showing exclusion of the aneurysm from the circulation with coils and stent placement in the right PCA. No vessel compromise is seen, (b) capillary phase of the angiography presenting filling of the small vessels within the occipital lobe, (c) second vertebral angiography after the patient was brought back to the angiography suite presenting good filling of the distal branches of the PCA with no vessel compromise or implant failure.



**Figure 3:** (a) MRI FLAIR images presenting only mild brain edema in the occipital lobes, (b) MRI T2 images presenting no significant changes, (c) diffusion-weighted images presenting no ischemic changes.

the use of endovascular techniques, the added morbidity associated with brain retraction, potential cranial nerve injury, perforator, and parent vessel compromise that could potentially happen during surgery are obviated. Therefore, given the age of our patient, the associated comorbidity, and location of the lesion, the endovascular management was the better alternative for the treatment of this particular aneurysm.

However, endovascular interventions are not without risks and there are various intracranial complications that could also happen throughout the endovascular intervention. These complications include most frequently vasospasm, vessel dissection, parent vessel occlusion, distal emboli, and intravascular device compromise.<sup>[6,13,14]</sup> This is the reason

why we brought the patient back to the angiographic suite to manage possibly reversible complications. Only after we excluded the above-mentioned problems, we were led to the diagnosis of contrast-induced encephalopathy. This is a rare complication estimated to occur between 0.3% and 1% of patients undergoing brain angiography.<sup>[9,10,15-18,20]</sup> The definition of contrast-induced encephalopathy and transient cortical blindness is partial or complete visual loss with normal oculomotor reflexes, preserved extraocular movements, and normal pupillary reflexes.<sup>[16]</sup> The symptoms can be observed as early as 10 min after the intervention and can last as long as 5 days.<sup>[16]</sup> In general, most patients return their normal function within 24 h after the procedure.<sup>[15-18]</sup>

As the condition is very rare, there are not so many studies regarding the risk factors that can precede its occurrence. According to the literature, we suggest grouping the risk factors in three categories: (1) type of endovascular intervention; (2) type of contrast media used during the procedure; and (3) patient-related factors.

Studies suggest that the highest risk for contrast-induced encephalopathy is reported after vertebral angiography, posterior brain circulations studies, and endovascular interventions in this vascular territory.<sup>[9,10,15-18,20]</sup> However, the condition is also encountered during routine coronary angiography. In our institution we reviewed 9474 percutaneous coronary procedures (6148 diagnostic and 3326 interventions) and such transient neurological deficit was observed in only 16 patients (0.0017%), 75% of whom were male. All neurological symptoms were transient and resolved within 48 h after the intervention.<sup>[3]</sup> Other authors have described this complication after brachial angiography, aortography, myelography, and even after intravenous contrast CT in the presence of occipital metastatic lesions.<sup>[15,18]</sup>



The type of contrast agent used during the endovascular procedure is another risk factor. This kind of complication is reported to occur after administration of ionic and nonionic types of contrast agents and might be associated with penetration of the contrast media through transient disruption of the blood–brain barrier (BBB) related to dose, length of the procedure, and type of the contrast and is predominantly observed in the occipital lobes.<sup>[15,16,18]</sup> The condition was more frequent in the previous decades when high-osmolality contrast material solution (709 mosm/kg) was used for brain angiography. In our case, we used 200 ml iso-osmolar (290 mosm/kg), nonionic, water-soluble contrast medium (blood osmolality is 300 mosm/kg) for a period of 2½ h which was the total length of the procedure.

There are few evidences in the literature for the patient-related risk factors behind this condition. A recent study of Chu *et al.* examining 421 patients with acute ischemic stroke treated with endovascular thrombectomy report 1.7% (seven patients) who develop transient contrast-induced encephalopathy.<sup>[4]</sup> The authors identify that a history of previous stroke and impaired renal function are potentially associated with a higher risk of contrast-induced encephalopathy. In difference to other studies, the patients who experience contrast induced neurotoxicity are less likely to achieve favorable functional outcomes. However, this can be related to the specific patient population in this study, because according to authors, previous or acute stroke could disrupt the BBB in the same or adjacent vascular territory and facilitates leakage of the contrast medium.<sup>[4]</sup> Other authors also report that impaired renal function, arterial hypertension, as well as variability in procedural blood pressure (high range above and below patient's baseline) could be a risk factor for contrast-induced neurotoxicity.<sup>[11,21]</sup> It is known that high blood pressure can disrupt the blood–brain barrier and impaired renal function reduces the clearance of contrast medium.<sup>[4,11,21]</sup>

Several studies regarding the radiological findings observed with this condition describe hyperattenuated lesions in the occipital and posterior parietal cortices visible on CT scan which corresponds to accumulation of contrast media following disruption of the BBB.<sup>[10,17,18]</sup> These findings disappear within 24–48 h on repeated CT scan.<sup>[16]</sup> Another paper by Zevallos *et al.*, studying the clinical and radiological presentation of contrast-induced neurotoxicity after endovascular procedures, report that 82% of patients showed ipsilateral to the intervention brain edema and only two cases had contrast enhancement.

The MRI findings include abnormal cortical T2 and FLAIR hyperintensities in the occipital and parietal cortices, mild brain edema, with the absence of restricted fluid motion on the diffusion-weighted images (DWI), which excludes the ischemic source of the clinical presentation of the disease. In

our case we have not done a CT, but an MRI showed bilateral occipital lobe edema only with mild FLAIR changes and no abnormality on the DWI.

In the differential diagnosis with ischemia, which has distinctive MRI features and can be excluded, some studies suggest that contrast-induced neurotoxicity is similar to a syndrome known as posterior reversible leukoencephalopathy with similar MRI characteristics (reversible edema, localized mainly to the occipital lobes). This condition is often related to transplant immunosuppressive treatment, renal insufficiency, and hypertension and is presented with occipital edematous lesions on MRI, which often resolves on control of blood pressure or reduction of immunosuppressive drugs.<sup>[16]</sup> Studies suggest that the strength of the BBB is not equally distributed within the brain and it is most vulnerable in the occipital cortex.<sup>[18]</sup> This might explain why the visual cortex is frequently affected in contrast-induced neurotoxicity and posterior reversible leukoencephalopathy.<sup>[16,18]</sup>

The condition, if all other causes are excluded as in our case, usually requires no special pharmacological treatment and is reversible shortly after the procedure. However, some authors suggest the use of dexamethasone in tapering doses to stabilize the BBB, hydration, or even mannitol to draw contrast media osmotically out of the occipital cortex.<sup>[10,18]</sup> In our case we used hydration and dexamethasone in tapering doses, but no mannitol because the occipital lobe edema was not that extensive and there were no signs of contrast extravasation. Other authors have suggested the addition of heparin infusion to the treatment. We also preferred the use of low-molecular-weight heparin because of the ease of application (one or two dosages daily), lack of necessity for frequent measurement of international normalized ratio and activated partial thromboplastin time.<sup>[15]</sup> However, as the condition is rare, no specific therapy is proven to be effective for faster return to baseline of the neurological functions of the patients.<sup>[15-18,20]</sup>

## CONCLUSION

Contrast-induced neurotoxicity is a rare event that can occur after uneventful endovascular interventions of the brain vessels. The condition has benign course, with reversible neurological symptoms. However, patient associated conditions such as impaired renal function, history of previous stroke, intraparenchymal brain lesions, hypertension, as well as interventions in posterior circulation are potential risk factors for the occurrence of contrast-induced neurotoxicity. Although treatment is suggested, there is no evidence for specific therapeutic management. Knowledge of this rare condition, after exclusion of all other possible reversible causes, is important for the prognosis and reassurance of the patient for the temporary nature of the neurological worsening.

**Declaration of patient consent**

Patient's consent not required as patients identity is not disclosed or compromised.

**Financial support and sponsorship**

Nil.

**Conflicts of interest**

There are no conflicts of interest.

**REFERENCES**

- Bakker NA, Metzemaekers JD, Groen RJ, Mooij JJ, van Dijk JM. International subarachnoid aneurysm trial 2009: Endovascular coiling of ruptured intracranial aneurysms has no significant advantage over neurosurgical clipping. *Neurosurgery* 2010;66:961-2.
- Bekelis K, Gottlieb DJ, Su Y, O'Malley AJ, Labropoulos N, Goodney P, *et al.* Comparison of clipping and coiling in elderly patients with unruptured cerebral aneurysms. *J Neurosurg* 2017;126:811-8.
- Chilingirov N, Zheleva-Kyuchukova I, Stoyanov I, Staykov I, Peneva M, Kirova-Nedyalkova G, *et al.* Contrast-induced encephalopathy as a rare complication of percutaneous coronary procedures. *Med Rev* 2021;57:39-43.
- Chu YT, Lee KP, Chen CH, Sung PS, Lin YH, Lee CW, *et al.* Contrast-induced encephalopathy after endovascular thrombectomy for acute ischemic stroke. *Stroke* 2020;51:3756-9.
- Darsaut TE, Findlay JM, Magro E, Kotowski M, Roy D, Weill A, *et al.* Surgical clipping or endovascular coiling for unruptured intracranial aneurysms: A pragmatic randomised trial. *J Neurol Neurosurg Psychiatry* 2017;88:663-8.
- Etminan N, Rinkel GJ. Unruptured intracranial aneurysms: Development, rupture and preventive management. *Nat Rev Neurol* 2016;12:699-713.
- Gmeiner M, Gruber A. Current strategies in the treatment of intracranial large and giant aneurysms. *Acta Neurochir Suppl* 2021;132:19-26.
- Greving JP, Wermer MJ, Brown RD Jr., Morita A, Juvela S, Yonekura M, *et al.* Development of the PHASES score for prediction of risk of rupture of intracranial aneurysms: A pooled analysis of six prospective cohort studies. *Lancet Neurol* 2014;13:59-66.
- Horwitz NH, Wener L. Temporary cortical blindness following angiography. *J Neurosurg* 1974;40:583-6.
- Lantos G. Cortical blindness due to osmotic disruption of the blood-brain barrier by angiographic contrast material. CT and MRI studies. *Neurology* 1989;39:567-7.
- Matsubara N, Izumi T, Miyachi S, Ota K, Wakabayashi T. Contrast-induced encephalopathy following embolization of intracranial aneurysms in hemodialysis patients. *Neurol Med Chir (Tokyo)* 2017;57:641-8.
- Molyneux AJ, Kerr RS, Yu LM, Clarke M, Sneade M, Yarnold JA, *et al.* International subarachnoid aneurysm trial (ISAT) of neurosurgical clipping versus endovascular coiling in 2143 patients with ruptured intracranial aneurysms: A randomised comparison of effects on survival, dependency, seizures, rebleeding, subgroups, and aneurysm occlusion. *Lancet* 2005;366:809-17.
- Naggara ON, Lecler A, Oppenheim C, Meder JF, Raymond J. Endovascular treatment of intracranial unruptured aneurysms: A systematic review of the literature on safety with emphasis on subgroup analyses. *Radiology* 2012;263:828-35.
- Naggara ON, White PM, Guilbert F, Roy D, Weill A, Raymond J. Endovascular treatment of intracranial unruptured aneurysms: Systematic review and meta-analysis of the literature on safety and efficacy. *Radiology* 2010;256:887-97.
- Niimi Y, Kupersmith MJ, Ahmad S, Song J, Berenstein A. Cortical blindness, transient and otherwise, associated with detachable coil embolization of intracranial aneurysms. *Am J Neuroradiol* 2008;29:603-7.
- Saigal G, Bhatia R, Bhatia S, Wakhloo AK. MR findings of cortical blindness following cerebral angiography: Is this entity related to posterior reversible leukoencephalopathy? *Am J Neuroradiol* 2004;25:252-6.
- Schulte-Altendorneburg G, Rüb K, Scheglmann K. Simultaneous ischemic and neurotoxic brain damage after coronary angiography. *Neurol Res* 2004;26:79-82.
- Shinoda J, Ajimi Y, Yamada M, Onozuka S. Cortical blindness during coil embolization of an unruptured intracranial aneurysm-case report. *Neurol Med Chir (Tokyo)* 2004;44:416-9.
- Sughrue ME, Saloner D, Rayz VL, Lawton MT. Giant intracranial aneurysms: Evolution of management in a contemporary surgical series. *Neurosurgery* 2011;69:1261-70; discussion 1270-1.
- Utz R, Ekholm SE, Isaac L, Sands M, Fonte D. Local blood-brain barrier penetration following systemic contrast medium administration. A case report and an experimental study. *Acta Radiol* 1988;29:237-42.
- Zevallos CB, Dandapat S, Ansari S, Farooqui M, Quispe-Orozco D, Mendez-Ruiz A, *et al.* Clinical and imaging features of contrast-induced neurotoxicity after neurointerventional surgery. *World Neurosurg* 2020;142:e316-24.

**How to cite this article:** Spiriev T, Laleva L, Alioski N, Dobrikov R, Gelev V, Milev M, *et al.* Contrast-induced neurotoxicity presented as transient cortical blindness after stent-assisted coiling of a medium-sized unruptured basilar artery aneurysm: A case report and review of the literature. *Surg Neurol Int* 2022;13:48.