

Single Case – General Neurology

A Pyramidal Cause of a Cerebellar Ataxia: HSP-7

Tjerk Joppe Lagrand^a Gerard Hageman^b

^aDepartment of Neurology, University Medical Centre Groningen, Groningen, The Netherlands; ^bDepartment of Neurology, Medical Spectrum Twente, Enschede, The Netherlands

Keywords

Hereditary spastic paraparesis · SPG7 · Ataxia

Abstract

A 43-year-old man presented with a slowly progressive fatigue and coordination problems, coupled with a radiological appearance of diffuse atrophy, especially in the cerebellar hemispheres. The diagnostic process was challenging because initially the additional investigations were focused on a cerebellar ataxia. In the following months, his ataxic gait developed in a more spastic pattern and whole exome sequencing revealed mutations in the SPG7 gene, confirming a diagnosis of hereditary spastic paraplegia. Therefore, the authors call for an extension of genetic panels in ataxia patients.

© 2020 The Author(s)
Published by S. Karger AG, Basel

Introduction

Late-onset ataxias are rare neurological conditions caused by a variety of diseases. This diverse etiology requires extensive clinical, metabolic and genetic workup. In view of the frequency with which genetic/inherited factors cause ataxia, a decent family history is crucial. Generally speaking, late-onset ataxias tend to be of autosomal dominant inheritance and classically genetic panels for the spinocerebellar ataxias (SCAs) are performed in these cases. However, in recent years a gene known to cause hereditary spastic paraplegia type 7 (HSP-7) has showed to be a major cause of unexplained ataxia presenting in mid-adult life. Here, we

report a case of a patient with an unexplained late-onset ataxia, which turned out to be based on HSP-7.

Case Report

A 43-year-old man was seen with complaints of progressive fatigue in the last 9 months. A mild obstructive sleep apnea syndrome (OSAS) was diagnosed, but he also had an unbalanced gait for many years, which he attributed to a traumatic leg injury in childhood. Neurological examination showed saccadic intrusions during smooth pursuit with a bidirectional nystagmus. There was asymmetrical limb ataxia with his left side being more affected than his right, making his gait uncoordinated and slow (online suppl. Video 1; for all online suppl. material, see www.karger.com/doi/10.1159/000509346). There were no signs of peripheral neuropathy and reflexes were normal. Family history was negative and laboratory tests including onco-neuronal antibodies showed no abnormalities. MR brain scanning showed diffuse cerebral and cerebellar atrophy, more pronounced infratentorial, with the cerebellar hemispheres more affected than the brainstem (Fig. 1).

We suspected a genetic or metabolic disorder, but extensive laboratory tests (including thyroid hormone, vitamin levels and anti-gliadine/-tissue transglutaminase/-endomysium antibodies) and a cerebellar ataxia panel (49 genes) were normal.

Six months later, the patient reported some dizziness while standing up, making us to consider that his cerebellar ataxia and atrophy was due to multiple system atrophy (MSA-c). However, autonomic function testing, including a head-up tilt table test, showed no orthostatic hypotension and IBZM-SPECT imaging was completely normal.

After another 6 months, his ataxic gait slowly turned into a more spastic pattern and his reflexes were now brisk with a left extensive plantar response. Repeat MR scan was unaltered, but whole exome sequencing revealed two heterozygous mutations (p.Arg485_Glu487del and p.Ala510Val) in the SPG-7 gene, confirming a diagnosis of hereditary spastic paraplegia type 7 (HSP-7).

One year later, his younger brother came to our neurology department with impaired walking and difficulty climbing stairs. His examination findings included mild spasticity in the legs, hyperreflexia and a slow, wide-based and cautious walking pattern (online suppl. Video 2). Mutation analysis of the SPG-7 gene was performed and was positive as well.

Discussion

Hereditary spastic paraplegia (HSP) refers to a group of familial diseases that are characterized by progressive degeneration of the corticospinal tracts. The prevalence differs from 1.3 to 9.6 per 100.000 individuals in several European countries [1, 2].

In 1880, neurologist Adolf von Strümpell reported the first case in which ‘a little lame father’ had a son aged 58 years, who was affected by spastic paraplegia which hindered him in his work. A second son developed walking difficulties at the age of 56 years, and a third was nursed for many years for arthritis deformans. Apart from the paraparesis and increased deep tendon reflexes, neurological examination in all four showed no other abnormalities. Unfortunately, there are no data disclosed of the 29 children of the eldest son [3]. In the following years, Strümpell in Germany and Lorrain in France described similar families and named this heterogeneous group of neurodegenerative disorders Strümpell-Lorrain disease [4, 5].

It took more than a century before Harding in 1981 was the first to distinguish a pure and a complicated form of HSP. In her ‘classification of the hereditary spastic paraplegias’ she did not only make differences in age of onset and inheritance, but also divided them in two groups: the ones with (just) pyramidal signs in the lower limbs and increased tendon reflexes, and the ones with additional neurological and systemic features [6]. Nowadays, although genetic determination revealed more than 50 HSP loci and more than 40 HSP-related genes, this categorization is still relevant [7].

The age of onset in uncomplicated (or “pure”) HSP varies from infancy through late adulthood. Patients present with progressive gait disturbances and stiffness. Neurologic examination demonstrates lower limb spasticity particularly in the hamstrings, quadriceps, gastrocnemius and adductor muscles. There is weakness in the iliopsoas, tibialis anterior and hamstrings, hyperreflexia and extensor plantar responses, sometimes accompanied by urinary disturbance, pes cavus and mild sensory loss in the lower limbs. No bulbar weakness is found and upper extremities are not affected [8, 9].

In the complicated form, the typical picture of pure HSP is accompanied by other systemic conditions such as epilepsy, cognitive impairment, retinopathy, amyotrophy and ataxia (in the absence of other causes for these additional features) [10, 11]. Because of this great phenotypic diversity, several of these conditions were classified in the group of the ataxias, dementias and leukodystrophies in the past, while other neurological conditions have unfairly been scolded for HSP.

The clinical heterogeneity is also reflected in the different forms of inheritance. HSP can be inherited in an autosomal dominant, autosomal recessive and X-linked manner [12]. The different genetic loci are designated SPG (for “spastic paraplegia”) in order of their discovery. More than 80% of the pure forms, including the most frequent SPG4 and SPG3 inherit autosomal dominant, while the heterogeneity of the complicated forms is matched by a more genetic heterogeneity [13]. SPG7 is one of the more common autosomal recessive paraplegias and its phenotype is heterogeneous with both pure and complicated families being found. MR brain imaging shows in almost all patients cerebellar atrophy, which is sometimes accompanied by a clinical picture of cerebellar ataxia. Furthermore, optic nerve atrophy and peripheral neuropathy are frequently observed. It is important to distinguish SPG7 from hereditary ataxias [14].

In our case, we were misled by the lack of a positive family history and the patients clinical picture in which ataxia was the prominent feature. The additional brain MRI showing cerebellar atrophy suggested a genetic cause, however, SPG genes were not included at the time we requested the ataxia gene panel. Eventually, more than 2 years later, whole exome sequencing revealed mutations in the SPG7 gene, making a diagnosis easier in case of his brother. This case corresponds to recent literature [15], in which cerebellar ataxia is described as the presenting symptom in patients with HSP-7. Therefore, in most current ataxia gene panels, SPG7 is now included, which prevents unnecessary delay in diagnoses.

Statement of Ethics

The authors have no ethical conflicts to disclose. The authors confirm obtaining written consent from the patients for publication of the manuscript (including images, videos, case history, and data).

Conflict of Interest Statement

The authors have no conflicts of interest to declare.

Funding Sources

No funding was received.

Author Contributions

T.L. followed the patient, contributed to the diagnosis, physical examination, and testing of the patient and wrote the paper. G.H. contributed to the writing and revision of the manuscript.

References

- 1 McMonagle P, Webb S, Hutchinson M. The prevalence of “pure” autosomal dominant hereditary spastic paraparesis in the island of Ireland. *J Neurol Neurosurg Psychiatry*. 2002 Jan;72(1):43–6.
- 2 Sedel F, Fontaine B, Saudubray JM, Lyon-Caen O. Hereditary spastic paraparesis in adults associated with inborn errors of metabolism: a diagnostic approach. *J Inherit Metab Dis*. 2007 Nov;30(6):855–64.
- 3 Strümpell A. Beiträge zur Pathologie des Rückenmarks. *Arch Psychiatr Nervenkr*. 1880;10(3):676–717.
- 4 Strümpell A. Ueber die hereditäre spastische Spinalparalyse. *Dtsch Z Nervenheilkd*. 1893;4(3-4):173–88.
- 5 Lorrain M. Contribution à l'étude de la paraplégie spasmodique familiale. Paris: Steinheil; 1898.
- 6 Harding AE. Classification of the hereditary ataxias and paraplegias. *Lancet*. 1983 May;1(8334):1151–5.
- 7 Fink JK. Hereditary spastic paraplegia: clinico-pathologic features and emerging molecular mechanisms. *Acta Neuropathol*. 2013 Sep;126(3):307–28.
- 8 Harding AE. Hereditary “pure” spastic paraplegia: a clinical and genetic study of 22 families. *J Neurol Neurosurg Psychiatry*. 1981 Oct;44(10):871–83.
- 9 Dürr A, Brice A, Serdaru M, Rancurel G, Derouesné C, Lyon-Caen O, et al. The phenotype of “pure” autosomal dominant spastic paraplegia. *Neurology*. 1994 Jul;44(7):1274–7.
- 10 Hentati A, Pericak-Vance MA, Hung WY, Belal S, Laing N, Boustany RM, et al. Linkage of ‘pure’ autosomal recessive familial spastic paraplegia to chromosome 8 markers and evidence of genetic locus heterogeneity. *Hum Mol Genet*. 1994a Aug;3(8):1263–7.
- 11 Pensato V, Castellotti B, Gellera C, Pareyson D, Ciano C, Nanetti L, et al. Overlapping phenotypes in complex spastic paraplegias SPG11, SPG15, SPG35 and SPG48. *Brain*. 2014 Jul;137(Pt 7):1907–20.
- 12 Finsterer J, Löscher W, Quasthoff S, Wanschitz J, Auer-Grumbach M, Stevanin G. Hereditary spastic paraplegias with autosomal dominant, recessive, X-linked, or maternal trait of inheritance. *J Neurol Sci*. 2012 Jul;318(1-2):1–18.
- 13 Magariello A, Muglia M, Patitucci A, Ungaro C, Mazzei R, Gabriele AL, et al. Mutation analysis of the SPG4 gene in Italian patients with pure and complicated forms of spastic paraplegia. *J Neurol Sci*. 2010 Jan;288(1-2):96–100.
- 14 van Gassen KL, van der Heijden CD, de Bot ST, den Dunnen WF, van den Berg LH, Verschuuren-Bemelmans CC, et al. Genotype-phenotype correlations in spastic paraplegia type 7: a study in a large Dutch cohort. *Brain*. 2012 Oct;135(Pt 10):2994–3004.
- 15 Pfeffer G, Pyle A, Griffin H, Miller J, Wilson V, Turnbull L, et al. SPG7 mutations are a common cause of undiagnosed ataxia. *Neurology*. 2015 Mar;84(11):1174–6.

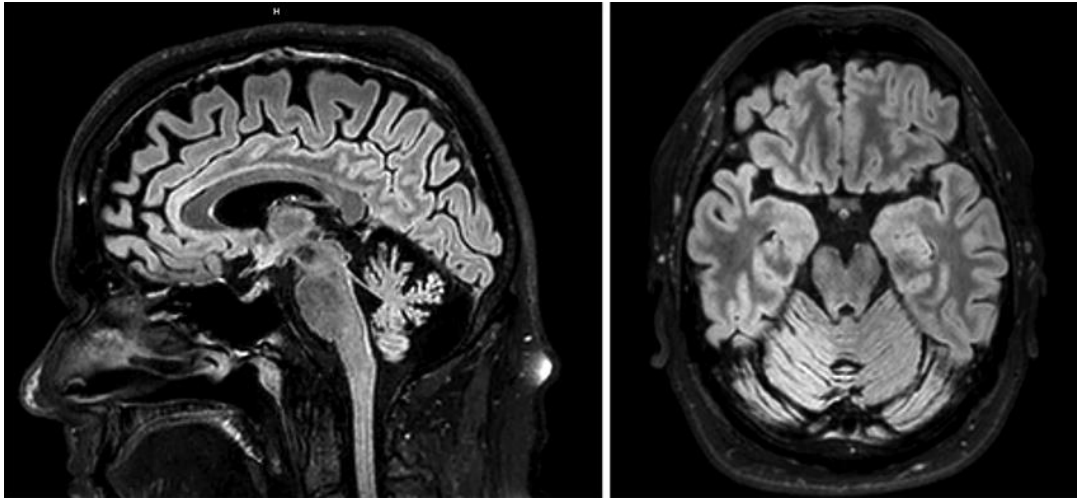


Fig. 1. MRI midsagittal (left) and axial (right) FLAIR showing especially cerebellar atrophy.