



Case report

Airway fibroepithelial polyposis



Gonzalo Labarca^{a,b,*}, Ivan Caviedes^c, Macarena R. Vial^c, Yumay Pires^d, Erik Folch^e, Adnan Majid^f, Sebastian Fernandez-Bussy^c

^a Facultad de Medicina, Universidad San Sebastian, Concepcion, Chile

^b Complejo Asistencial Dr. Victor Rios Ruiz, Los Angeles, Chile

^c Intervencional Pulmonology, Facultad de Medicina Clínica Alemana-Universidad del Desarrollo, Santiago, Chile

^d Servicio de Patología, Clínica Alemana de Santiago, Universidad del Desarrollo, Santiago, Chile

^e Division of Pulmonary and Critical Care Medicine, Massachusetts General Hospital, Harvard Medical School, Boston, MA, USA

^f Division of Thoracic Surgery and Intervencional Pulmonology, Beth Israel Deaconess Medical Center, Boston, MA, USA

ARTICLE INFO

Article history:

Received 19 April 2017

Received in revised form

7 August 2017

Accepted 7 August 2017

Keywords:

Fibroepithelial polyp

Trachea

Bronchoscopy

Benign airway lesion

Argon plasma coagulation

ABSTRACT

Fibroepithelial polyps are benign lesions, frequently found in the skin and genitourinary tract. Airway involvement is rare, and few case reports have been published. Our patient was a 79 y.o. male smoker, who was referred to us with a 3-month history of dry cough. At physical examination, the patient looked well, but a chest CT showed a 6-mm polyp lesion in his trachea. A flexible bronchoscopy confirmed this lesion, and forceps biopsies were performed. Argon plasma coagulation was used to completely resect and treat the lesion. Pathological analysis revealed a fibroepithelial polyp (FP). The aim of this manuscript is to report a case of FP with bronchoscopic management and to review the current literature about this condition.

© 2017 The Authors. Published by Elsevier Ltd. This is an open access article under the CC BY-NC-ND license (<http://creativecommons.org/licenses/by-nc-nd/4.0/>).

1. Introduction

Benign airway lesions are uncommon, comprising less than 2% of all airway lesions. Estimate prevalence according United State of America data is 2.6 per 100.000 habitants. These lesions compromise tracheobronchial tree and are related with an increased risk of complication, including life threatening condition. Etiology includes hamartomas (chondroid, non chondroid), inflammatory polyps, papillomas (simple, glandular, squamous), leiomiomas, schwannomas, hemangiomas, tumorlets, neurofibroma. Consequences are related to occlusion of the airway lumen due to intraluminal proliferation of the tumor as well as potential malignant transformation [1].

Fibroepithelial polyps (FP) consist of a benign proliferation commonly found in the skin and genitourinary tract [2]. Respiratory fibroepithelial polyposis is an infrequent disease, poorly described, and without a clear pathogenesis. However, due to the improvement of the available quality of imaging in chest radiology and bronchoscopy, several cases of this disease have been reported

in upper and lower airways. Prompt diagnosis and interpretation of radiological and bronchoscopic findings are necessary to evaluate the clinical and pathological behavior of respiratory fibroepithelial polyposis [3].

We report a case of FP, including a literature review using the PubMed (MEDLINE), Lilacs, and Google scholar databases.

2. Case report

A 79-year-old male with a 20 year history of smoking was referred to us with a dry cough of 3 month duration. He had no prior history of respiratory allergies, gastroesophageal reflux symptoms or chronic sinus symptoms. He had not experienced fevers, dyspnea or symptoms of bronchial obstruction. The patient's only pre-existing condition was well-controlled blood hypertension.

At physical examination, he was afebrile and morbidly obese (BMI 31 kg/m²). His blood pressure was 135/88, pulse was 82 beats/minute, and respiratory rate was within normal range. Oxygen saturation was 95% on room air and his lungs were clear to auscultation. The rest of the physical examination was unremarkable.

Laboratory testing showed a normal white blood count, without

* Corresponding author. Lientur 1457, Concepcion, 4080871, Chile.

E-mail address: glabarcat@gmail.com (G. Labarca).

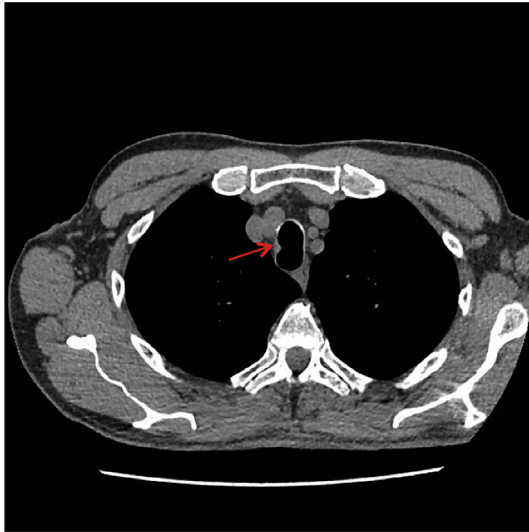


Fig. 1. Chest CT showed a 6mm polypoid lesion at the right lateral aspect of the proximal trachea.

eosinophilia, anemia or thrombocytopenia. His biochemistry profile was within normal limits, including IgE levels, AST, ALT, LDH, CRP and creatine kinase. Antinuclear antibodies (ANA), double-stranded antibody (Anti-dsDNA), rheumatoid factor, complement levels, and anti-neutrophil cytoplasmic antibody ANCA (PR3-MPO) were all negative.

Chest radiographs were normal, but due to his smoking history we decided to perform a chest CT scan. CT results showed mild centrilobular emphysema and a 6-mm polypoid lesion in the right wall of the proximal trachea (Fig. 1).

Flexible bronchoscopy revealed a polypoid lesion with a pink mucosa and firm consistency in the right lateral wall of the proximal trachea (Fig. 2). We biopsied the lesion with forceps, then used argon plasma coagulation to entirely resect the lesion and treat the base. The pathology report described a polyp with a long stalk and marked papillary or finger-like projections. The nodules consisted of fibrovascular stroma with scattered lymphocytes, plasma cells, and erythrocytes, and lined by normal epithelium with ciliated pseudostratified columnar epithelia and stratified squamous epithelia. (Fig. 3a–d) Complementary analyses using protein C, which is reactive for human papillomavirus (HPV) 6 and 11, were negative.

Follow up: One month after the procedure, the patient's cough had diminished but had not disappeared completely. We believe his cough was also caused by respiratory allergies.

3. Discussion

Fibroepithelial polyposis is a rare and benign disease described initially by Rowlands and cols [4] in 1960. In our literature review we found 30 cases of airway fibroepithelial polyps, including our case [2,3,5–8]. The average age at diagnosis was 61 years (Standard deviation \pm 14,72 years). This disease was most frequently found in men (25/30 cases, or 83%).

Symptoms are mild or seen in association with pneumonia. Several cases were diagnosed only as an incidental radiological finding, discovered in association with pneumonia (10 cases), or in 8 asymptomatic cases. However, when the size of the FP lesion is bigger, symptoms such as airway obstruction and hemoptysis are frequent. In our review, 6/30 (20%) cases were associated with hemoptysis, and one case presented with airway obstruction.

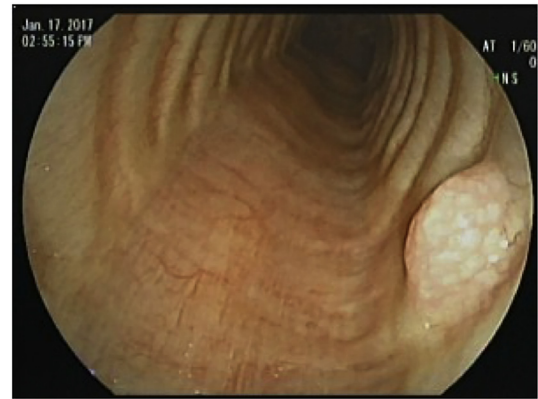


Fig. 2. White light videobronchoscopy revealed a polypoid lesion with whitish pink mucosa.

Differential diagnoses for FP lesions include neoplasia (bronchogenic carcinoma, metastatic lesions to the airway, plasmacytomas); rheumatologic disorders (vasculitis, amyloidosis, rheumatoid arthritis); infections (papilloma virus, mucus plug) and benign airway lesions (chondromas, central airway granulomas, leiomyoma, lipoma, neuroma, hamartomas).

Radiologic findings usually show a well-defined polyp lesion, and lobulated margins of the polyp are recognizable with chest CT scan [9]. Size and location of FP varies widely. We found an average diameter size of 15.30 mm (SD 19.12 mm), with 15/30 cases (50%) located in right bronchial tree, 11 (37%) in left bronchial tree, and 4 (13%) in the trachea. A literature review of the clinical, radiological and therapeutic approaches of the published cases is summarized in Table 1.

Bronchoscopic evaluation reveals a pedunculated firm polypoid lesion, with a pink colored mucosa. These are important characteristics for evaluating this endobronchial lesion [5].

Histologic findings of a fibroepithelial polyp demonstrate a regular, normal respiratory epithelium with a core of connective tissue. The stromal component is dense, with a collagenous hypocellular matrix with thin-walled vessels, and lacking epithelial overgrowth. Herpes papilloma virus analysis must be negative [9].

The most common treatment includes endoscopic procedures such as endobronchial excision with biopsy forceps. However, an endoscopic thermoablative technique (argon plasma coagulation, electrocautery or laser) can be used in addition to completely resect and treat the polyp. Rigid bronchoscopy is recommended for endoluminal lesions with critical airway obstruction. Its working channel and suction power is bigger than flexible bronchoscopy. Tumor resection is also performed using the tip of the rigid scope. Our patient had a 6mm tracheal lesion seen on CT scan, so flexible bronchoscopy resection is safe for small lesions with no significant airway obstruction For the largest noted lesion (more than 10 mm), surgical resection was utilized [6].

Prognosis is generally good in most cases. No data about mortality associated with fibroepithelial polyps has been published, and no treatment-related mortality has been reported either. The endoscopic approach is a safe and useful method to remove these lesions.

Finally, we have not found any reports on recurrence or malignant transformation of FP. CT images and/or bronchoscopy surveillance are used to follow up others benign tracheobronchial tumors to diagnose recurrence or malignancy [1].

4. Conclusion

Airway fibroepithelial polyps are uncommon benign lesions that

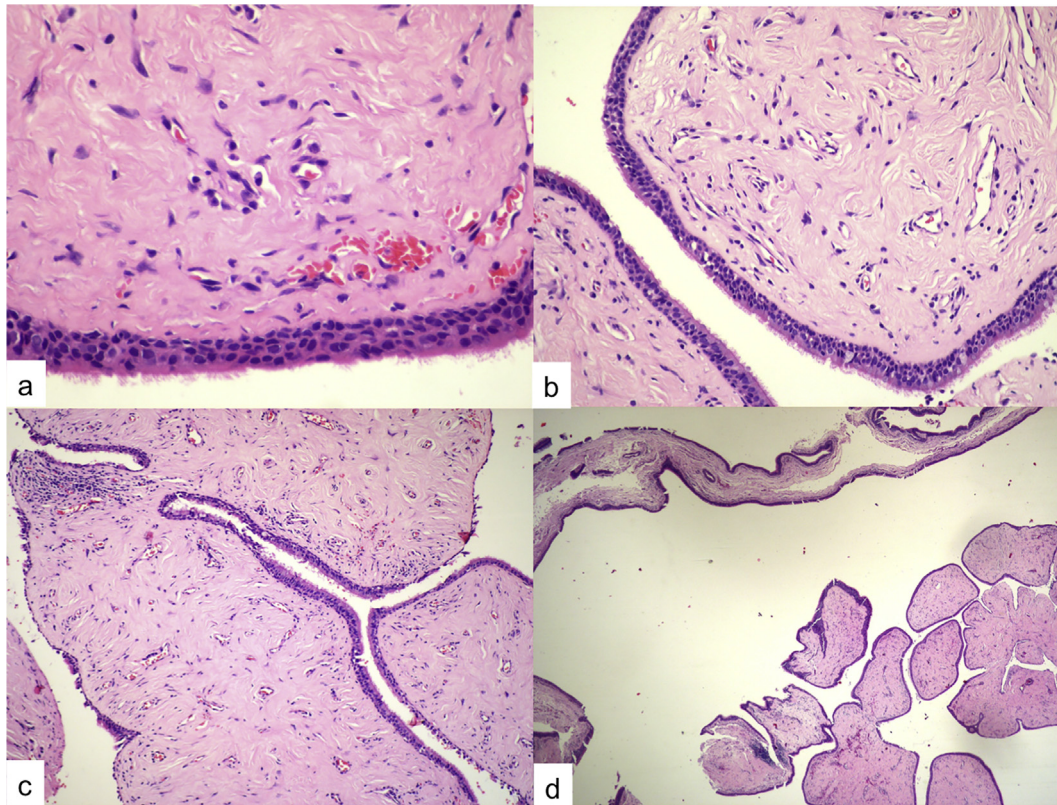


Fig. 3. a) Scanning photograph of sagittal section of polyp showing a long stalk and marked papillary or finger-like projections of nodule (H & E stain, $\times 2$). Low-power and high-power photomicrographs shows that polyp consists of fibrovascular stroma with scattered lymphocytes, plasma cells and erythrocytes and lined by normal respiratory epithelium with ciliated pseudostratified columnar epithelium and stratified squamous epithelium (H & E stain, $\times 40$, Fig. 3a; $\times 20$, Fig. 3b; $\times 10$ Fig. 3c).

Table 1

Summary of previous case reports including our case. M: male; F: female, ND: No data; RB: Right bronchi; LB: left bronchi; S: Surgery; E: Endoscopy.

Age	Sex	Symptoms	Size	Location	Therapy
38	M	Recurrent pneumonia	9	RB	S
65	F	Pneumonia	30	LB	E
55	M	Recurrent pneumonia	100	Trachea	S
81	M	Dyspnea	15	RB	E
37	F	Recurrent pneumonia	ND	RB	E
32	M	Recurrent pneumonia	30	LB	S
55	M	Dyspnea	20	Trachea	E
69	M	Bronchial obstruction	ND	Trachea	E
37	F	Recurrent pneumonia	ND	RB	E
38	M	Recurrent pneumonia	29	LB	S
77	M	Hemoptysis	17	LB	E
47	M	Dyspnea	12	LB	E
61	M	Fever, hemoptysis	25	RB	E
45	M	Pneumonia	20	RB	E
78	M	Hemoptysis	20	RB	S
69	M	Hemoptysis	10	RB	E
68	M	Asymptomatic	4	RB	E
68	F	Asymptomatic	6	LB	E
68	M	Pneumonia	10	LB	E
76	M	Asymptomatic	5	RB	E
59	M	Cough	10	RB	E
56	M	Hemoptysis	8	RB	E
81	M	Hemoptysis	4	LB	E
54	F	Asymptomatic	2	RB	E
53	M	Asymptomatic	4	LB	E
75	M	Asymptomatic	2	LB	E
74	M	Asymptomatic	3	LB	E
68	M	Asymptomatic	3	RB	E
76	M	Pneumonia	9	RB	E
69	M	Cough	6	Trachea	E

are usually diagnosed as incidental radiological findings, or in association with pneumonia. A bronchoscopic approach with the use of excisional biopsy and thermoablative technique is a safe and effective treatment.

Contribution

GL SF, AM: Providing the cases, and writing the manuscript and submitting the manuscript. Final approval proof.

YP: pathological data and analysis. Critical analysis and final approval proof.

IC, EF and MR: Contribution: Reviewing and editing the manuscript. Final Approval proof.

No source(s) of support in the form of grants, gifts, equipment, and/or drugs are available for this manuscript. No conflict of interest to disclose for all authors.

References

- [1] S. Scarlata, P. Graziano, G. Lucantoni, P. Battistoni, S. Batzella, R. Dello Jacono, R. Antonelli Incalzi, G. Galluccio, Endoscopic treatment of primary benign central airway tumors: results from a large consecutive case series and decision making flow chart to address bronchoscopic excision, *Eur. J. Surg. Oncol.* 41 (2015) 1437–1442.
- [2] R.C. Melo, C. Ribeiro, A. Sanches, A. Oliveira, A rare benign tumor of tracheo-bronchial tree: endobronchial fibroepithelial polyp, *Rev. Port. Pneumol.* 2015 (21) (2006) 221–222.
- [3] M. Li, G. Zhang, A. Peng, C. Wang, Bronchial fibroepithelial polyp: a case report and review of the literature, *Intern Med.* 52 (2013) 373–376.
- [4] D.T. Rowlands Jr., Fibroepithelial polyps of the bronchus: a case report and review of the literature, *Dis. Chest* 37 (1960) 199–202.
- [5] A.P. Maskey, F. Almeida, C. Farver, Endobronchial fibroepithelial polyp, *J. Bronchology Interv. Pulmonol.* 19 (2012) 313–314.
- [6] E. Casalini, A. Cavazza, A. Andreani, A. Marchioni, G. Montanari, F.G. Cappiello,

- M.C. Mengoli, P. Corradini, L. Agostini, R. Serini, G. Rossi, Bronchial fibroepithelial polyp: a clinico-radiologic, bronchoscopic, histopathological and in-situ hybridisation study of 15 cases of a poorly recognised lesion, *Clin. Respir. J.* 11 (2017) 43–48.
- [7] P.B. Amin, F. Baciewicz, Benign fibroepithelial polyp arising in the bronchus: a case report and review of the literature, *Arch. Surg.* 144 (2009) 1081–1083.
- [8] A. Ushiki, M. Yasuo, T. Tanabe, K. Urushihata, H. Yamamoto, M. Hanaoka, T. Koizumi, K. Fujimoto, K. Kubo, Y. Yamazaki, K. Asano, A rare case of a tracheal fibroepithelial polyp treated by an endobronchial resection, *Intern Med.* 47 (2008) 1723–1726.
- [9] H. Kang, T.S. Kim, J. Han, H. Kim, Fibroepithelial polyp of the bronchus: CT and histopathologic findings, *Korean J. Radiol.* 13 (2012) 355–357.