



## Case report

## Rare association of traumatic diaphragmatic hernia with spinal cord injury: A case report

R.M.G.K. Rathnayaka<sup>a,\*</sup>, Kalaventhan Pathinathan<sup>b</sup>, S. Sivamynthan<sup>a</sup>, N. Pirashanthan<sup>b</sup>,  
Parathan Sriharan<sup>b</sup>, Dilshan Munidasa<sup>c</sup>

<sup>a</sup> General Surgery, Postgraduate Institute of Medicine, University of Colombo, Sri Lanka

<sup>b</sup> Orthopaedic Surgery, Postgraduate Institute of Medicine, University of Colombo, Sri Lanka

<sup>c</sup> Department of Trauma and Orthopaedics, National Hospital-Colombo, Sri Lanka

## ARTICLE INFO

## Keywords:

Case report  
Diaphragmatic hernia  
Laparotomy  
Spinal cord injury  
Thoracolumbar spine

## ABSTRACT

**Introduction and importance:** The traumatic diaphragmatic hernia could be missed in the background of spinal fractures due to neurological weakness. We report the first case of the management of thoracolumbar fracture-dislocation associated with diaphragmatic injury.

**Presentation of case:** 53-year-old male transferred from local hospital following fallen from a motorbike on the 4th day after the injury. He was paraplegic from L1 below with sacral root involvement. Further imaging showed fracture-dislocation of the vertebral body at the T12-L1 level and anterior displacement of T11 on T12. The left-sided diaphragmatic hernia was detected by chest x-ray with bowel shadows in the left hemithorax. Emergency laparotomy and diaphragmatic repair followed by a posterior spinal exploration and pedicle screw fixation were done. Early mobilization was done after spinal fixation and the patient is successfully continuing rehabilitation.

**Clinical discussion:** Thoracolumbar fracture-dislocation associated with the traumatic diaphragmatic hernia is rare. Clinical diagnosis of associated visceral injuries could be delayed due to the neurological deficit of the patient. An initial concern was to repair the life-threatening diaphragmatic hernia. Even current studies showed improved neurological function from early spinal surgery, spinal fixation had to delay as surgery needs a prone position.

**Conclusion:** Early identification and management of traumatic diaphragmatic hernia are life-saving and allows early surgical intervention for the spine. Early reduction and fixation are associated with improved neurological function and will allow early mobilization and reduce hospital and ICU stay.

### 1. Introduction

Spinal cord injuries play a major role in traumatic injuries which directly affects the patient's morbidity mortality and quality of life of the patients. Vertebral fractures are seen in 3% of polytrauma patients [1]. Spinal cord injuries occur due to the primary injury by the direct force or secondarily by ischemia, inflammation, or compression by fractured vertebral segments.

Fracture dislocation of the Thoracolumbar spine occurs due to the massive force transmitted through the spine. It is usually associated with other injuries such as Vascular damage, visceral injuries, rib fractures, and lung contusions which can be missed due to neurological deficits [1,2]. Traumatic thoracolumbar spine fracture-dislocation with concomitant aortic injury is uncommon but fatal [3]. But this is the first

of the management of the fracture-dislocation associated with the Traumatic diaphragmatic rupture.

### 2. Method

We report this case in line with the updated consensus-based surgical case report (SCARE) guidelines [4].

### 3. Case report

A 53-year-old male was transferred from a local hospital following fallen from a motorbike under the influence of alcohol on the fourth day after the trauma. He had no significant past medical history and took no regular medications. On admission, he was fully conscious. Abrasions

\* Corresponding author at: No 1/37, Mihindu Mawatha, Rambukkana, Sri Lanka.

E-mail address: [rmgkayankrishan@gmail.com](mailto:rmgkayankrishan@gmail.com) (R.M.G.K. Rathnayaka).

<https://doi.org/10.1016/j.ijscr.2021.106517>

Received 17 September 2021; Received in revised form 12 October 2021; Accepted 13 October 2021

Available online 16 October 2021

2210-2612/© 2021 The Authors. Published by Elsevier Ltd on behalf of IJS Publishing Group Ltd. This is an open access article under the CC BY-NC-ND license

(<http://creativecommons.org/licenses/by-nc-nd/4.0/>).

were seen in the left hypochondrium. He had bilateral rib fractures and left hemothorax. He was paraplegic with muscle power 0/5 below L1 myotome level with the loss of anal tone. He had paresthesia Below T12 dermatomal level (ASIA A). The skin over the lower lumbar spine was tented due to the protruding spinous processes of the dislocated lumbar vertebrae. X-ray images, Non-Contrast Computed tomography (NCCT) images, and magnetic resonant images revealed the fracture-dislocation of the L1 vertebra with posterior displacement of the L2 and lower vertebral column (Fig. 1). His vital signs were stable, His respiratory rate was 16 breaths per minute and arterial oxygen saturation was 96%. He did not show symptoms of spinal shock or respiratory distress.

An initial chest X-ray was not taken at the local hospital. The chest X-ray revealed the bowel shadows in the left lung field (Fig. 2). There were no clinical or radiological features of the visceral organ perforations during the process of evaluation.

Laparotomy was done by the Casualty surgeon in the Emergency and trauma center of the National Hospital Colombo on the same day of the transfer. Jejunum and spleen were herniated to the left hemithorax through the diaphragmatic defect. The bowel was reduced to the abdomen and diaphragmatic repair was done. No other injuries were found intraoperatively, and postoperative intensive care was given. Postoperative standard spinal trauma care was provided with strict bed rest, compressive stockings, and nutritional support. Spinal fixation was planned four weeks after the laparotomy. But due to the pandemic situation surgery was delayed up to the sixth week after laparotomy.

Exploration of the thoracolumbar spine was done by the Orthopaedic surgeon in the orthopaedics and trauma department of the National Hospital Colombo. The posterior approach was used to access the Lumbar vertebra. L1 vertebral body fracture with T12-L1 spondyloptosis was detected with severe spinal cord compression. No Dural tare was detected. Spinal decompression and long segment two-level pedicle screw fixation was done.

Rehabilitation was started the next day after spinal fixation. Postoperative neurological recovery was not detected below the spinal cord compression. But at the level of the injury, the L1 myotome was

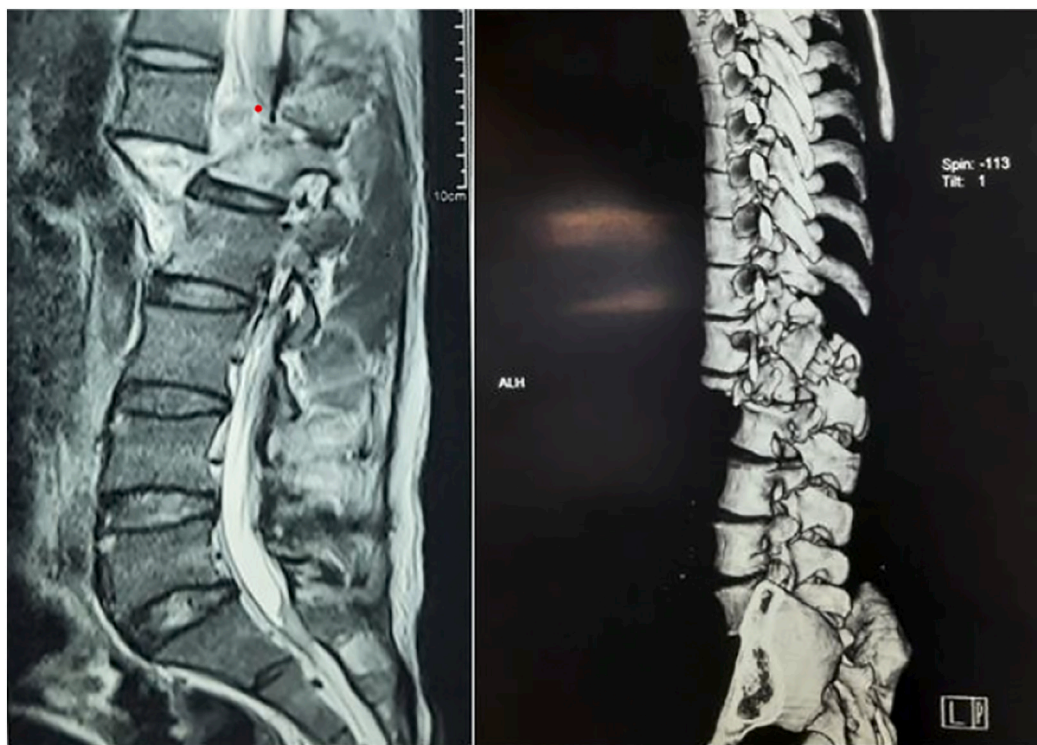achieved a 2/5 muscle power. Bilateral lower limb sensory improvement was detected at both lower limbs.

#### 4. Discussion

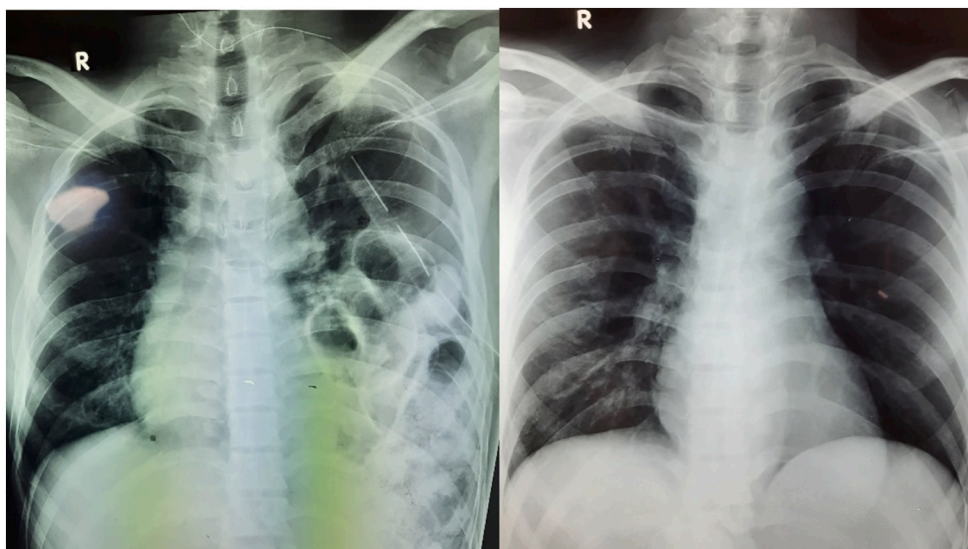
The annual incidence of spinal fractures is 64 per 100,000 and neurological deficit is seen in 10–30% [5]. Most of these injuries involve in thoracolumbar region, but thoracolumbar fracture-dislocations are much rare [1]. Most fracture-dislocations are associated with complete neurological deficit [1]. The commonly young population is affected [1]. A previous study reported females with a greater number of pre-existing co-morbidities, a higher frequency of Thoraco-lumbar trauma, and less severe neurological impairment [6].

Closed traumatic thoracolumbar spondylosis occurs due to the very high energy trauma involving simultaneous multidirectional, distractive, and compressive forces across various spinal elements [1]. It is commonly associated with significant neurological deficit and vascular and visceral injuries. Lung contusion, Hemopneumothorax, bowel perforation, and vascular injury are common among these injuries [1,2]. These injuries will increase the mortality and morbidity of the patient and delay the surgical intervention for the spine [2]. Diaphragmatic injuries have commonly occurred with blunt forces (3.4%) [7,8]. 75–80% cases blunt trauma causes injury to the left hemi-diaphragm [7]. Definitive diagnosis with chest x-ray is very challenging [7]. Further due to initial neurological deficits this can be easily missed during the clinical assessment (Late diagnosis made in 9.5% of traumatic diaphragmatic injuries) [9]. Therefore clinical diagnosis requires a high level of suspicion [7]. In high-energy spinal fractures, less threshold to do an NCCT chest abdomen will help to identify the secondary injuries and prevent unnecessary delay of the spinal fixation.

Intra-abdominal access, Posterolateral thoracotomy, and combined thoracoabdominal incisions are used to repair the Diaphragmatic hernia [8]. Laparotomy incision was used in this case because of the suspicion of other intraabdominal injuries, early surgery, and familiarity with the surgeon. Posterolateral thoracotomy warrants a good exposure for



**Fig. 1.** T2-weighted magnetic resonance images and Three-dimensional computed tomography in the reconstruction view show traumatic spondyloptosis of T12/L1 with lower lumbar cord edema/contusion, conus medullaris, and upper cauda equina compression.



**Fig. 2.** Left image: Preoperative chest x-ray shows multiple small bowel loops and Chest tube in the left hemithorax. Right image: Postoperative chest x-ray after diaphragmatic repair.

isolated diaphragmatic hernia and it will help to release the intrathoracic adhesions in delayed surgeries [8].

Due to significant dislocation, spinal cord injury and nerve root damage are significant at the level of the trauma. The possibility of neurological recovery below the level of spinal cord injury is negligible. Therefore reduction and fixation are mainly aimed for the early mobilization, reduced pain, prevent further spinal cord injury, and reduced the duration of hospital stay [1,10,11].

Traumatic Dural tears are commonly associated with thoracic lumbar spinal trauma in the range of 18–36% [1,12]. Surgery will help to identify the Dural tare and spinal root compression which are feasible to repair, and which will prevent CSF leak improve the post-operative rehabilitation, and prevent chronic pain and phantom sensation, in our case dura was intact even there was a severe injury. No nerve root compression was detected.

The surgical approaches to the fracture-dislocation can be an anterior, combined anterior and posterior, or posterior [13]. Better canal decompression, easy access to the anterior column, and intervertebral fixation are the advantages of the anterior approach. But it will not provide sufficient traction for fracture reduction [13]. The combined anterior and posterior approach improves sagittal alignment, Better neural decompression. But It is associated with more intraoperative bleeding and extended surgery time and the need to change the position during surgery [13]. Because of the previous abdominal surgery, the only option for vertebral decompression was the posterior approach. But prone positioning was difficult during the immediate post-operative period after diaphragmatic repair. Therefore spinal surgery had to postpone until the patient fully recovered from the laparotomy. But there was no difference is reported in decompression and neurological outcome between the anterior and posterior approach, but the posterior approach is superior in less blood loss and operative time [13].

Fixation could be a long segment or short segment fixation [13]. In this case, long-segment fixation was used because Long segment posterior fixation is with two levels above and two levels below fixation considered for highly unstable spinal injuries to achieve multiple fixation points and distribute the stress while maintaining alignment [2,13]. Short segment fixation can also be used for thoracolumbar fracture dislocation as it causes less blood loss and fewer operative duration [13].

Advantages of the early surgery versus late surgery are controversial [5]. In our case, the main concern was to immediately repair the life-threatening diaphragmatic hernia. Therefore spinal surgery had to postpone until the patient is fully recovered from the abdominal surgery.

The highest neurological recovery rates were found in patients operated on within 8 h after trauma. After 48 h there was no significant neurological outcome compared to the time of the operation [5,10,14]. But in severe spinal cord injury in spondyloptosis, Neurological improvement below the level of the injury is negligible in contrast to that, there is a significant improvement of the nerve roots at the level of the injury. In some studies report further neurological deterioration following surgical intervention for completely damaged spinal cord injuries and they are not helped by canal decompression [11]. In patients who received surgery after three weeks, the scar has formed around the lesion and obstruct the reduction. For the patients who cannot receive spine surgery in few days after injury, pre-operative traction should be applied [2]. Because the reduction is difficult in delayed surgeries, the anterior approach will be needed to get an adequate reduction [10,15].

## 5. Conclusion

To the best of our knowledge, this is the first reported case of the fracture-dislocation of the thoracolumbar spine associated with the diaphragmatic rupture. Initial identification of the associated diaphragmatic injury could be difficult due to the neurological deficit and associated other injuries. High suspicion for diaphragmatic injury and low threshold for NCCT thorax and abdomen during high-velocity injury helps to early identification and early repair.

## Sources of funding

No institutional or third-party funding sources were used to prepare this case report.

## Ethical approval

This work does not require deliberation by the ethics committee.

## Consent

Informed written consent has been obtained from the patient for the case report and the accompanying images. The written consent is available for review on the request by the editor of the journal.

## Guarantor

Dr. Dilshan Munidasa, Senior Consultant Orthopaedic Surgeon and the supervisor of the case report, Department of Trauma and Orthopaedics, National Hospital Colombo, Sri Lanka.

## Research registration

Not applicable.

## Credit authorship contribution statement

All authors of this case report are involved in patient assessment, management, data collection, and the preparation of this article. The consultant supervised the management and was involved in the correction and final editing of the article.

## Declaration of competing interest

All authors have declared any competing financial or personal interests which could have influenced their work.

## Acknowledgment

All authors of this case report would like to thank other staffs who have been involved in the management of the patient.

## Provenance and peer review

Not commissioned, externally peer-reviewed.

## References

- [1] S. Kumar, M.K. Patralekh, T. Boruah, S.A. Kareem, A. Kumar, R. Kumar, Thoracolumbar fracture dislocation (AO type C injury): a systematic review of surgical reduction techniques 11 (5) (2020) 730–741, <https://doi.org/10.1016/j.jcot.2019.09.016>.
- [2] F. Wang, Y. Zhu, Treatment of complete fracture-dislocation of thoracolumbar spine, *J. Spinal Disord. Tech.* 26 (8) (2013) 421–426, <https://doi.org/10.1097/BSD.0b013e31824e1223>.
- [3] G. Santoro, A. Ramieri, V. Chiarella, M. Vigliotta, M. Domenicucci, Thoraco-lumbar fractures with blunt traumatic aortic injury in adult patients: correlations and management, *Eur. Spine J.* 27 (2018) 248–257, <https://doi.org/10.1007/s00586-018-5601-5>.
- [4] R.A. Agha, T. Franchi, C. Sohrabi, et al., The SCARE 2020 guideline: updating consensus Surgical CAse REport (SCARE) guidelines, *Int. J. Surg.* 84 (2020) 226–230, <https://doi.org/10.1016/j.ijsu.2020.10.034>.
- [5] J.P.H.J. Rutges, F.C. Oner, L.P.H. Leenen, Timing of thoracic and lumbar fracture fixation in spinal injuries: a systematic review of neurological and clinical outcome, *Eur. Spine J.* 16 (5) (2007) 579–587, <https://doi.org/10.1007/s00586-006-0224-7>.
- [6] J.C. Furlan, B.C. Craven, M.G. Fehlings, Sex-related discrepancies in the epidemiology, injury characteristics and outcomes after acute spine trauma: a retrospective cohort study 42 (sup1) (2019) 10–20, <https://doi.org/10.1080/10790268.2019.1607055>.
- [7] M.A. Khan, F. Ali, in: *The etiology, associated injuries and surgical management of post traumatic diaphragmatic hernia; a retrospective study* 271, 2021, pp. 3–7.
- [8] X. Deng, Z. Deng, E. Huang, Surgical management of traumatic diaphragmatic hernia: a single institutional experience of more than two decades, *BMC Surg.* 21 (1) (2021) 1–7, <https://doi.org/10.1186/s12893-021-01141-2>.
- [9] X. Guo, Y. Feng, T. Sun, et al., Clinical guidelines for neurorestorative therapies in spinal cord injury (2021 China version) 9 (1) (2021) 31–49, <https://doi.org/10.26599/jnr.2021.9040003>.
- [10] C. Gaebler, R. Maier, F. Kutscha-Lissberg, L. Mrkonjic, V. Vècsei, Results of spinal cord decompression and thoracolumbar pedicle stabilisation in relation to the time of operation, *Spinal Cord* 37 (1) (1999) 33–39, <https://doi.org/10.1038/sj.sc.3100765>.
- [11] T.O. Boerger, D. Limb, R.A. Dickson, Does “canal clearance” affect neurological outcome after thoracolumbar burst fractures? 82 (5) (2000) 629–635, <https://doi.org/10.1302/0301-620X.82B5.11321>.
- [12] S.E. Lee, C.K. Chung, T.A. Jahng, C.H. Kim, Dural tear and resultant cerebrospinal fluid leaks after cervical spinal trauma, *Eur. Spine J.* 23 (8) (2014) 1772–1776, <https://doi.org/10.1007/s00586-014-3332-9>.
- [13] S. Mittal, S. Ifthekar, K. Ahuja, et al., Outcomes of thoracolumbar fracture-dislocation managed by short-segment and long-segment posterior fixation: a single-center retrospective study 15 (1) (2021) 55–61, <https://doi.org/10.14444/8006>.
- [14] C. Bellabarba, C. Fisher, J.R. Chapman, J.R. Dettori, D.C. Norvell, Does early fracture fixation of thoracolumbar spine fractures decrease morbidity or mortality? *Spine* 35 (SUPPL. 9S) (2010) 138–145, <https://doi.org/10.1097/BRS.0b013e3181d830c1>.
- [15] K. Khatri, K. Farooque, V. Sharma, B. Gupta, S. Gamanagatti, Neglected thoraco lumbar traumatic spine injuries, *Asian Spine J.* 10 (4) (2016) 678–684, <https://doi.org/10.4184/asj.2016.10.4.678>.