

# Late recovery in cerebral fat embolism

Srikanth KP, Sundararajan SR, Rajasekaran S

## ABSTRACT

Fat embolism syndrome presenting primarily with cerebral manifestations is rarely reported. We report here two such patients who showed complete recovery following initial deterioration. The aim of these reports is to highlight that prolonged intensive care and good rehabilitation can lead to normal neurologic recovery despite poor clinical picture initially. The importance of adequate oxygenation to prevent secondary brain damage is emphasized during prolonged recovery.

**Key words:** Cerebral fat embolism, fat embolism syndrome, magnetic resonance imaging brain

## INTRODUCTION

Although fat embolization may occur in almost all patients with pelvic or long bone fractures; in most cases it is sub-clinical.<sup>1,2</sup> The reported incidence of fat embolism syndrome in long bone fractures is 0.5-11% and up to 30% in bilateral femoral fractures.<sup>3-5</sup> Cerebral fat embolism syndrome where the clinical manifestation is dominated by neurological dysfunction is rare and only scarcely reported. Gregorakos *et al.*<sup>6</sup> reported two cases with prolonged coma due to cerebral fat embolism which required ventilatory support for 2 and 3 weeks duration. We report two such cases which recovered completely despite rapid initial deterioration and prolonged coma. Although clinical pictures are well reported, our cases are unique that both presented with normal neurology to the hospital and had neurological worsening due to cerebral fat embolism phenomenon 24-48 h prior to surgery without associated respiratory distress. Both needed ventilation for a prolonged period and had poor mentation at the time of discharge. Furthermore, during the followup they showed complete recovery to normal and social life; highlighting the fact that prolonged intensive care and

good rehabilitation can lead to normal neurology despite poor clinical picture initially.

## CASE REPORTS

### Case 1

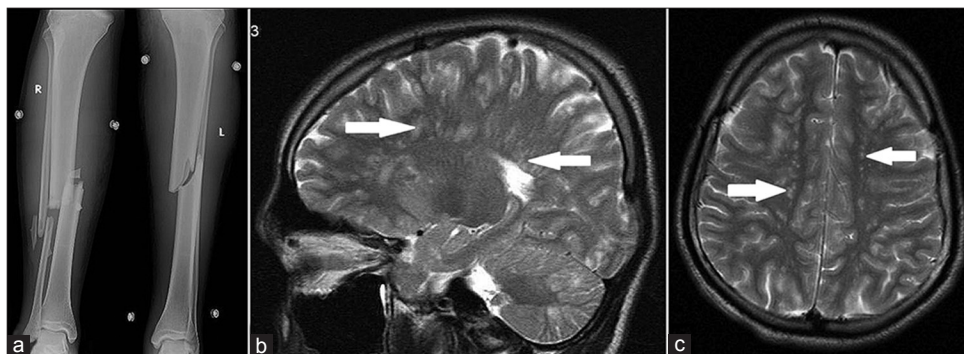
A 20-year-old male presented 7 h following a Road Traffic Accident (RTA) with closed fracture of mid-shaft tibia and fibula involving both his legs. On arrival patient was conscious and oriented with a Glasgow Coma Scale (GCS) - 15/15. He was hemodynamically stable with oxygen saturation of 100% on room air. Blood investigations were normal except for raised serum lactate (5.7 mmol/L). Urine microscopy was negative for fat globules. Fractures in the legs were splinted by above knee slab application.

Two hours after admission (9 h since injury), patient became drowsy with a blood pressure of 116/74 mmHg, oxygen saturation – 84% at room air and pulse rate of 138/min. Oxygen supplementation through the face mask was given. Further 4 h later patient became lethargic and comatose with the GCS falling to 8/15. Electrolyte and metabolic imbalance was ruled out. Computed tomography (CT) brain was carried out which showed no abnormality. Patient was intubated and ventilated and was on supportive treatment with neuro-monitoring. Magnetic resonance imaging (MRI) of the brain revealed multiple well defined tiny hyperintense lesions on T2 and fluid-attenuated inversion-recovery sequences with restricted diffusion bilaterally scattered in the subcortical white matter, centrum semiovale, basal ganglia, thalami and cerebellum suggestive of multiple tiny infarcts due to fat embolism [Figure 1]. Chest X-ray which was initially clear, revealed minimal bilateral diffuse haziness only after 3 days [Figure 2]. Fractures of both bones of both legs were stabilized by external fixation on 4th day after injury. Patient regained consciousness only after 2 weeks, but had poor higher mental functions such

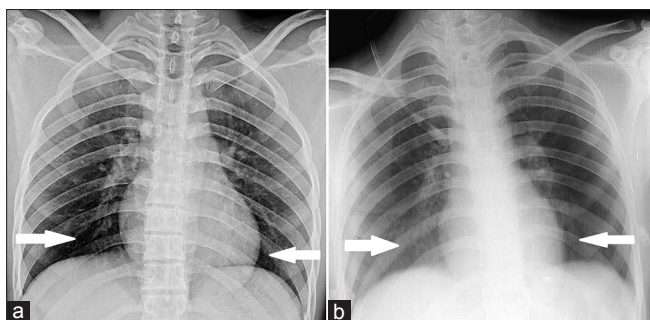
Departments of Orthopaedics, Ganga Hospital, Coimbatore, Tamil Nadu, India

**Address for correspondence:** Prof. S Rajasekaran,  
Chief of Orthopaedics and Spine Surgery, Ganga Medical Centre and Hospital,  
#313, Mettupalayam Road, Coimbatore - 641 043, Tamil Nadu, India.  
E-mail: rajasekaran.orth@gmail.com

Access this article online	
Quick Response Code:	Website: www.ijonline.com
	DOI: 10.4103/0019-5413.125527



**Figure 1:** (a) Radiograph of leg bones with ankle joint (anteroposterior views) showing fractures in both legs (b and c) T2W magnetic resonance imaging of the brain (arrow) showing multiple well defined tiny hyperintense lesions suggestive of cerebral fat embolism (arrow)



**Figure 2:** (a) Radiograph of chest, which was normal initially; (b) Bilateral diffuse haziness after 3 days (arrow)

as slurred speech, poor cognition and disturbed memory. GCS had improved to 13/15 and ventilator support was gradually weaned and withdrawn at 3 weeks. Later at 4 weeks (since injury), external fixator removal and interlocking nailing was carried out for fractures of both the tibiae. At 10 weeks postinjury, patient was conscious and oriented, but with poor cognition. At 5 months, patient had regained full neurological recovery and fractures of both bones of both the legs united [Figure 3]. Neurological recovery was evaluated by Glasgow outcome scale (GOS)<sup>7</sup> and mini-mental state examination (MMSE),<sup>8</sup> which showed good recovery and normal cognition respectively. MRI of the brain repeated at 10 months postinjury revealed resolution of previously visualized hyperintense lesions except in the periventricular region without any diffusion restriction pattern [Figure 3].

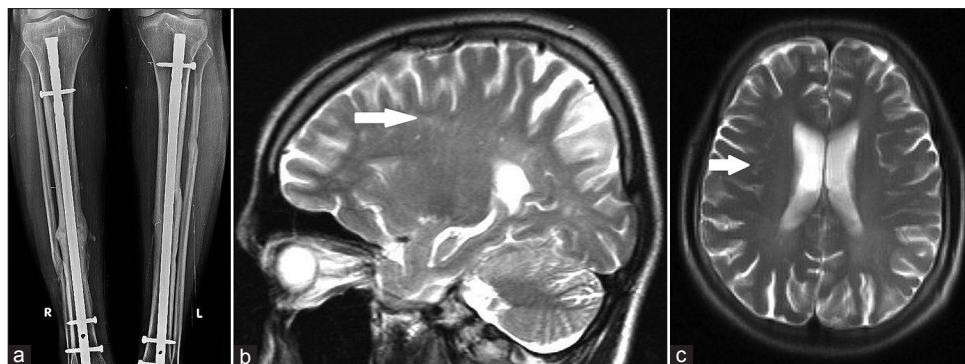
### Case 2

A 28 year old male presented with RTA and sustained closed fracture of the right femur. He was admitted in the evening at 6 pm and was planned for interlocking nailing the following day. He had no other injuries and was fully conscious at admission. Next day morning at 7 am, patient was found to be drowsy and CT of the brain was carried out, which was reported to be normal. The pulse rate was 114/min, blood pressure was 122/84 mmHg with an oxygen saturation of 86% at room air. Within 3 h, consciousness of patient rapidly deteriorated with the GCS falling to 7/15 and he required

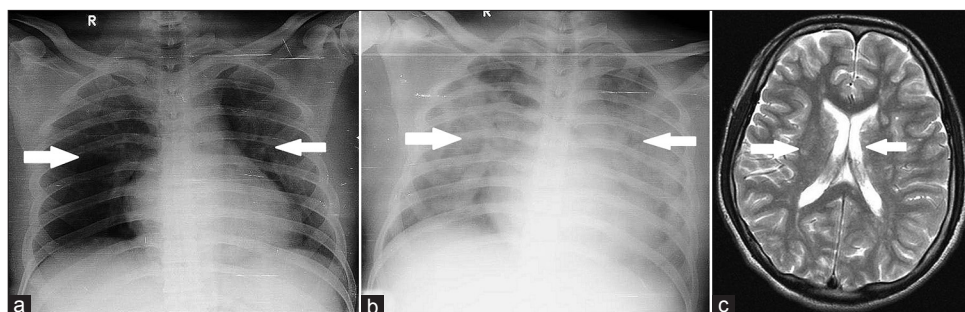
intubation and ventilation to maintain oxygen saturation. Clinically, a diagnosis of fat embolism syndrome was made after ruling out head injury, hypotension, electrolyte and metabolic disturbances. The fracture was then stabilized by an external fixator on the 2<sup>nd</sup> day after injury. Chest X-ray, was initially normal and showed bilateral diffuse haziness after 2 days [Figure 4]. Since consciousness did not improve even after 6 days, MRI of the brain was done, which confirmed cerebral fat embolism [Figure 4]. As there was continued requirement of mechanical ventilation with positive end expiratory pressure, tracheostomy was done. Mechanical ventilation was continued for 5 weeks until he regained consciousness with the GCS improving to 11/15. Gradual weaning was carried out with T-piece and ventilation support was discontinued at 6 weeks. External fixator removal and interlocking nailing was carried out for fracture femur at 8 weeks since injury. Neurologically, patient had poor cognition and spasticity initially, which gradually improved and the patient returned to his original job. At 6 months, postinjury the patient had good neurological recovery (GOS) and normal cognition (MMSE).

### DISCUSSION

Gurd and Wilson<sup>9</sup> reported that fat embolism syndrome typically develops between 12 h and 72 h after the injury in young adults. This was seen in our cases also where they were completely normal neurologically at presentation and rapidly deteriorated in the next 9-12 h. Diagnosis of fat embolism syndrome is by and large clinical and is characterized by the classical triad of petechial rash, respiratory distress and neurological dysfunction.<sup>9</sup> However, this triad may not be present in all patients and poses a diagnostic challenge.<sup>10</sup> Both our cases had profound neurological dysfunction at presentation, but had no petechial rash. Although they had no respiratory distress at presentation, dysfunction was manifested by worsening hypoxia detected by pulse oxymetry. Cases where the neurological manifestations are predominant are referred to as cerebral fat embolism syndrome.<sup>5,11</sup> Cerebral



**Figure 3:** (a) Radiograph of leg bones (anteroposterior views) showing well united fractures of both legs; (b and c) T2W magnetic resonance imaging of brain repeated 10 months postinjury shows incomplete, but significant resolution of previous hyperintense lesions (arrow)



**Figure 4:** (a) Initial radiograph of chest; (b) Radiograph of chest repeated after 2 days reveals diffuse haziness (arrow) compared to initial radiograph; (arrow) (c) Magnetic resonance imaging of brain shows features of cerebral fat embolism (arrow)

manifestations are highly variable and nonspecific. This includes headache, lethargy, irritability, delirium, stupor, convulsions, focal deficits or coma.<sup>11</sup> These features may be seen even with head injury, substance abuse, polytrauma and sedative medication, making the diagnosis of cerebral fat embolism difficult.<sup>12</sup>

Cerebral fat embolism has been reported in young adults between 18 and 39 years.<sup>5,6,10,12-21</sup> The two patients, we report here are also in the same age group. Although, neurological deterioration in many reported patients was postoperative following intramedullary nailing for long bone fractures;<sup>5,6,10,13-16</sup> onset prior to surgery has also been reported as seen in our patients.<sup>10,12,17-20</sup> MRI is helpful in diagnosis of cerebral fat embolism and also to exclude other causes of deterioration.<sup>12,17,21</sup> Parizel *et al.*<sup>19</sup> reported that diffusion weighted MRI characterized by “starfield” pattern – bright spots on a dark background helps in early diagnosis. In the cases reported in literature, the duration of ventilatory support ranged up to a maximum of 3 weeks, but our patients required prolonged ventilation support for 3 and 6 weeks respectively. Butteriss *et al.*<sup>13</sup> emphasized the role of neurotoxicity and Metting *et al.*<sup>21</sup> highlighted the occurrence of delayed coma due to cerebral fat embolism in association with head injury. Complete neurological recovery has been reported in many case reports at 3 weeks to 4 months after the initial insult. Our two patients also had delayed, but complete

recovery after 5 and 6 months respectively. Manousakis *et al.*<sup>20</sup> studied the cognitive outcome in cerebral fat embolism and reported that neuropsychological evaluation was normal except for borderline frontal dysfunction at the end of 4 months. Pfeffer and Heran<sup>14</sup> although reported poor outcome in cerebral fat embolism associated with restricted diffusion in MRI, there was clear evidence of intraoperative hypoxia and hypotension in their cases, which might have contributed to the poor outcome. Metting *et al.*<sup>21</sup> reported persistent cognitive dysfunction in patient with cerebral fat embolism associated with head injury. Mueller *et al.*<sup>15</sup> reported poor outcome in fulminant cerebral fat embolism associated with atrial septal defect.

Early suspicion of fat embolism syndrome should be raised when there are subtle changes in consciousness, tachycardia, tachypnea and evidence of hypoxemia picked up by pulse oxymetry for early suspicion. Cytological examination of urine for fat globules is not sensitive and its absence does not rule out fat embolism syndrome as was seen in our patients.<sup>22</sup> Dongfeng *et al.*,<sup>23</sup> in a retrospective multicenter study, emphasized early diagnosis for good outcome in cerebral fat embolism.

Treatment of cerebral fat embolism syndrome is essentially supportive.<sup>16</sup> Cerebral edema plays a major part in neurological deterioration in fulminant type of cerebral



fat embolism syndrome.<sup>6</sup> Neurological manifestations in fat embolism syndrome can be worsened by associated primary head injury or secondary brain damage due to cerebral hypoxia, which may occur due to acute respiratory distress syndrome or low GCS.

Meyer *et al.*<sup>5</sup> has reported that any intention to withdraw supportive measures must be tempered until the patient is at least 1 month from the date of injury and the brain magnetic resonance image shows no sign of improvement. However in one of our patient, ventilation was required for 42 days and finally the patient recovered completely. This proves that there is no limit for supportive treatment in cerebral fat embolism syndrome considering the excellent prognosis. The cognitive dysfunction following cerebral fat embolism is reported to be similar to hypoxic brain injury,<sup>20,24</sup> which if avoided during management has excellent outcome.

Cerebral fat embolism syndrome has to be strongly considered in young adults with long bone and pelvic fractures presenting with rapid deterioration of neurological status in the absence of head injury. It cannot be ruled out even if associated with severe head injury. Magnetic resonance imaging of the brain is helpful for early diagnosis in isolated cerebral fat embolism. Importance of its early recognition lies in the fact that despite grave presentation, rapid worsening and late neurological recovery; the prognosis is very good with intensive care and rehabilitation. Prevention of secondary brain damage due to hypoxia is essential to avoid permanent neurological sequelae.

## REFERENCES

- Bhaskaran CS. Bone marrow embolism in traumatic death. *Pathol Microbiol (Basel)* 1969;34:105-11.
- Bulger EM, Smith DG, Maier RV, Jurkovich GJ. Fat embolism syndrome. A 10-year review. *Arch Surg* 1997;132:435-9.
- Stein PD, Yaekoub AY, Matta F, Kleerekoper M. Fat embolism syndrome. *Am J Med Sci* 2008;336:472-7.
- Ten Duis HJ. The fat embolism syndrome. *Injury* 1997;28:77-85.
- Meyer N, Pennington WT, Dewitt D, Schmeling GJ. Isolated cerebral fat emboli syndrome in multiply injured patients: A review of three cases and the literature. *J Trauma* 2007;63:1395-402.
- Gregorakos L, Sakayianni K, Hroni D, Harizopoulou V, Markou N, Georgiadou F, *et al.* Prolonged coma due to cerebral fat embolism: Report of two cases. *J Accid Emerg Med* 2000;17:144-6.
- Jennett B, Bond M. Assessment of outcome after severe brain damage. *Lancet* 1975;1:480-4.
- Folstein MF, Folstein SE, McHugh PR. "Mini-mental state". A practical method for grading the cognitive state of patients for the clinician. *J Psychiatr Res* 1975;12:189-98.
- Gurd AR, Wilson RI. The fat embolism syndrome. *J Bone Joint Surg Br* 1974;56B:408-16.
- Gupta B, Kaur M, D'souza N, Dey CK, Shende S, Kumar A, *et al.* Cerebral fat embolism: A diagnostic challenge. *Saudi J Anaesth* 2011;5:348-52.
- Jacobson DM, Terrence CF, Reinmuth OM. The neurologic manifestations of fat embolism. *Neurology* 1986;36:847-51.
- Yildiz OK, Delice A, Oztoprak I, Gurelik M, Yildirim A, Bolayir E, *et al.* Cerebral fat embolism in the absence of systemic manifestations of fat embolism syndrome. *Turkiye Klinikleri Journal of Neurology* 2010;5:19-23.
- Butteriss DJ, Mahad D, Soh C, Walls T, Weir D, Birchall D. Reversible cytotoxic cerebral edema in cerebral fat embolism. *AJNR Am J Neuroradiol* 2006;27:620-3.
- Pfeffer G, Heran MK. Restricted diffusion and poor clinical outcome in cerebral fat embolism syndrome. *Can J Neurol Sci* 2010;37:128-30.
- Mueller F, Pfeifer C, Kinner B, Englert C, Nerlich M, Neumann C. Posttraumatic fulminant paradoxical fat embolism syndrome in conjunction with asymptomatic atrial septal defect: A case report and review of the literature. *J Med Case Rep* 2011;5:142.
- Buskens CJ, Gratama JW, Hogervorst M, van Leeuwen RB, Rommes JH, Spronk PE. Encephalopathy and MRI abnormalities in fat embolism syndrome: A case report. *Med Sci Monit* 2008;14:CS125-9.
- Leiva Salinas C, Poyatos Ruipérez C, González Masegosa A, Ferrer Casanova JM. Diffusion-weighted MRI in early diagnosis of cerebral fat embolism syndrome. *Neurologia* 2008;23:188-91.
- Kim KC, Hwang DS, Shin HD. Posttraumatic cerebral fat embolism prior to operative repair of femoral and tibial fractures. *Orthopedics* 2008;31:170.
- Parizel PM, Demey HE, Veeckmans G, Verstreken F, Cras P, Jorens PG, *et al.* Early diagnosis of cerebral fat embolism syndrome by diffusion-weighted MRI (starfield pattern). *Stroke* 2001;32:2942-4.
- Manousakis G, Han DY, Backonja M. Cognitive outcome of cerebral fat embolism. *J Stroke Cerebrovasc Dis* 2012;21:906.e1-3.
- Metting Z, Rödiger LA, Regtien JG, van der Naalt J. Delayed coma in head injury: Consider cerebral fat embolism. *Clin Neurol Neurosurg* 2009;111:597-600.
- Shaikh N. Emergency management of fat embolism syndrome. *J Emerg Trauma Shock* 2009;2:29-33.
- Dongfeng C, Jian P, Xuejun F. Early diagnosis and prognosis in cerebral fat embolism syndrome. *China J Mod Med* 2004;14:95-7.
- Gray AC, Torrens L, White TO, Carson A, Robinson CM. The cognitive effects of fat embolus syndrome following an isolated femoral shaft fracture. A case report. *J Bone Joint Surg Am* 2007;89:1092-6.

**How to cite this article:** Srikanth KP, Sundararajan SR, Rajasekaran S. Late recovery in cerebral fat embolism. *Indian J Orthop* 2014;48:100-3.

**Source of Support:** Ganga Orthopaedic Research and Education Foundation, **Conflict of Interest:** None.