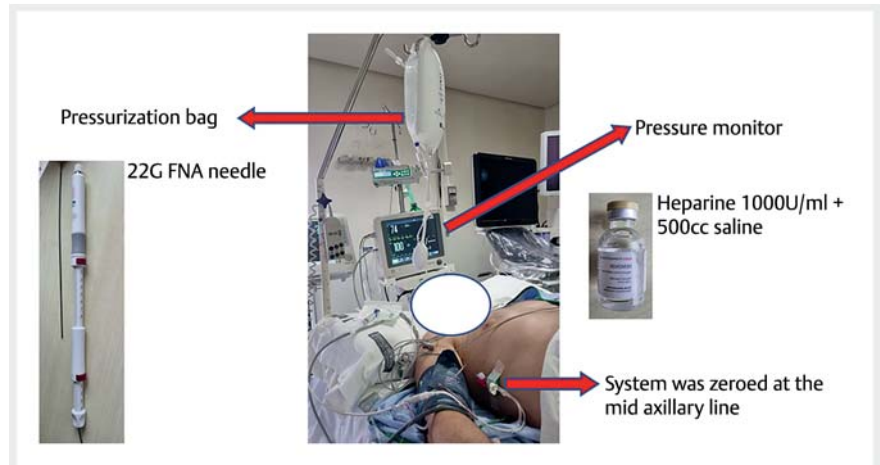


Endoscopic ultrasound-guided portal pressure gradient measurement

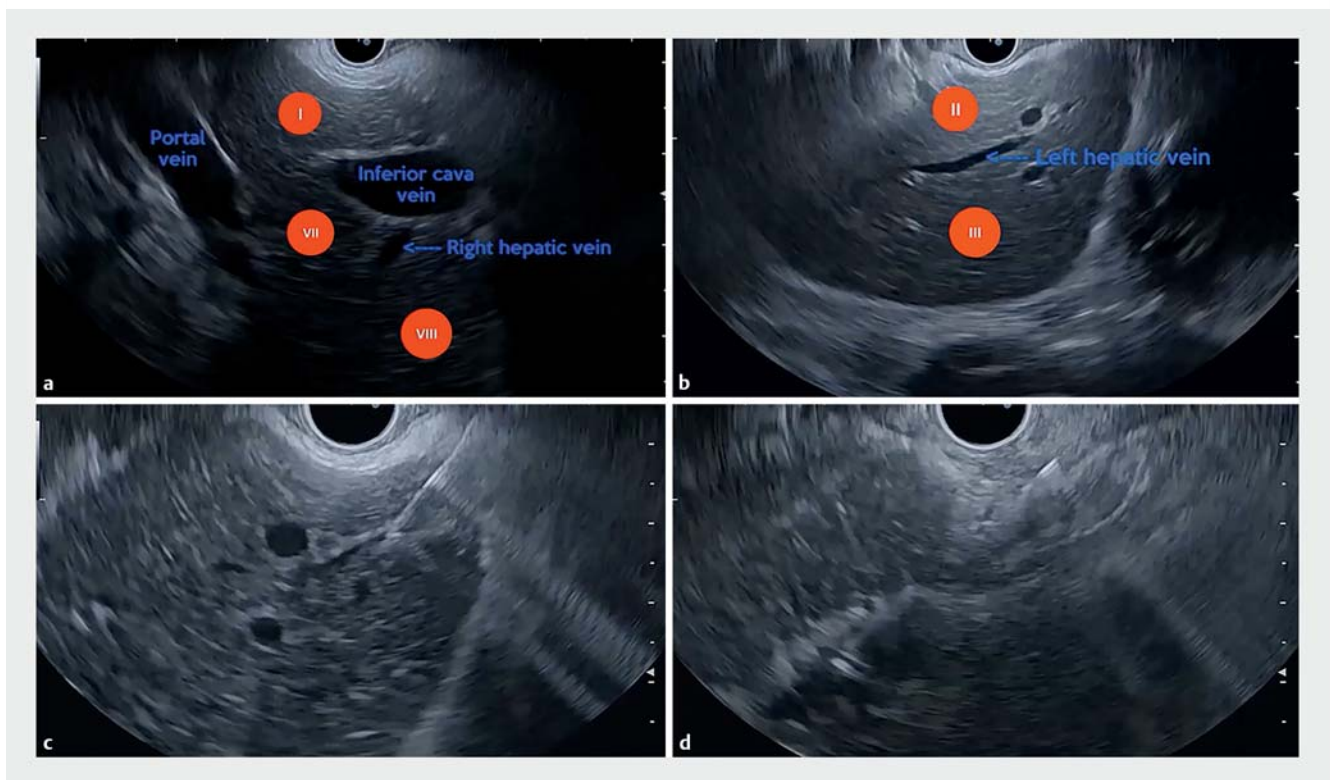
OPEN
ACCESS

A 55-year-old man with a past medical history of chronic liver disease and small esophageal varices on upper gastrointestinal endoscopy underwent endoscopic ultrasound-guided portal pressure gradient (EUS-PPG) measurement.

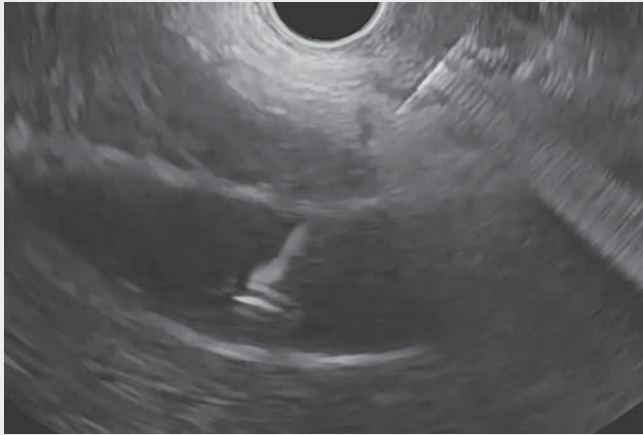
The materials that were used to perform the procedure were: a pressure monitor, a pressurization bag, a 22G fine-needle aspiration (FNA) needle, and heparinized saline. The system was zeroed at the right mid-axillary line (► **Fig. 1**). A curvilinear array echoendoscope (GF-UCT180, Olympus, Tokyo, Japan) that allowed color Doppler imaging was placed in the stomach to visualize the hepatic vascular anatomy.



► **Fig. 1** The equipment and materials that were used in endoscopic ultrasound-guided portal pressure gradient (EUS-PPG) measurement. FNA, fine-needle aspiration.



► **Fig. 2** Endoscopic ultrasound images showing: **a** identification of the main hepatic landmarks, namely the portal vein and inferior vena cava, with the liver segments marked in red circles; **b** identification of the left hepatic vein; **c** puncture of the left hepatic vein with a 22G fine-needle aspiration (FNA) needle; **d** puncture of the portal vein with a 22G FNA needle.



▶ Video 1 An endoscopic ultrasound-guided portal pressure gradient (PPG) measurement is performed, with identification of the hepatic landmarks, puncture of the left hepatic vein (or inferior vena cava as an alternative) and portal vein, giving a PPG of 19 mmHg, which represents portal hypertension.

The primary step in the technique for EUS-PPG measurement is to identify the liver landmarks: the inferior vena cava (IVC) and the portal vein. These landmarks allow the identification of the liver segments I, VII, and VIII (▶ **Fig. 2a**). Following this, a counterclockwise movement must be made with the endoscope to identify the left hepatic vein (LHV), which is another important landmark in recognizing segments II and III, which are seen above and below the LHV, respectively (▶ **Fig. 2b**).

The LHV is the initial structure in which the puncture must be performed. It is punctured with a 22G FNA needle (▶ **Fig. 2c**), and 1 mL of heparinized saline is flushed into the vein, with the pressure being observed on the monitor. An alternative when puncture of the LHV is not possible is puncture of the IVC, which theoretically is more accessible because of its larger size. Lastly, it is necessary to search for the portal vein, which has a fish-eye appearance. The portal vein is another important landmark in identifying liver segments III and IVb. The technique of portal vein puncture (▶ **Fig. 2d**) is the same as for the LHV and IVC.

It is essential to note that three punctures with three measurements should be performed in each vein (three in the LHV or IVC and three in the portal vein) (▶ **Video 1**). To calculate the pressure in each vein, it is necessary to take the mean of the values for that vein. The PPG is the result of the difference between the pressure of the LHV or IVC and the pressure in the portal vein.

Currently, the hepatic venous pressure gradient (HVPG) measurement is the main option for determining portal pressure [1], but it is indirect and the method is not free of complications. In contrast, EUS-PPG is a direct measurement and the results are similar to those for HVPG, with excellent consistency between the methods [2, 3]. The use of the 22G FNA needle seems safer than the use of a 25G FNA needle, which other authors have used.

Endoscopy_UCTN_Code_TTT_1AS_2AG

Competing interests

The authors declare that they have no conflict of interest.

The authors

Edson Guzmán-Calderón^{1,2,3}, Belén Martínez-Moreno⁴, José Ramón Aparicio⁴

- 1 Gastroenterology Unit, Hospital Nacional Edgardo Rebagliati Martins, Lima, Peru
- 2 Universidad Peruana de Ciencias Aplicadas (UPC), Lima, Peru
- 3 Gastroenterology Unit, Angloamericana Clinic, Lima, Peru
- 4 Gastroenterology Unit, Hospital General Universitario de Alicante, Alicante, Spain

Corresponding author

Gerly Edson Guzmán-Calderón, MD

Hospital Nacional Edgardo Rebagliati Martins, Av. Edgardo Rebagliati s/n – Jesús María, Lima, Perú
edson_guzman@hotmail.com

References

- [1] d'Amico G, Morabito A, D'Amico M et al. New concepts on the clinical course and stratification of compensated and decompensated cirrhosis. *Hepatology* 2018; 12: 34–43
- [2] Zhang W, Peng C, Zhang S et al. EUS-guided portal pressure gradient measurement in patients with acute or subacute portal hypertension. *Gastrointest Endosc* 2021; 93: 565–572
- [3] Huang J, Samarasekera J, Tsujino T et al. EUS-guided portal pressure gradient measurement with a simple novel device – a human pilot study. *Gastrointest Endosc* 2017; 85: 996–1001

Bibliography

Endoscopy 2022; 54: E1009–E1010

DOI 10.1055/a-1909-1515

ISSN 0013-726X

published online 24.8.2022

© 2022. The Author(s).

This is an open access article published by Thieme under the terms of the Creative Commons Attribution-NonDerivative-NonCommercial License, permitting copying and reproduction so long as the original work is given appropriate credit. Contents may not be used for commercial purposes, or adapted, remixed, transformed or built upon. (<https://creativecommons.org/licenses/by-nc-nd/4.0/>)

Georg Thieme Verlag KG, Rüdigerstraße 14, 70469 Stuttgart, Germany

