

An Observational Study of Mucocutaneous Manifestations among SARS-CoV-2 Patients from Three COVID-19 Dedicated Tertiary Care Centers

Abstract

Introduction: Ever since the outbreak of COVID-19, the respiratory system has been the chief focus of researches, however, understanding the impact of this disease on the integumentary system is just as essential. **Objectives:** We aimed at collecting data on any cutaneous manifestation arising in patients with active and recovering COVID-19 infection, or a direct consequence of the infection's treatment, and correlating these findings with systemic disease severity and duration. **Materials and Methods:** A prospective observational study was conducted in three tertiary care centers from Rajasthan, India, to acquire data of laboratory-confirmed cases of COVID-19 presenting with any mucocutaneous manifestation. **Results:** Eight predominant patterns of dermatological involvement were seen, namely, maculopapular (14.59%), urticarial (13.17%), pernioic (12.1%), pityriasis rosea (11.74%), acral erythema/edema (10.3%), petechial (4.63%), vesicular (2.49%), and livedo (1.78%). Rare findings included eruptive pseudoangioma, eruptive hypomelanosis, alopecia parvimaclata, geographic tongue, chikungunya-like hyperpigmentation, and nail changes. On correlating these findings with the gradient of the disease, livedo, vasculitis, exfoliation, and erythroderma were associated with severe disease, whereas perniosis and eruptive pseudoangioma were seen in mild illness. **Conclusion:** We reported a few previously unpublished skin manifestations of COVID-19, namely, geographic tongue, chikungunya-like pigmentation, eruptive hypomelanosis, and alopecia parvimaclata. This study provides a visual description of the muco-cutaneous manifestations of COVID-19 disease which could aid a dermatologist or physician in early diagnosis of this novel infection, especially in a resource-poor setting.

Keywords: Corona virus, COVID-19, cutaneous manifestations, mucocutaneous manifestations, SARS-CoV-2

Introduction

Ever since the outbreak started in Wuhan, China in November 2019 the cases of COVID-19 or SARS-CoV-2 (severe acute respiratory syndrome coronavirus 2) have been rising at an explosive rate.^[1] Owing to a very high secondary infection rate coupled with the largely asymptomatic transmission, the virus rapidly spread across the world and gained the title of a pandemic on 11th March 2020 by the World Health Organization (WHO).^[2] By the beginning of September 2020, India was the second-worst hit country in the world with COVID-19.^[3]

Of late, several authors have reported various cutaneous manifestations in the setting of COVID-19 infection, and these

myriad presentations of COVID-19 related lesions have a broad and current interest.^[4]

In this study, we aimed at collecting data on any cutaneous manifestation arising in patients with active and recovering COVID-19 infection, or a direct consequence of the infection's treatment, and correlating these findings with systemic disease severity and duration, from three tertiary care centers in Rajasthan, India.

Materials and Methods

This prospective multi-centric study was initiated after obtaining due approval from institutional ethical board (F/SPMC/IERB/2061) and conducted at three tertiary care centers from Rajasthan, India, namely Bikaner, Kota, and Jodhpur,

Alpana Mohta,
Achala Mohta¹,
Radhe Shyam Nai,
Aakanksha Arora,
Suresh Kumar
Jain²,
Alok Mohta³,
Rajesh Dutt Mehta,
Bhikam
Chand Ghiya,
Vijeta Prasad,
Rajesh Khokhar,
Rajat Toteja³,
Gaurav Bha`rgava⁴

Departments of Dermatology, Venereology and Leprosy and ¹Preventive and Social Medicine, Sardar Patel Medical College, Bikaner; ²Departments of Dermatology, Venereology and Leprosy and ⁴General Medicine, Government Medical College, Kota, ³Department of General Medicine, Sampurnanand Medical College, Jodhpur, Rajasthan, India

Address for correspondence:

Dr. Alpana Mohta,
Senior Resident, Department
of Dermatology, Venereology
and Leprosy, Sardar
Patel Medical College,
Bikaner - 334 001, Rajasthan,
India.
E-mail: dralpanamohta10@
gmail.com

Access this article online

Website: www.idoj.in

DOI: 10.4103/idoj.IDOJ_127_21

Quick Response Code:



This is an open access journal, and articles are distributed under the terms of the Creative Commons Attribution-NonCommercial-ShareAlike 4.0 License, which allows others to remix, tweak, and build upon the work non-commercially, as long as appropriate credit is given and the new creations are licensed under the identical terms.

For reprints contact: WKHLRPMedknow_reprints@wolterskluwer.com

How to cite this article: Mohta A, Mohta A, Nai RS, Arora A, Jain SK, Mohta A, *et al.* An observational study of mucocutaneous manifestations among SARS-CoV-2 patients from three COVID-19 dedicated tertiary care centers. Indian Dermatol Online J 2021;12:687-95.

Received: 03-Mar-2021. **Revised:** 17-Apr-2021.
Accepted: 20-Jul-2021. **Published:** 10-Sep-2021.

over 6 months from June 2020 to November 2020 in patients with confirmed present or past COVID-19 infection according to reverse transcription polymerase chain reaction (RT-PCR). The patients were divided into two groups, namely A (acute viral infection) and B (recovering phase within 2 months after the subsidence of fever). The patients were recruited from both COVID-19-dedicated in-patient facility and general out-patient department (OPD). However, every time a patient, with high clinical suspicion of active infection, presented to our OPD the diagnosis was established by RT-PCR. In group A, the duration of viral illness was determined by a negative RT-PCR at the end of the infection.

All patient-related data were entered into a proforma and a printed questionnaire (designed specifically to categorize the skin manifestations according to various other authors' reports). Clinical photographs were clicked for as many patients as possible. All clinical images were independently analyzed by three senior dermatologists, and a diagnosis of cutaneous ailment was made according to a common consensus.

Results

During the study period, 281 patients of confirmed COVID-19, having muco-cutaneous manifestations, were identified by us. While 163 patients were of active COVID-19 (group A), the remaining 118 were in recovery (group B).

Eight predominant patterns of dermatological involvement were seen, namely, maculopapular (14.59%), urticarial (13.17%), pernioitic (12.1%), pityriasis rosea (11.74%), acral erythema/edema (10.3%), petechial (4.63%), vesicular (2.49%), and livedo (1.78%) along with some miscellaneous findings. We also identified some novel, previously unpublished nail changes in patients with COVID-19. The clinical patterns identified by us in both the groups have been tabulated [Table 1].

Detailed analysis of cutaneous lesions

A thorough analysis revealed some subtle associations between various systemic manifestations and cutaneous eruptions in study subjects.

1. Maculopapular rash (MP rash) (n = 41; 14.59%) was our most common finding seen frequently during the early stage of active disease. The trunk was the most commonly involved site (n = 22). Six patients also had oral lesions. MP rash was associated with severe illness (n = 12; 29.3%) and a mortality rate of 9.6%.
2. Urticaria and angioedema (n = 37; 13.17%) were seen both in early (n = 24 in group A) and recovery (n = 13 in group B) phases [Figure 1]. The most common pattern was generalized urticaria (43.2%). In group A, eruptions were short-lasting (average duration

Table 1: Muco-cutaneous manifestations in groups A and B

GROUP A	GROUP B
DERMATOSIS	DERMATOSIS
Maculo-papular eruptions	Urticaria
Urticaria/angioedema/ urticarial vasculitis	Perniosis
Pernioitic lesions	Maculo-papular eruptions
Acral edema/erythema	Pityriasis rosea
Pityriasis rosea	Acneform eruptions
Exfoliative lesions	Acral/periungual exfoliation
Petechial lesions	Allergic contact dermatitis-like lesions
Erythroderma	Chikungunya-like hyperpigmentation
Vesicular eruptions	Eruptive Hypomelanosis
Erythema multiformae	Alopecia Parvimaclata
Eruptive pseudoangioma	Nail involvement
Livedo reticularis/racemosa	
Geographic tongue	
Kawasaki-like exfoliation	
Nail involvement	
Mucosal lesions	

- 14.3 days). In group B, three patients developed chronic urticaria (>6 weeks). A positive history of drug consumption before onset was present in 14 (37.84%) patients. The lesions were associated with moderate to severe disease in 45.83% of the cases.
3. Perniosis or pseudo-chilblains (n = 34, 12.1%) was commonly seen in patients during the latter half of their active infection, lasting for a mean duration of 18.6 days before resolving on their own [Figure 2a and b]. The majority of patients were either asymptomatic or had mild flu-like symptoms only. Only 2 (5.9%) of these patients had a previous history of pernioitic. Variants of pernioitic reported by us have been mentioned in Table 2.
 4. Pityriasis rosea (n = 33; 11.74%): In 33 patients, there was the development of pityriasis rosea (PR)-like lesions (n = 11 in group A and n = 22 in group B). The lesions were different from typical PR by the absence of herald patch in more than half of the patients (n = 20), presence of pruritus, and involvement of atypical sites such as flexures and limbs.
 5. Acral edema/erythema (n = 29; 10.32%) was seen exclusively in the active phase of infection. However, no definite correlation could be made regarding disease duration or severity. Twelve (41.4%) patients had erythromelalgia of the palms/soles.
 6. Petechiae/purpura (n = 13; 4.63%) was encountered only in group A, with mucosal involvement in four patients [Figure 3a-c]. Eight of these patients were admitted to ICU. Four of these patients had cutaneous vasculitis.

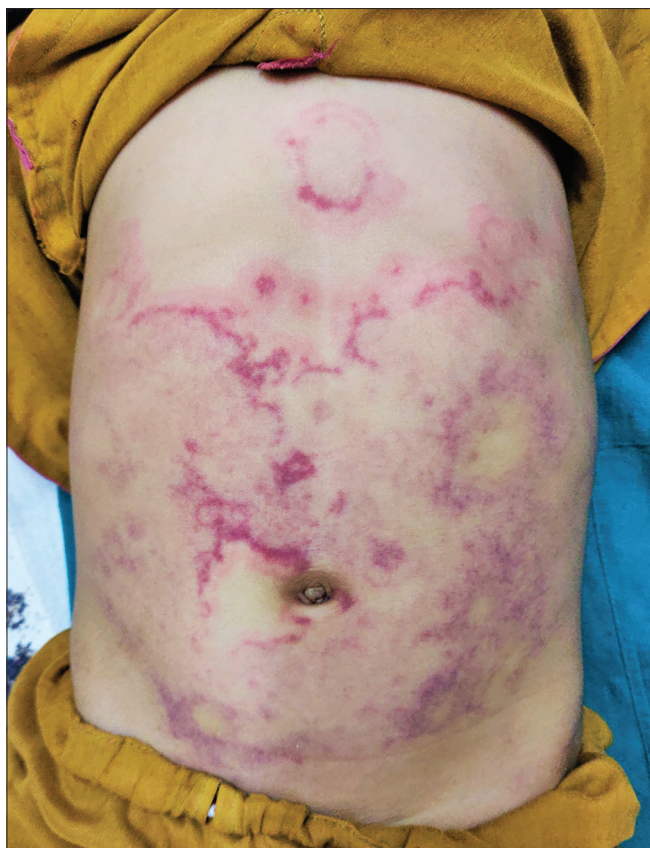

Figure 1: Urticarial vasculitis associated with MIS-C

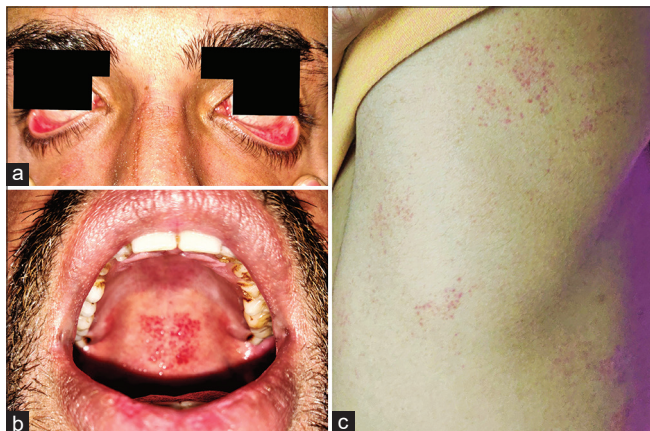

Figure 3: Punctate purpura in group A on (a) palpebral conjunctiva, (b) hard palate, (c) back

7. Vesicular eruptions (n = 7; 2.49%) were monomorphic in all the patients and seen only in the active disease. They usually occurred late during the course of severe disease (latency period 16.3 days). Seen transiently and lasting for an average of 7.1 days, the lesions were associated with severe illness. All patients documented by us were over 50 years of age (mean age 63.8 years) and admitted in the intensive care unit [Figure 4a-d].
8. Livedo reticularis/racemosa (n = 5; 1.78%) was also present only during active infection in severely ill patients, seen during the latter half of illness

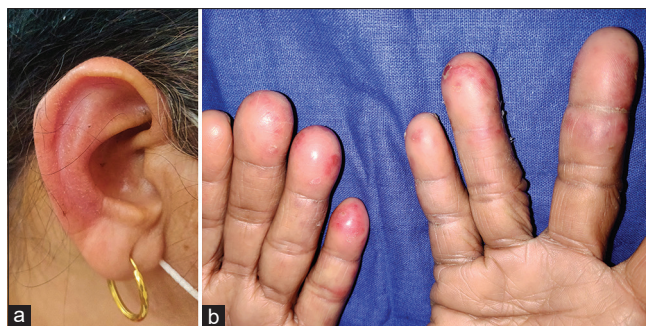


Figure 2: Pseudo-chilblains with (a) ear lobe pernio, (b) petechiae with edema, pseudovesicles, and exfoliation

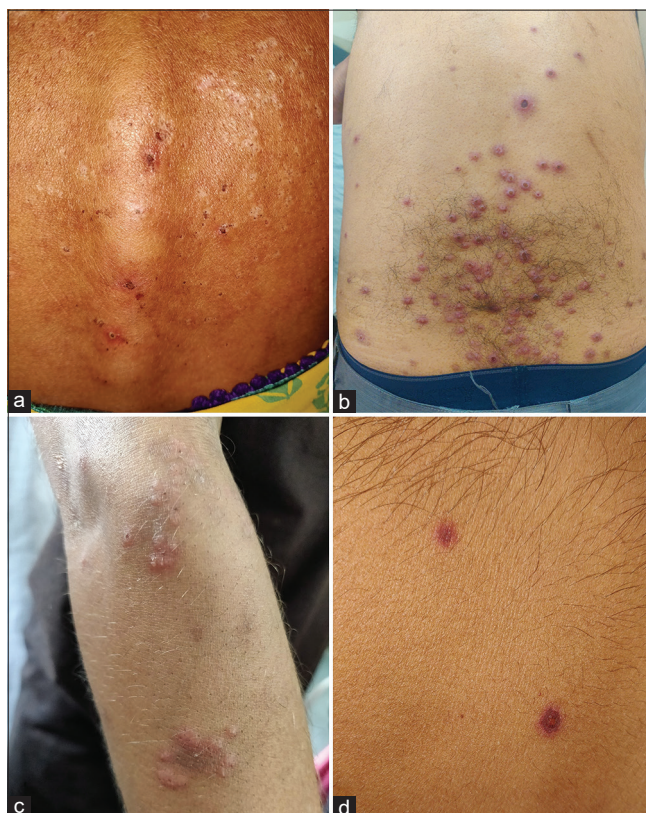


Figure 4: Vesicular eruptions resembling (a) erythema multiforme of the trunk, (b) erythema multiforme of trunk, (c) erythema multiforme of extensors, (d) flat targetoid eruptions

[Figure 5a and b]. Four (80%) patients were hospitalized in ICU and treated with enoxaparin. D-dimer levels were raised in all five. The mortality rate was 20% (n = 1).

9. Miscellaneous mucocutaneous changes
 - Nail changes: The patients in group A presented with nail cyanosis, red lunula, erythronychia, periungual petechial, apparent total leukonychia, and periungual exfoliation. Whereas punctate leukonychia, total leukonychia, onychomadesis, onychoschizia, onycholysis, trachyonychia, beau lines, pitting, and melanonychia were present in group B patients.
 - Acral exfoliation (n = 10, 3.55%) was seen more commonly in the recovery phase.

Table 2: The pattern of disease in patients		
Mucocutaneous manifestation	Total no. of patients	Pattern
Maculo-papular eruptions	41	Trunk (53.7%) Flexures (26.8%) Generalized (12.2%) Acral (7.3%)
Urticaria/ angioedema/ urticarial vasculitis	37	DISTRIBUTION: Generalized (43.2%) Acral (27.1%) Flexural (24.3%) Mucosal (5.4%). VARIANTS: Urticarial vasculitis-11 Urticaria with angioedema-3 Angioedema-2 Urticarial vasculitis with multisystem inflammatory syndrome-2 Complaint of acute abdominal pain during episodes of acute urticaria-4.
Perniotic lesions	34	Localized finger/toe tip swelling/erythema (73.5%) vesicobullous eruptions (11.8%) digital tip petechiae (8.8%) erythema multiformae-like digital vesicles (5.9%). Earlobe perniosis (5.9%).
Pityriasis rosea	33	Truncal > acral > face > flexural > generalized
Acral edema/ erythema	29	Bilaterally symmetrical involvement of legs > hands (erythromelalgia of the palms/soles in 12 patients (41.4%)
Petechial lesions	13	Macular (62.3%) palpable purpura (37.7%) truncal (n=6) acral (n=7) Mucosal (conjunctival and oral) n=4
Vesicular eruptions	7	VARIANTS: Miliaria crystalline-like vesicles-3 (bilateral lower/upper limbs);targetoid (erythema multiformae-like lesions)-2 (bilateral palms and soles);

Table 2: Contd...		
Mucocutaneous manifestation	Total no. of patients	Pattern
		hemorrhagic varicella like lesions-1 (generalized); necrotic ulceration-1 (lower limbs). SITES: Acral (n=5; 71.4%), Head and neck (n=2; 28.6%).
Livedo	5	bilateral lower limbs, n=2; unilateral lower limb n=2; unilateral trunk=1
Eruptive pseudoangioma	6	Acral (50%) > face (40%) > truncal (10%)
Kawasaki-like exfoliation	3	generalized-2, acral-1; strawberry tongue-1
Erythroderma	2	Generalized exfoliative dermatitis (n=2)
Only mucosal lesions	6	Geographic tongue: 4; Hypertrophic candidiasis: 2

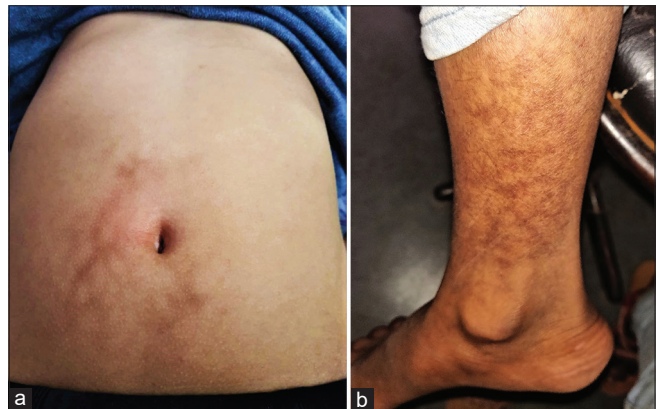


Figure 5: Unilateral livedo reticularis with (a) broken fishnet pattern involving the trunk, (b) the lower leg

- Allergic contact dermatitis-like lesions (n = 5, 1.78%) were also seen in on the palms and soles of the recovering patients.
- Kawasaki-like exfoliation (n = 3; 1.07%): Such lesions were seen only in pediatric patients during the latter half of active illness with, all three children admitted in ICU [Figure 6a-c]. Strawberry tongue was seen in one case [Figure 6b].
- Mucosal lesions were the only presenting feature in six cases, with four cases of geographic tongue, and two of oral hypertrophic candidiasis. Oral erosions, apthae, vesicles, and strawberry tongue were seen in patients along with other skin manifestations.
- Chikungunya-like hyperpigmentation was seen in one (0.36%) patient in the recovering stage of COVID-19, with the involvement of the dorsum of the hands [Figure 7]. The patient was being treated with injection remdesivir during active infection.

Contd...

- Eruptive pseudoangiomatosis (EP) (n = 6; 2.14%) was seen exclusively in the pediatric age group (mean age 13.2 years) during active infection. It was associated with a good prognosis [Figure 8a-c].
- Acneform eruptions (n = 34; 12.1%) were observed only in group B with a history of systemic steroids being used for the management of COVID-19 in all cases.
- Eruptive hypomelanosis was seen in five patients from three families during the recovery phase of their illness [Figure 9a and b].
- Erythroderma was seen in two patients from group A.
- Alopecia parvimaclata was seen in three patients from group B [Figure 10a and b].

On correlating the cutaneous features with the severity of the systemic disease, we found a linear correlation between increasing disease intensity (in terms of oxygen saturation, metabolic derangement, CT scan score, duration of hospital stay, the requirement of supplementary oxygen/intensive care) and some skin manifestations. [Figure 11].

Discussion

The pioneering original study concerning the classification of cutaneous manifestations of COVID-19 was conducted by Galván Casas *et al.*^[5] in form of a nationwide survey in Spain. Since then, many other authors have been tirelessly adding an ever so growing list of dermatoses found to be associated with this novel virus.^[5-12] However, despite the widespread prevalence of the illness in India, the data regarding its skin manifestations are sparse.

Even though the prognostic significance of these emerging skin lesions is yet to be verified, they might aid in diagnosis and any possible drug-related adverse events. But whether these muco-cutaneous features are a direct result of this novel viral infection or due to systemic deterioration, opportunistic infections, or adverse drug reactions is still a matter of debate.

Our study was carried out from the month of July 2020 to November 2020 when India was severely afflicted by COVID-19. Owing to such widespread demographic involvement of this illness in our country lately, we encountered quite a handful of patients with otherwise unexplainable mucocutaneous lesions.

Maculopapular eruptions

Maculopapular (MP) eruptions are perhaps the most widely reported cutaneous lesions within the spectrum of COVID-19 with a prevalence rate ranging from 5% to 70%.^[13,14] In our study, we observed some subtle differences in the etiology of these eruptions in different age groups. Although in pediatric patients, the rash was non-pruritic and seen at the same time as pyrexia, (group A), in adults MP

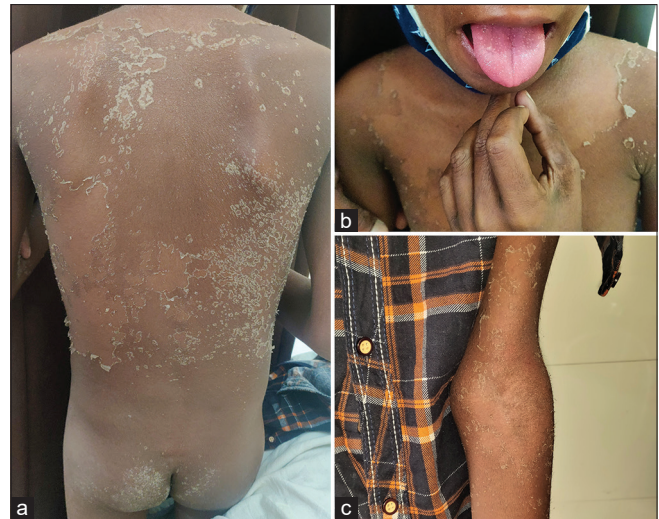

Figure 6: Kawasaki-like exfoliation on (a) back, (b) strawberry tongue, (c) flexural

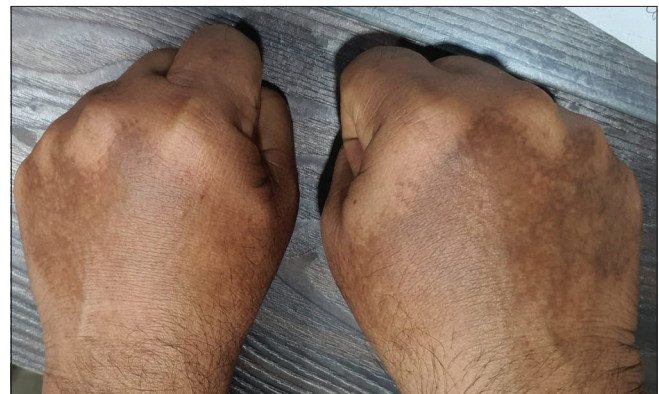

Figure 7: Chikungunya-like hyperpigmentation on the dorsum of the bilateral hands

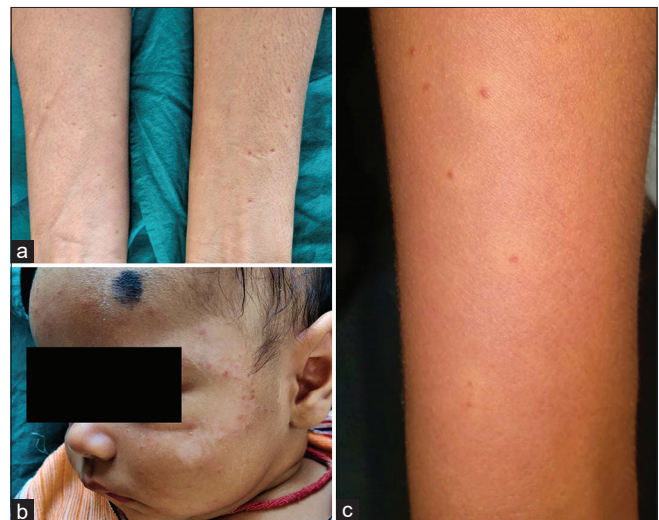

Figure 8: Eruptive pseudoangiomatosis in pediatric patients on (a) forearms, (b) face, (c) forearms

rash was pruritic and commonly seen during the recovery phase (group B). We hypothesize that in pediatric patients,

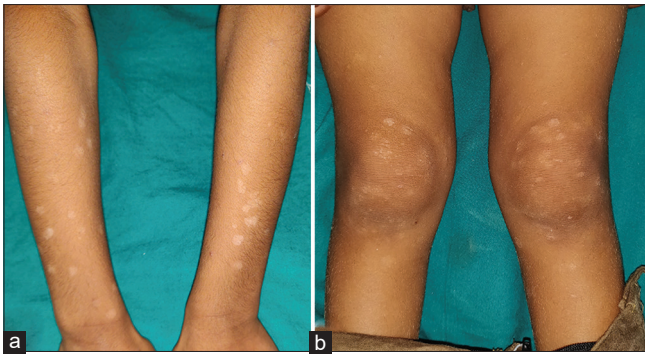

Figure 9: (a) Eruptive hypomelanosis in (b) a pediatric patient, and his sibling

MP rash was usually of viral origin, whereas in adults, these lesions were predominantly drug-induced.

The high hospital admission rate and mortality rate in these patients can perhaps be explained by the need for polypharmacy in the form of salvage drugs in critically ill cases, inducing MP rashes. Late-onset MP rash can be triggered from a hyperactive immune system.^[15]

Urticaria/Angioedema

Urticaria can be either idiopathic, viral, or drug-induced. There was a definitive history of drug consumption before the onset of lesions in at least 14 patients, namely, hydroxychloroquine, lopinavir, azithromycin, and remdesivir. We also encountered two pediatric patients having urticarial vasculitis with severe systemic involvement in the form of “multisystem inflammatory syndrome in children” (MIS-C) [Figure 1]. Although urticaria is associated with severe illness, their highly variable etiology has rendered them to be an inaccurate disease identification marker.

Perniosis or pseudo-chilblains

Classical lesions of perniosis/chilblains are associated with exposure of acral areas with cold temperatures, leading to deep dermal vessels' constriction and superficial plexus dilatation.^[16] A consistent correlation of pernioitic lesions with active COVID-19 infection has been established. The reported prevalence ranges from 14.3% to 72%.^[5,6,17,18] The clinico-epidemiological profile of the affected patients in our study (n = 35) was similar to most other reports in the past, with lesions appearing in younger patients, occurring late during active disease, having mild systemic features, and excellent prognosis. Vesico-bullous and erythema multiforame-like acral lesions carried a poor prognosis.

In our experience, these lesions are a strong indicator of active COVID-19. This study was conducted in the months of summer in India, where the temperature tends to get hot and arid in Rajasthan. The fact that pernioitic lesions were seen acutely in patients despite such high temperature, with a positive history of COVID-19, strongly favored

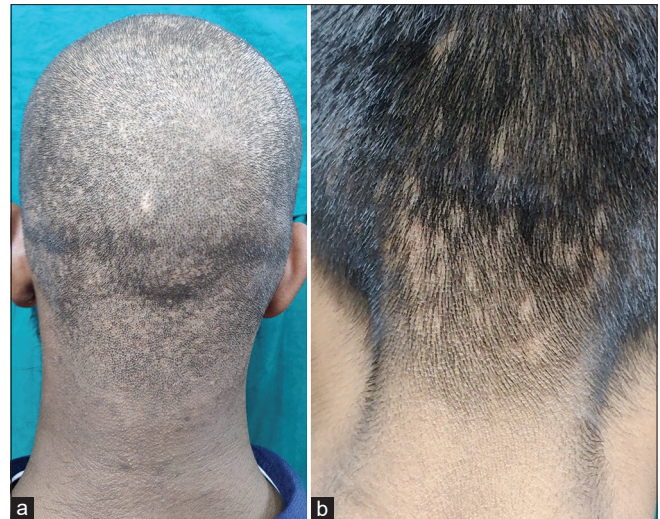

Figure 10: (a,b) Alopecia parvimaclata in two patients recovering from COVID-19 illness

viral origin. Negative history of similar lesions in the past in most patients also favors this temporal association. It has been hypothesized that microemboli lodgement in the peripheral dermal plexus led to endothelial injury and vascular inflammation.^[19]

Pityriasis rosea (PR)

The delayed onset of PR can be explained by the development of lymphopenia during the recovery phase according to Drago *et al.*^[20] This lymphopenia could play a role in the reactivation of latent *human herpesvirus 6* (HHV-6), *human herpesvirus 7* (HHV-7), *varicella-zoster virus*, and *Epstein-Barr virus* (EBV) virus.^[21-24]

Vesicular lesions

Vesicular eruptions are a sparsely reported entity in COVID-19, with an incidence rates of 3.77%–15%.^[13] Interestingly, we also encountered one patient with hemorrhagic vesicles distributed over the entire body, resembling varicella-zoster. However, unlike varicella, these lesions were monomorphic and lacked mucosal involvement. They are an indicator of severe illness. Criado *et al.*^[25] has hypothesized that these eruptions arise from cytokine storms in the skin, resulting in endothelial damage. These lesions are specific to COVID-19, and their identification could be a useful tool in aiding the diagnosis of early or ambiguous cases in a resource-poor setting.^[13]

Petechiae/purpura

Only a handful of case series have reported petechiae/purpura in COVID-19 cases.^[10,17,26] We found mucosal petechiae to be an indicator of severe illness. The underlying pathogenesis is a leukocytoclastic event resulting from pauci-immune prothrombotic vasculopathy,^[27] drug-induced, or secondary to infusion reaction.

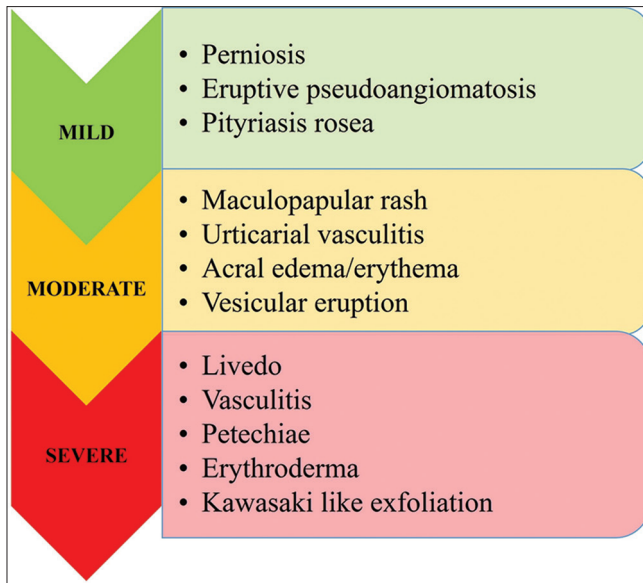


Figure 11: Categorization of dermatoses according to COVID-19 severity

Livedo Reticularis/racemosa

Livedo reticularis (LR), is a sign of severe systemic illness, consisting of a lacy hexagonal network of red to violaceous dusky patches encircling a pale center. Their likely cause in COVID-19 is the development of a procoagulant state with small vessel occlusion. The virus can also infect the angiotensin-converting enzyme 2-receptors on vascular endothelial and smooth muscle cells leading to low-grade vessel inflammation.^[28,29]

Erythroderma

Erythroderma (exfoliative dermatitis involving >90% BSA) is a reaction pattern secondary to myriad underlying ailments, including infection or drug consumption. The cutaneous barrier dysfunction predisposes patients to super-infections, septicemia, electrolyte imbalance, dehydration, or congestive heart failure.

Mucosal lesions

The angiotensin-converting enzyme-2 receptors present in the oral and conjunctival mucosal cells serve as a host for the virus to attach. Additionally, the altered kinetics of mucosal tissue due to systemic dysfunction in COVID-19 patients and the use of multiple salvage drugs contributes to immunological impairment that promotes secondary opportunistic infections such as oral candidiasis, recurrent herpetic gingivostomatitis, oral ulceration, erosions, and gingivitis.^[30]

Alopecia parvimaclata

It presents as small lentil-sized multiple atrophic foci of alopecia on the scalp. Lesions are hypothesized to be of a questionable infectious origin.^[31] We hypothesize that in our study, these lesions developed from flare-up of

seborrheic folliculitis in the patients healing with spotted scarring.

Eruptive pseudoangiomatosis

This is a paraviral eruption most commonly secondary to infection with ECHO virus E25 and E32, coxsackie B, Epstein-Barr virus, and cytomegalovirus.^[32,33] Typical lesions of EP consist of a central erythematous macule surrounded by a blanched hypopigmented border. All our cases were from the pediatric age group. Only one report apart from ours has reported this entity in patients with COVID-19.^[34]

Kawasaki-like exfoliation and multisystem inflammatory syndrome in children (MIS-C)

Despite having a good prognosis, in rare instances, pediatric cases may present with severe illness with multisystem involvement. Outbreaks of Kawasaki-like illness have been reported amidst the pandemic.^[35,36] We found two such cases in pediatric ICU, who had an uneventful recovery. Cases with urticarial vasculitis associated with MIS-C were also observed by us [Figure 1].

An incidental observation in our study was the presence of an otherwise unexplainable flare-up in patients with preexisting chronic dermatoses, namely acne vulgaris, psoriasis papulopustular rosacea, and a sudden exacerbation in telogen effluvium or shock hair loss. The dermatologists from our tertiary centers have also observed an increased incidence rate of herpes zoster and hand-foot-mouth disease during the pandemic, thus, indicating a viral flare-up or coinfection.

Unlike most other viruses the novel COVID-19 virus has been found to be associated with myriad cutaneous manifestations. Most patients had monomorphic lesions. Only a few patients had polymorphic eruptions. We hypothesize that patients with polymorphy develop lesions either due to polypharmacy or due to coinfection of another organism, like those with a flare-up in psoriasis (staph aureus), rosacea (Demodex), eruptive pseudoangiomatosis, and eruptive hypomelanosis.

There are some skin manifestations usually encountered early during the course of illness and could perhaps precede other symptoms, as observed in our patients. These early lesions, predominantly including urticaria, MP rash, petechiae/purpura/vasculitis, and eruptive pseudoangiomatosis could aid in the early diagnosis of COVID-19. Manifestations such as a vesicular rash, ulceration, urticarial vasculitis, and livedo could help in predicting severe disease requiring intensive care. Late markers including PR-like rash and eruptive hypomelanosis are only epidemiological markers in recovering cases.

Conclusion

In conclusion, our work provides a detailed clinical description of the impact of this novel viral infection on skin and also presents postulations for likely underlying mechanisms involved with these changes. We have also correlated these findings with disease severity and duration. The visual description provided by us could aid a physician in recognizing early or asymptomatic cases and help in containing the ongoing community spread of the illness. We also reported a few previously unpublished skin manifestations of COVID-19, namely, geographic tongue, chikungunya-like pigmentation, eruptive hypomelanosis, and alopecia parvimaclata.

However, more detailed analytic studies with histopathological correlation need to be done over longer periods as the disease revolves.

Declaration of patient consent

The authors certify that they have obtained all appropriate patient consent forms. In the form, the patients have given their consent for their images and other clinical information to be reported in the journal. The patients understand that their names and initials will not be published and due efforts will be made to conceal their identity, but anonymity cannot be guaranteed.

Financial support and sponsorship

Nil.

Conflicts of interest

There are no conflicts of interest.

References

- Zhu N, Zhang D, Wang W, Li X, Yang B, Song J, *et al.* A novel coronavirus from patients with pneumonia in China, 2019. *N Engl J Med* 2020;382:727-33.
- Recalcati S. Cutaneous manifestations in COVID-19: A first perspective. *J Eur Acad Dermatol Venereol* 2020;34:e212-3.
- Bhadra A, Mukherjee A, Sarkar K. Impact of population density on Covid-19 infected and mortality rate in India. *Model Earth Syst Environ* 2020;14:1-7.
- Gupta S, Gupta N, Gupta N. Classification and pathophysiology of cutaneous manifestations of COVID-19. *Int J Res Dermatol* 2020;6:584-8.
- Galván Casas C, Català A, Carretero Hernández G, Rodríguez-Jiménez P, Fernández-Nieto D, Rodríguez-Villa Lario A, *et al.* Classification of the cutaneous manifestations of COVID-19: A rapid prospective nationwide consensus study in Spain with 375 cases. *Br J Dermatol* 2020;183:71-7.
- Lesort C, Kanitakis J, Villani A, Ducroux E, Bouschon P, Fattouh K, *et al.* COVID-19 and outbreak of chilblains: Are they related? *J Eur Acad Dermatol Venereol* 2020;34:e757-8.
- Landa N, Mendieta-Eckert M, Fonda-Pascual P, Aguirre T. Chilblain-like lesions on feet and hands during the COVID-19 pandemic. *Int J Dermatol* 2020;59:739-43.
- Freeman EE, McMahon DE, Lipoff JB, Rosenbach M, Kovarik C, Desai SR, *et al.* The spectrum of COVID-19-associated dermatologic manifestations: An international registry of 716 patients from 31 countries. *J Am Acad Dermatol* 2020;83:1118-9.
- García-Legaz Martínez M, Martínez-Doménech Á, Magdaleno-Tapia J, Valenzuela-Oñate C, Partarrieu-Mejías F, Lorca-Spröhnle J, *et al.* Acute acral cutaneous manifestations during the COVID-19 pandemic: A single-centre experience. *J Eur Acad Dermatol Venereol* 2020;34:e692-4.
- Rubio-Muniz CA, Puerta-Peña M, Falkenhain-López D, Arroyo-Andrés J, Agud-Dios M, Rodríguez-Peralto JL, *et al.* The broad spectrum of dermatological manifestations in COVID-19: Clinical and histopathological features learned from a series of 34 cases. *J Eur Acad Dermatol Venereol* 2020;34:e574-6.
- Nasiri S, Araghi F, Tabary M, Gheisari M, Mahboubi-Fooladi Z, Dadkhahfar S. A challenging case of psoriasis flare-up after COVID-19 infection. *J Dermatolog Treat* 2020;31:448-9.
- Marasca C, Ruggiero A, Napolitano M, Fabbrocini G, Megna M. May COVID-19 outbreaks lead to a worsening of skin chronic inflammatory conditions?. *Med Hypotheses* 2020;143:109853.
- Daneshgaran G, Dubin DP, Gould DJ. Cutaneous manifestations of COVID-19: An evidence-based review. *Am J Clin Dermatol* 2020;21:627-39.
- Singh H, Kaur H, Singh K, Sen CK. Cutaneous manifestations of COVID-19: A systematic review. *Adv Wound Care (New Rochelle)* 2021;10:51-80.
- Herrero-Moyano M, Capusan TM, Andreu-Barasoain M, Alcántara-González J, Ruano-Del Salado M, Sánchez-Largo Uceda ME, *et al.* A clinicopathological study of eight patients with COVID-19 pneumonia and a late-onset exanthema. *J Eur Acad Dermatol Venereol* 2020;34:e460-4.
- Shahi V, Wetter DA, Cappel JA, Davis MD, Spittell PC. Vasospasm is a consistent finding in pernio (Chilblains) and a possible clue to pathogenesis. *Dermatology* 2015;231:274-9.
- de Masson A, Bouaziz JD, Sulimovic L, Cassius C, Jachiet M, Ionescu MA, *et al.* Chilblains is a common cutaneous finding during the COVID-19 pandemic: A retrospective nationwide study from France. *J Am Acad Dermatol* 2020;83:667-70.
- Docampo-Simón A, Sánchez-Pujol MJ, Juan-Carpena G, Palazón-Cabanes JC, Vergara-De Caso E, Berbegal L, *et al.* Are chilblain-like acral skin lesions really indicative of COVID-19? A prospective study and literature review. *J Eur Acad Dermatol Venereol* 2020;34:e445-7.
- El Hachem M, Diociaiuti A, Concato C, Carsetti R, Carnevale C, Ciofi Degli Atti M, *et al.* A clinical, histopathological and laboratory study of 19 consecutive Italian paediatric patients with chilblain-like lesions: Lights and shadows on the relationship with COVID-19 infection. *J Eur Acad Dermatol Venereol* 2020;34:2620-9.
- Drago F, Ciccarese G, Rebora A, Parodi A. Human herpesvirus-6, -7, and Epstein-Barr virus reactivation in pityriasis rosea during COVID-19. *J Med Virol* 2021;93:1850-1.
- Dursun R, Temiz SA. The clinics of HHV-6 infection in COVID-19 pandemic: Pityriasis rosea and Kawasaki disease. *Dermatol Ther* 2020;33:e13730.
- Veraldi S, Romagnuolo M, Benzecry V. Pityriasis rosea-like eruption revealing COVID-19. *Australas J Dermatol* 2020;10.1111/ajd. 13504. doi: 10.1111/ajd. 13504.
- Ciccarese G, Parodi A, Drago F. SARS-CoV-2 as possible inducer of viral reactivations. *Dermatol Ther* 2020;33:e13878.
- Brambilla L, Maronese CA, Tourlaki A, Veraldi S. Herpes zoster following COVID-19: A report of three cases. *Eur J Dermatol* 2020;30:754-6.
- Criado PR, Abdalla BM, de Assis IC,

- van Blaricum de Graaff Mello C, Caputo GC, Vieira IC. Are the cutaneous manifestations during or due to SARS-CoV-2 infection/COVID-19 frequent or not? Revision of possible pathophysiologic mechanisms. *Inflamm Res* 2020;69:745-56.
26. Askin O, Altunkalem RN, Altinisik DD, Uzuncakmak TK, Tursen U, Kutlubay Z. Cutaneous manifestations in hospitalized patients diagnosed as COVID-19. *Dermatol Ther* 2020;33:e13896.
 27. Magro C, Mulvey JJ, Berlin D, Nuovo G, Salvatore S, Harp J, *et al.* Complement associated microvascular injury and thrombosis in the pathogenesis of severe COVID-19 infection: A report of five cases. *Transl Res* 2020;220:1-13.
 28. Li MY, Li L, Zhang Y, Wang XS. Expression of the SARS-CoV-2 cell receptor gene ACE2 in a wide variety of human tissues. *Infect Dis Poverty* 2020;9:45.
 29. Khalil S, Hinds BR, Manalo IF, Vargas IM, Mallela S, Jacobs R. Livedo reticularis as a presenting sign of severe acute respiratory syndrome coronavirus 2 infection. *JAAD Case Rep* 2020;6:871-4.
 30. Dziedzic A, Wojtyczka R. The impact of coronavirus infectious disease 19 (COVID-19) on oral health. *Oral Dis* 2021;27:703-6.
 31. Hoefler W. Sporadisches auftreten von alopecia parvimaclata [Sporadic occurrence of alopecia parvimaclata]. *Dermatol Wochenschr* 1964;149:381-6.
 32. Kushwaha RK, Mohta A, Jain SK. A Case of eruptive pseudoangiomatosis: Clinical, histopathological, and dermoscopic findings. *Indian Dermatol Online J* 2020;11:672-3.
 33. Jha AK, Sonthalia S, Jakhar D. Dermoscopy of angiokeratoma. *Indian Dermatol Online J* 2018;9:141-2.
 34. Bouaziz JD, Duong TA, Jachiet M, Velter C, Lestang P, Cassius C. Vascular skin symptoms in COVID-19: A French observational study. *J Eur Acad Dermatol Venereol* 2020;34:e451-2.
 35. Xu S, Chen M, Weng J. COVID-19 and Kawasaki disease in children. *Pharmacol Res* 2020;159:104951.
 36. Brumfiel CM, DiLorenzo AM, Petronic-Rosic VM. Dermatologic manifestations of COVID-19-associated multisystem inflammatory syndrome in children. *Clin Dermatol* 2020. doi: 10.1016/j.clindermatol.2020.10.021.