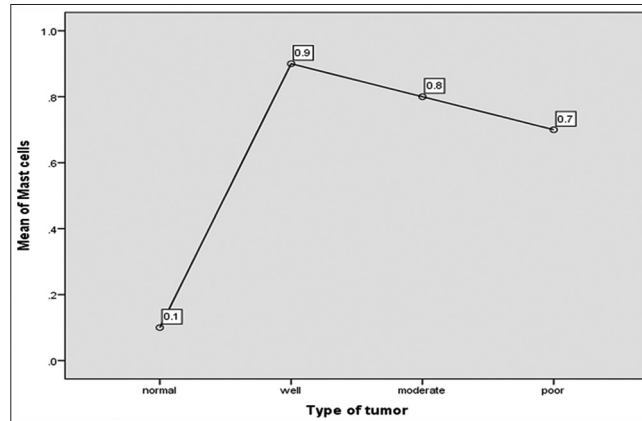


Erratum: Evaluation of myeloid cells (tumor associated tissue eosinophils and mast cells) infiltration in different grades of oral squamous cell carcinoma

In the article titled, “Evaluation of myeloid cells (tumor associated tissue eosinophils and mast cells) infiltration in different grades of oral squamous cell carcinoma” published in pages 158-167, issue 3, vol. 37 of Indian Journal of Medical and Paediatric Oncology,^[1] Graph 5 and its legend is incorrectly published.

The correct Graph 5 and its legend is mentioned below.



Graph 5: Mast cells infiltration in normal & in oral squamous cell carcinoma cases (ANOVA test).

Legend of Graph 6 is written incorrectly as “Eosinophils and mast cells expression in recurrence and no recurrence cases of oral squamous cell carcinoma” instead of “Recurrence & no recurrence cases of oral squamous cell carcinoma.”

REFERENCE

1. Debta P, Debta FM, Chaudhary M, Bussari S. Evaluation of myeloid cells (tumor-associated tissue eosinophils and mast cells) infiltration in different grades of oral squamous cell carcinoma. Indian J Med Paediatr Oncol 2016;37:158-67.

DOI: 10.4103/0971-5851.195754