

Surgical patch venoplasty after unsuccessful percutaneous balloon venoplasty for pacemaker lead–related superior vena cava stenosis



Dhaval Desai, MD, Ryan Cooley, MD, FHRS, David Kress, MD, Suhail Q. Allaqaband, MD

From Aurora Cardiovascular Services, Aurora Sinai/Aurora St. Luke's Medical Centers, Milwaukee, Wisconsin.

Introduction

Pacemaker and implantable cardioverter-defibrillator leads have been associated with venous stenosis. Symptomatic venous stenosis can have variable presentations. Early diagnosis and treatment of symptomatic venous stenosis is crucial for favorable long-term patient outcomes. We present a case of pacemaker lead–related superior vena cava (SVC) stenosis, presenting as bulging abdominal veins, that was repaired surgically after unsuccessful percutaneous angioplasty.

Case report

A 32-year-old woman with a history of complete heart block requiring a dual-chamber pacemaker presented with enlarged veins in her abdomen of 2 weeks' duration (Figure 1A). She became alarmed when the bulging veins progressed into her groin and arms, which prompted her to seek medical attention. She did not complain of any lightheadedness, facial swelling, flushing, or syncope.

She had been pacemaker-dependent since she was 20 years old. At that time, she had presented with increasing symptoms of fatigue, near-syncope with exertion, and palpitations. Electrocardiography and telemetry showed sinus bradycardia with intermittent second-degree and third-degree heart block. A left-sided, dual-chamber pacemaker was placed after no reversible cause of bradycardia was found. Between ages 21 and 28, she had several pacemaker lead–related events: right atrial lead fracture, pacemaker pocket revision, 2 episodes of right ventricular lead fractures, transvenous extraction of left-sided pacemaker leads and generator, and implantation of a right-sided, dual-chamber pacemaker.

The bulging veins in her abdomen, groin, and upper extremity caused concern for possible venous stenosis. She underwent a venogram, which showed significant stenosis

KEY TEACHING POINTS

- Pacing leads can lead to asymptomatic superior vena cava (SVC) stenosis in up to 33%–60% of patients and symptomatic SVC stenosis in up to 1%–3% of patients. Over time, pacemaker lead–induced mechanical stress of the venous endothelium can lead to inflammation, modeling, fibrosis, and, ultimately, stenosis.
- Bulging of the superficial abdominal veins, groin, and upper extremity in the setting of SVC stenosis is characteristic of stenosis below the level of the azygos vein.
- Treatment of pacemaker lead–mediated SVC stenosis includes anticoagulation, angioplasty with or without stent, and surgery. Treatment is usually individualized. Angioplasty and surgery show good short-term patency rates, but recurrent venous obstruction can occur in a small percentage of patients.
- Prevention of SVC stenosis is key. The number of pacemaker leads and the sum of the diameters of the implanted leads are associated with an increased risk of SVC stenosis. Therefore, the number of leads placed and procedures involving lead exchanges should be avoided.

of the SVC and right atrium (RA) junction (Figure 1B) below the level of the azygos vein with a mean pressure gradient difference of 13 mm Hg. A prominent azygos vein was visualized draining into the SVC (Figure 1B). Progressive percutaneous transluminal venoplasty was performed with increasing diameters of noncompliant balloons (Figure 1C). The gradient decreased to 10 mm Hg. It was felt that further aggressive balloon venoplasty could lead to procedural complications such as SVC rupture and/or tamponade, and

KEYWORDS Stenosis; Surgical patch venoplasty; Balloon venoplasty (Heart Rhythm Case Reports 2018;4:141–143)

Address reprint requests and correspondence: Dr Suhail Q. Allaqaband, Aurora Cardiovascular Services, Aurora St. Luke's Medical Center, 2801 W Kinnickinnic River Parkway, Ste 840, Milwaukee, WI 53215. E-mail address: publishing3@aurora.org.

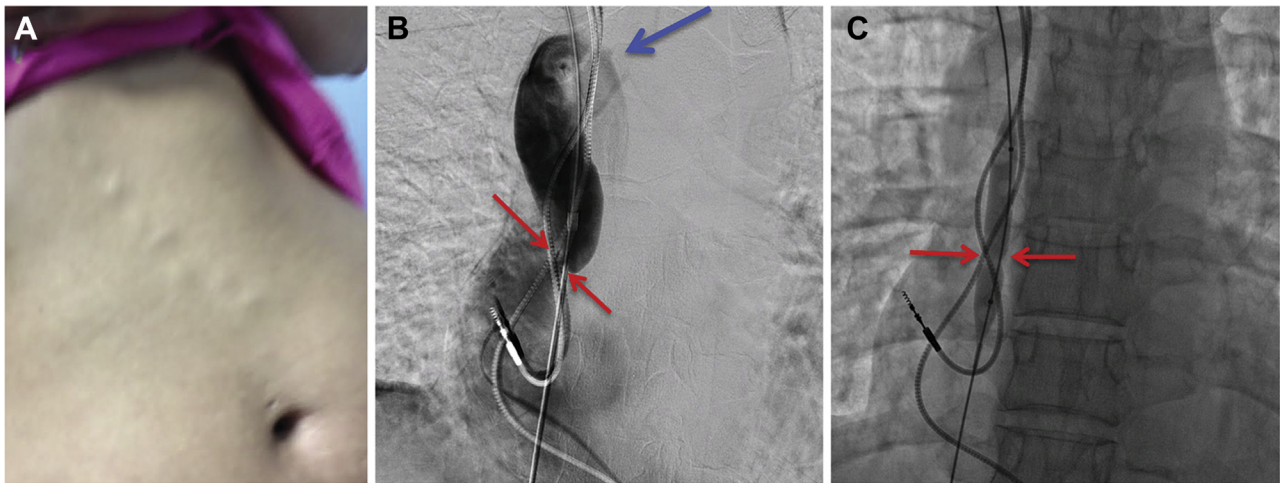


Figure 1 A: Bulging superficial abdominal veins in patient with superior vena cava (SVC) stenosis. B: Venogram shows a severe stenosis at the SVC–right atrium (RA) junction (*red arrows*) and prominent azygos vein (*blue arrow*). C: Balloon venoplasty is attempted to decrease stenosis across the SVC-RA junction.

therefore the procedure was stopped. She was started on anticoagulation with apixaban. The subsequent computed tomography (CT) venogram showed persistent, significant stenosis of the SVC-RA junction below the level of the azygos vein (**Figure 2A**). Extensive discussions were held between the patient and the heart team. She was interested in definitive treatment for her SVC stenosis. Given the need for dual-chamber pacing, history of keloid formation, and extensive scar burden after previously extracted left-sided pacemaker, it was felt that surgical venoplasty with venous endarterectomy and patulous patch, removal of all leads,

and epicardial dual-chamber pacemaker placement would be her best treatment option.

The patient underwent median sternotomy with bovine pericardial patch venoplasty of the SVC and SVC-RA junction, right pectoral pacemaker and lead extraction, and placement of epicardial leads and reinsertion of existing dual-chamber pacemaker in the right subcostal site. She was maintained on anticoagulation for 2 months after the surgery. A CT venogram 6 months after surgery did not show any evidence of SVC stenosis (**Figure 2B**). The bulging veins in her abdomen and groin resolved as well.

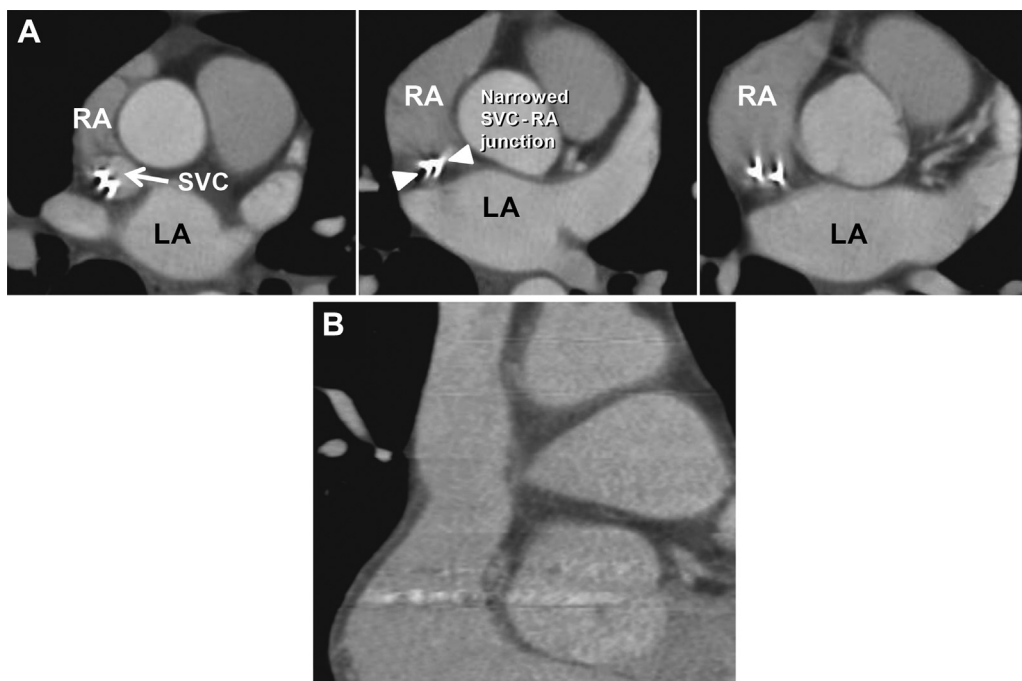


Figure 2 A: Serial axial images on computed tomography show persistent stenosis after attempted percutaneous venoplasty. The superior vena cava (SVC)–right atrium (RA) junction remained significantly narrowed; only the pacemaker leads are visualized at the junction (*arrowheads*). B: Computed tomography scan after surgical patch venoplasty shows widely patent SVC and SVC-RA junction (*arrow*). LA = left atrium.

Discussion

Incidence of symptomatic SVC stenosis due to pacing leads is reported to occur in 1%–3% of patients; however, asymptomatic venous stenosis is seen in 33%–60% of patients undergoing venography.¹ The pathophysiology is believed to be due to pacemaker lead–induced mechanical stress of the venous endothelium that leads to inflammation, remodeling, fibrosis, thrombus formation, and, ultimately, stenosis.² The number of pacemaker leads and the sum of the diameters of the implanted leads were shown to be a predictor of subsequent venous stenosis.¹

The mainstay of treatment for pacemaker lead–mediated SVC stenosis includes anticoagulation, angioplasty, and surgery. Anticoagulation maintains patency of the SVC as well as collateral vessels and reduces formation or propagation of potential venous thrombi. Endovascular interventions such as balloon angioplasty with or without stent placements are commonly used to treat stenosis and have shown good short-term patency rates.³ Long-term patency of this technique is lacking and recurrent venous obstruction can occur, requiring repeat interventions. There is a concern for periprocedural incidence of lead dysfunction and venous rupture with aggressive angioplasty.³ For patients experiencing recurrent stenosis, stenting should be considered to maintain longer patency.⁴ Ideally, stenting should be preceded by lead extraction, with subsequent reinsertion after successful stenting. This can help ensure that jailing of existing leads does not make their removal warrant a major surgery if they

become infected in the future. Surgery also can be considered in cases in which certain patient factors are in play: technically difficult percutaneous approach, unsuccessful endovascular treatment, stenosis related to infection requiring pacemaker, and lead extraction.⁵

In summary, we present a case of pacemaker lead–associated SVC stenosis with a rare presenting symptom of bulging abdominal veins. We initially attempted endovascular venoplasty to treat the stenosis but when aggressive venoplasty was unable to resolve the stenosis, a surgical approach was chosen. The SVC stenosis resolved with surgical patch venoplasty and epicardial pacemaker lead placement.

References

1. Abu-El-Haija B, Bhavne PD, Campbell DN, Mazur A, Hodgson-Zingman DM, Cotlarlan V, Giudici MC. Venous stenosis after transvenous lead placement: a study of outcomes and risk factors in 212 consecutive patients. *J Am Heart Assoc* 2015; 4:e001878.
2. Park HW, Kim W, Cho JG, Kang JC. Multiple pacing lead-induced superior vena cava syndrome: successful treatment by balloon angioplasty. *J Cardiovasc Electro-physiol* 2005;16:221–223.
3. Borsato GW, Rajan DK, Simons ME, Sniderman KW, Tan KT. Central venous stenosis associated with pacemaker leads: short-term results of endovascular interventions. *J Vasc Interv Radiol* 2012;23:363–367.
4. Fu HX, Huang XM, Zhong L, Osborn MJ, Bjarnason H, Mulpuru S, Zhao XX, Friedman PA, Cha YM. Outcome and management of pacemaker-induced superior vena cava syndrome. *Pacing Clin Electrophysiol* 2014;37:1470–1476.
5. Riley RF, Petersen SE, Ferguson JD, Bashir Y. Managing superior vena cava syndrome as a complication of pacemaker implantation: a pooled analysis of clinical practice. *Pacing Clin Electrophysiol* 2010;33:420–425.