



Since January 2020 Elsevier has created a COVID-19 resource centre with free information in English and Mandarin on the novel coronavirus COVID-19. The COVID-19 resource centre is hosted on Elsevier Connect, the company's public news and information website.

Elsevier hereby grants permission to make all its COVID-19-related research that is available on the COVID-19 resource centre - including this research content - immediately available in PubMed Central and other publicly funded repositories, such as the WHO COVID database with rights for unrestricted research re-use and analyses in any form or by any means with acknowledgement of the original source. These permissions are granted for free by Elsevier for as long as the COVID-19 resource centre remains active.



## Pneumonia caused by *Mycobacterium tuberculosis*

Meili Wei <sup>a,\*</sup>,<sup>1</sup>, Yongjie Zhao <sup>a,1</sup>, Zhuoyu Qian <sup>b</sup>, Biao Yang <sup>a</sup>, Jun Xi <sup>a</sup>, Jun Wei <sup>c</sup>, Bikui Tang <sup>a,\*\*</sup>

<sup>a</sup> School of Life Sciences, Bengbu Medical College, Anhui, China

<sup>b</sup> Middle School Affiliated to Guangzhou Foreign Studies University, Guangzhou, China

<sup>c</sup> Department of Gastroenterology, The First Affiliated Hospital of Bengbu Medical College, Anhui, China

### ARTICLE INFO

#### Article history:

Received 3 May 2020

Accepted 25 May 2020

Available online 16 June 2020

#### Keywords:

Tuberculosis

Acute tuberculous pneumonia

Diagnosis

Therapy

### abstract

Tuberculosis (TB) is one of the top ten leading causes of death worldwide. The causative agent of TB is *Mycobacterium tuberculosis*. Acute tuberculous pneumonia (TP) is an acute form of pulmonary TB. However, acute TP and non-tuberculous community-acquired pneumonia can be easily confused, resulting in deterioration of TP due to delayed treatment. Therefore, rapid and accurate diagnosis of acute TP is crucial in order to stop the transmission of TB. Moreover, development of new diagnostic tools (technologies and approaches), and flexible application of different therapy schemes will help to reduce the incidence of TP and promote the goal of ending the TB epidemic.

© 2020 Published by Elsevier Masson SAS on behalf of Institut Pasteur.

Tuberculosis (TB) is a communicable disease caused by the bacillus *Mycobacterium tuberculosis* (*M. tuberculosis*). Nowadays, TB is still one of the top ten causes of death worldwide. About a quarter of the world's population is infected with *M. tuberculosis*. According to WHO's global tuberculosis report 2019, there were an estimated 10 million new TB cases in 2018, and 1.5 million people died from TB worldwide. The leading cause of death for people with HIV is TB [1].

### 1. Acute tuberculous pneumonia

*M. tuberculosis* can invade various organs of the body. Pulmonary tuberculosis (PTB) is the most common, which can mainly cause lung injury and tubercles. PTB is a typical chronic consumptive disease, but it can present as an acute pneumonia. Acute tuberculous pneumonia (TP) is similar to typical bacterial pneumonia, and it is one of the causes of childhood illness [2].

Acute TP generally refers to the clinical manifestations of community-acquired pneumonia (CAP), but the pathogen is *M. tuberculosis* instead of non-tuberculous bacteria or viruses [3]. TP is contagious: coughing, sneezing, laughing, and even talking

can produce droplet nuclei containing *M. tuberculosis*. Transmission occurs when a person inhales the droplet nuclei [4].

In developing countries, *M. tuberculosis* is a main pathogen that cause CAP. A systematic review found that over 10% of patients with CAP in Asia were caused by *M. tuberculosis* [5]. HamidReza Naderi reported that 17.5% of 120 CAP patients were diagnosed with *M. tuberculosis* infection at Imam Reza Hospital in Mashhad, Iran [6]. Therefore, it is necessary to identify TP in patients with CAP in TB endemic areas. The global distribution of TP is consistent with that of TB (Fig. 1). The incident cases mostly occur in developing countries, where many TB patients live in densely populated areas. This close contact increases the risk of cross infection.

#### 1.1. Clinical presentation

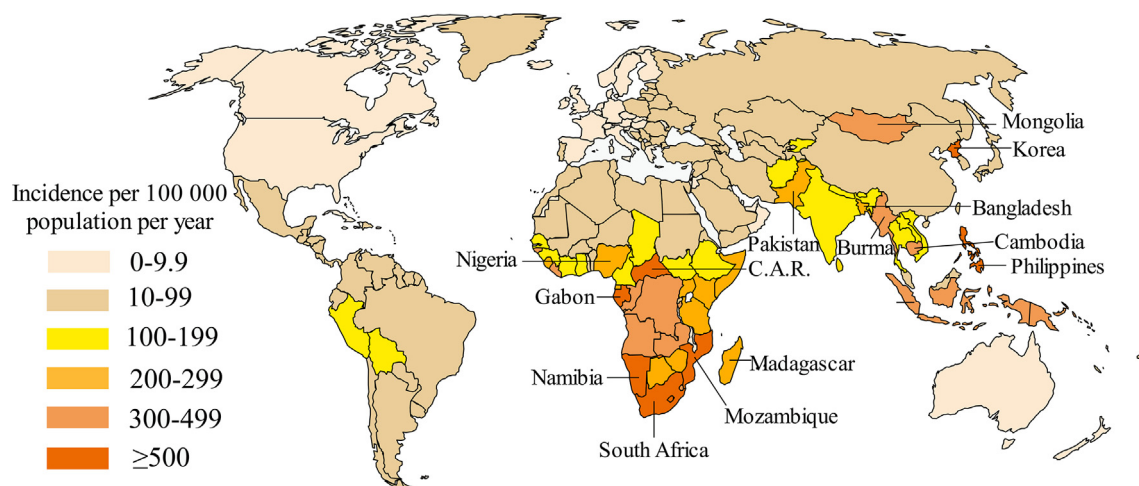
Different from typical PTB, acute TP presents as acute respiratory infection, including dry cough, fever and chest pain. Dry cough often precedes other respiratory and systemic symptoms [7]. Duration of symptoms is often more than 2 weeks prior to admission. The clinical symptoms of acute TP are similar to those of non-tuberculous CAP. However, patients with acute TP are subjectively better than patients with non-tuberculous bacterial pneumonia with less pleural pain, toxemia and dyspnea [8,9]. Compare to non-tuberculous CAP, weight loss is more common in patients with acute TP. Many patients with acute TP expectorate, but hemoptysis is relatively rare [6].

\* Corresponding author. School of Life Science, Bengbu Medical College, 2600 Donghai Avenue, Bengbu, 233030, China.

\*\* Corresponding author.

E-mail addresses: [meiliwei07@126.com](mailto:meiliwei07@126.com) (M. Wei), [bktang@sina.com](mailto:bktang@sina.com) (B. Tang).

<sup>1</sup> These authors contributed equally.



**Fig. 1.** Estimated TB incidence rates in 2018. Reproduced from global tuberculosis report 2019 ([https://www.who.int/tb/publications/global\\_report/en/](https://www.who.int/tb/publications/global_report/en/)). The incidence varied widely among countries in 2018.

Acute TP can result in severe consequences in some cases, such as acute respiratory distress syndrome (ARDS) in children [10]. Cases of acute respiratory failure caused by acute TP have also been reported [11,12]. Secondary diseases, including necrotizing pneumonia and destruction of the lung parenchyma, can be found in children, and were more common in HIV-infected children [13]. Jose Moreira pointed out that 59.3% of patients with TP have at least one complication; the most common ones are AIDS and diabetes [7].

## 1.2. Pathogenesis

Previous studies have tried to explain the pathogenesis of acute TP. *M. tuberculosis* propagates every 18–24 h, and it is uncommon for PTB to initially manifest as acute, rapidly progressive pneumonia. Septimus believed that this rapid progression may be an exudative hypersensitivity to aspirated tuberculoprotein, instead of the inflammatory response caused by *M. tuberculosis* [8]. Rich noted that the acute pneumonia could either be caused by massive *M. tuberculosis* infection or inhaled tuberculoprotein which cause acute exudative hypersensitivity. A study showed that in human TB, fresh pneumonia exudates were found around caseous lesions with little or no acid-fast bacilli (AFB) [14]. As early as 1931, Larson and Long injected tuberculin into the trachea of normal and TB guinea pigs respectively, confirming the hypersensitivity associated tuberculoproteins [15].

Imaging examination showed that TP was characterized by parenchymal lesions in the lung area around the affected bronchi. Bacteria and caseous substance penetrated into the periphery through these affected bronchial fistulas. TP presents a poor clinical inflammatory response that is different from the classic caseous pneumonia [16]. Clinically, dry irritating cough usually occurred a few days before fever and lung involvement, and appeared after the complete formation of fistula [17].

After the formation of TP, the outcome depends on the amount of bacteria in the caseous substance inhaled into the lungs from the lymph nodes. If there is little or no bacteria in the consolidation area, pneumonia will be relieved, which is previously called “epituberculosis” [18]. Otherwise, the disease will progress, and more necrotic cavities will spread to other areas of the lungs. Permanent lesions may occur, such as bronchostenosis. If the lesion is located in middle lobe or lingula, it will cause advanced complications such as bleeding and recurrent bacterial pneumonia [19].

## 1.3. TB and pneumonia

The incidence of pneumonia in PTB patients is higher than that in normal groups [20]. In some areas, such as Uganda, epidemiological analysis has shown that children with severe pneumonia have a higher incidence of PTB, accounting for 18.9% [21]. A recent study has shown that in CAP patients with *streptococcus pneumoniae* and *M. tuberculosis* coinfection, pneumococcal pneumonia is likely to provide fertile ground for reactivation of latent TB [22]. In patients with multidrug-resistant TB (MDR-TB), long-term use of medication increases the risk of secondary pneumonia. In turn, secondary pneumonia significantly delays in smear conversion to negative in patients with MDR-TB. This is also a cause to TB treatment failure [23]. Pneumonia and TB can be combined or exist one after another, and this would cause certain difficulties in identifying of the two diseases. Especially in the diagnosis of PTB, the manifestations of pneumonia are often more prominent. That may conceal the characteristics of PTB and lead to misdiagnosis.

## 2. Diagnosis

Patients with *M. tuberculosis* infection have lung damage and they may be at higher risk when pneumonia with different pathogens are raging. Once being infected with SARS-CoV-2, they are likely to develop serious COVID-19, making the treatment difficult. Therefore, timely and accurate screening of TP will help to reduce the transmission of TB.

Schwartz and Moyer proposed diagnostic criteria for TP based on its clinical manifestations: 1) Confluent dense shadows on the CXR involving at least one lobe; 2) High spiking fever; 3) Chest examination presenting signs of consolidation; and 4) Sputum examination positive for tubercle bacilli [24].

### 2.1. Clinical diagnosis

**Imaging test:** Medical imaging is an indispensable test in the diagnosis of acute TP. Morphological feature analysis of lesion is a pivotal basis for imaging diagnosis for acute TP. The radiographic characteristic of TP is homogeneous, segmental consolidation on CXR, which is interpreted by chest radiologists as bacterial pneumonia [25]. A retrospective study on 59 TP patients found that pulmonary consolidation of most cases (67.8%) appeared in upper

lobes, with the right lobe predominate. 9 cases' pulmonary consolidation were found in the middle lobe [7].

If a chest computed tomography (CT) scan is performed, the result will also be homogeneous consolidation [26]. Positron emission tomography combined with CT (PET/CT), which measures pulmonary inflammation through cellular uptake of  $^{18}\text{F}$ -labelled fluorodeoxyglucose, was very sensitive to detect *M. tuberculosis* early infection [27].

**Serologic test:** Leukocytosis was observed in only 35.6% of the TP patients [7]. The white blood cell count rarely exceeds 15,000/cu mm [8,9]. Some potential biomarkers in serum have been discovered in the diagnosis of TP. Researchers have constructed TB prediction model by detecting the levels of three iron biomarkers in serum (including serum iron, ferritin and transferrin) that can diagnose TB well. It can distinguish PTB from non-TB pneumonia. And it is hopeful to expand the diagnostic method of TP [28].

**Microbiological tests:** The AFB smear microscopy of the sputum or the bronchial washing specimens from TP patient is an effective and reliable method. Sputum smear microscopy is still the main laboratory test in many resource-limited settings [29]. The respiratory specimen of TP patient usually contains fewer bacteria and may require multiple samples for AFB test. The quality of microscopy diagnosis is often not guaranteed, as this test was noted to have poor sensitivity (between 30% and 70%) [30]. A retrospective observational study showed that 27 of 70 PTB patients (38.5%) were AFB smear-negative. These patients were more likely to be treated as non-tuberculous pneumonia and be admitted to the general ward without quarantined during hospitalization [31].

Using an automated screening system can improve the utility of this older diagnostic test-smear microscopy. Law has developed a computer-aided whole smear screening system, that can be used to detect AFB from respiratory specimens under general optical microscopy or fluorescence microscopy. So the staff workload can be reduced [32].

## 2.2. Differential diagnosis

Although there are many diagnostic methods, one of the challenges in the diagnosis of TP is to distinguish it from non-tuberculous CAP. In some areas with high TB prevalence, it is easy to misdiagnose PTB as CAP (such as community-acquired *Tsukamurella* pneumonia) due to similar symptoms [33]. Nonetheless, the two still have their own characteristics (Table 1). In the course of CAP treatment, acute TP should be considered when the patient experiences ineffective antibiotic treatment. And the patient should be screened for HIV infection [34].

Two inflammatory biomarkers, C-reactive protein (CRP) and procalcitonin (PCT), have shown the important clinical significance in identifying TB, *Pneumocystis jirovecii* pneumonia, and bacterial pneumonia in HIV patients [35]. PCT levels in patients with PTB were significantly lower than those non-tuberculous CAP patients

[6]. PCT tests have acceptable sensitivity and specificity in distinguishing TB from bacterial pneumonia [36]. However, a prospective cohort study showed that using CRP and PCT to identify TB from CAP patients has limited value [35]. Moreover, CRP has high sensitivity but low specificity in diagnosis of HIV-associated TB [37]. Accordingly, CRP and PCT can be used as reference indicators for the diagnosis of TP. In addition, Japanese researchers distinguished TP from non-tuberculous pneumonia by testing serum IFN- $\gamma$ , matrix metalloproteinases-1 and-9 (MMP-1 and MMP-9), and periostin [38].

The serum neutrophil-lymphocyte count ratio (NLR) levels of PTB patients were significantly lower than patients with bacterial CAP [39]. NLR can be used to distinguish PTB from bacterial CAP in the initial diagnosis. Besides, a study pointed out that the values of delta neutrophil index (DNI) of PTB patients were lower than those of CAP patients. Initially elevated DNI may help to rule out the possibility of PTB and also serve as an important potential diagnostic indicator to clinically distinguish between PTB patients and CAP patients [40].

A CT-based predictive nomogram built with pulmonary consolidation region, lymph node region and a clinical factor (duration of fever) can distinguish childhood PTB from CAP conveniently [26].

## 2.3. Etiologic diagnosis

**Mycobacterial culture:** *M. tuberculosis* culture, which is regarded as the “gold standard” for TB diagnosis by WHO, provides accurate and reliable results for acute TP diagnosis. Culture-positive strains can be used for subsequent strain identification and drug sensitivity testing. But traditional solid and liquid media culture have several limitations, including poor practicability, bacterial cross-contamination, and long culture time (about 2 months). Automated or semi-automated liquid culture system can significantly decrease the growth time of *M. tuberculosis* and shorten the diagnosis time of drug-sensitive *M. tuberculosis*. However, this system also takes about 14 days to detect *M. tuberculosis* [41], which is disadvantageous to the rapid diagnosis for TP.

**Immunological diagnosis:** IFN- $\gamma$  release assays (IGRAs) are originally developed to diagnose latent TB, and are widely used to detect *M. tuberculosis* infection with high specificity and sensitivity [42]. But the high cost limits their application in developing countries. Moreover, some studies have shown that severe diabetes may affect the results of IGRAs [43]. The TS-SPOT assay, which is also based on IFN- $\gamma$  detection, has the characteristics of low cost-effectiveness and high sensitivity. So it is a useful auxiliary method for rapid diagnosis of *M. tuberculosis* infection in low-income and high-incidence environment [44]. IGRA-ELISA can be used for large-scale detection, so it is easy to operate and can save manpower. In addition, there is a good correlation and consistency between IGRA-ELISA and T-SPOT.TB in the diagnosis of TB [45,46].

**Table 1**  
Difference between tuberculous pneumonia and non-tuberculous CAP.

	Tuberculous pneumonia	Non-tuberculous CAP
Clinical manifestation	<ul style="list-style-type: none"> <li>• Symptoms of tuberculosis</li> <li>• Night sweats, fever, dry cough, etc</li> </ul>	<ul style="list-style-type: none"> <li>• Severe poisoning symptoms</li> <li>• High fever, chills and mental malaise, etc.</li> </ul>
Laboratory test	<ul style="list-style-type: none"> <li>• Levels of WBC<sup>a</sup>, NE<sup>b</sup>, CRP<sup>c</sup> and PCT<sup>d</sup> are not high or slightly high</li> </ul>	<ul style="list-style-type: none"> <li>• Levels of WBC, NE, CRP and PCT are significantly increased</li> </ul>
Imaging test	<ul style="list-style-type: none"> <li>• Lesions are more common in the upper and middle lobes</li> <li>• Lesions appear as nodules, consolidations, and cavities</li> </ul>	<ul style="list-style-type: none"> <li>• Lesion location is uncertain</li> <li>• The lesions are mainly patchy shadows and consolidation shadows</li> </ul>

<sup>a</sup> WBC = White blood cell.

<sup>b</sup> NE = Neutrophils.

<sup>c</sup> CRP = C-reactive protein.

<sup>d</sup> PCT = Procalcitonin.

**Molecular assays:** The Center for Disease Control and Prevention (CDC) recommends that in addition to smear microscopy, at least one nucleic acid amplification (NAA) test, including polymerase chain reaction (PCR), should be performed for every suspected PTB patient [47,48]. A rapid, automated NAA test-Xpert MTB/RIF assay, is the only approach recommended by WHO for rapid diagnosis of TB and rifampicin resistance [49]. But this technology is not affordable in high-TB burden countries with limited resources [50]. And children are less sensitive than adults [49]. Xpert MTB/RIF Ultra assay is more sensitive than Xpert MTB/RIF assay in detecting TB patients complicated with paucibacillary disease or HIV, and is more sensitive to specimens with low bacillus content [51]. Therefore it can overcome the limitation of Xpert MTB/RIF assay. The detection of bacterial RNA can target viable *M. tuberculosis*. Bacterial load in sputum can be quantified through detecting 16S ribosomal RNA [52], as sensitive as solid culture [53].

In contrast to *M. tuberculosis* culture, one of the main advantages of molecular test is the rapid diagnosis that the results can be obtained on the same day [54]. However, the premise of rapid PCR-based test is to obtain a respiratory specimen, which is not practical for sputum samples of inadequate quality or patients who cannot spit. In order to collect specimens more effectively, Williams CM and his colleagues developed face-mask sampling, a highly efficient and non-invasive method for detecting exhaled *M. tuberculosis* output. This approach can detect early infection [55].

### 3. Treatment

#### 3.1. Anti-TB therapy

There are two types of anti-tuberculosis drugs in clinical use currently: first-line and second-line antibiotics. First-line drugs include rifampicin, streptomycin, isoniazid, etc. Second-line drugs include kanamycin, ciprofloxacin, ethionamide, etc. [56]. TB treatment requires a combination of multiple antibiotics with a treatment cycle of 6–9 months or even 2 years. However, the combination of multiple antibiotics, non-standard medication and insufficient medication duration are likely to produce strains of drug resistance [57]. These strains are defined as MDR. The main drugs used to treat MDR-TB are fluoroquinolones (FQ) and lastline injections (amikacin, kanamycin and capreomycin). Their use may lead to the emergence of extensively drug-resistant (XDR) strains that developed additional resistance mechanisms to FQ and aminoglycosides [58]. Therefore, the use of FQ as an empirical treatment for CAP in TB endemic areas should implement short-course (5–10 days) regimen to reduce the appearance of FQ-resistant *M. tuberculosis* [59]. This emphasizes the importance of rapid screening for *M. tuberculosis* infection in CAP patients [60]. It has been reported that delamanid and bedaquiline can be used in combination to treat XDR-TB and MDR-TB. Increasing evidence shows that this medicine combination is likely to be acceptable [61,62].

A series of candidate host-directed and immune-based therapies can accelerate the eradication of *M. tuberculosis*. They are being developed and will be used as adjuvant therapies to shorten the course of treatment, prevent permanent lung injury and improve the outcome of MDR-TB treatment [63]. It has been reported that a female with TP complicated with severe ARDS and disseminated intravascular coagulation has been successfully treated by high frequency oscillatory ventilation, vasopressor support, anti-TB therapy, intravenous immunoglobulin and recombinant soluble human thrombomodulin [10].

Inhaled drug therapy for TB can be used to supplement traditional oral drug therapy. The advantage of inhalation therapy for TB

is that it can deliver high concentrations of drugs to the lungs, which is the main sites of *M. tuberculosis* infection. Inhalation therapy for TB is a potentially strategy that needs to be evaluated in clinical studies [64]. There is a precedent for inhalation of beclomethasone dipropionate in acute TP patients complicated with asthma [65]. A recent article described the effect of intrapulmonary administration on local and systemic pharmacokinetics and showed how inhaled administration achieved high levels in the lung along with low levels of systemic absorption, which will help avoid toxicity [66]. Therefore, as one of the alternative strategies for traditional medicine, inhalation therapy is a potential method for the treatment of TP.

#### 3.2. Anti-inflammatory therapy

After *M. tuberculosis* is engulfed by alveolar macrophages, the infected macrophages will release pro-inflammatory cytokines [67]. Increasing evidence supports that inhibiting excessive and harmful inflammatory responses may reduce mycobacterial dissemination without inducing immunopathology [68–70]. Therefore, anti-inflammatory drugs should be considered in treatment for TP except antibiotics that target *M. tuberculosis*. A study found that PTB patients with acute renal failure who received corticosteroids had lower mortality than patients without corticosteroids [71]. It may be related to the anti-inflammatory properties of glucocorticoids and receptor agonists, such as dexamethasone and prednisone [72]. Corticosteroids can prevent immune reconstitution inflammatory syndrome in TB/HIV co-infection by improving TB lung pathology [73]. Survival benefits for TB meningitis have been proved [74]. Another study reported that *M. tuberculosis* associated necrotizing pneumonia was successfully treated by the initiation of corticosteroid followed by anti-TB drugs [75]. Andy Ruiz et al. found that Resolvin D1 and Maresin 1 can induce anti-inflammatory mechanism of human macrophages and produce different antimicrobial effectors to control intracellular growth of *M. tuberculosis* [76]. Their clinical application in patients with TP needs to be addressed in the future.

#### 3.3. Pulmonary function repair

Although the cure rate of new cases of TB has reached 85% in 2017, the chronic lung injury after PTB should not be ignored. Compared with the entire population, the morbidity and mortality of TB survivors were higher [77,78]. Pulmonary consolidation caused by TP can cause destructive damage to lung tissue, which is typically marked by pulmonary cavity [79,80]. Therefore, chronic lung damage after treatment of *M. tuberculosis* infection should be considered [78,81], and lung function repair should be performed to prevent *M. tuberculosis* reinfection.

Studies have found that inhibiting matrix metalloproteinase may reduce lung damage in people with history of tuberculosis, but it still needs to be proved by clinical trials [82]. Some traditional Chinese medicines may have repairing and protecting effects on TB-induced lung damage. Sinomenine, which was originally extracted from a Chinese herbal medicine-*Sinomenium acutum*, can attenuate acute lung injury by inhibiting inflammation and reducing oxidative stress [83]. Radix Astragali, a traditional Chinese medicine, can protect cells and tissues from oxidative stress by scavenging free radicals and reactive oxygen species, and finally providing significant protection against lung injury [84].

Climate change, air pollution and air allergens, etc. can affect cardiopulmonary health [85]. In the elderly, the increase in temperature and relative humidity are related to the decline in lung function [86]. Therefore, elderly patients with TP should pay attention to living in a suitable environment after recovery. Pablo A

Salcedo et al. used meta-analysis to quantify the effect of exercise training on indices of pulmonary function in adults with chronic lung disease, and pointed out that whole body exercise training can effectively improve lung function, especially the vital capacity index [87]. Exercise can also improve the lung function of children with cystic fibrosis [88]. Therefore, proper exercise is indispensable after TP treatment.

### 3.4. Vaccine prevention and treatment

Vaccine is the best way to prevent TP. Bacille Calmette–Guérin (BCG) is the only licensed vaccine against *M. tuberculosis* infection [89]. Although BCG can effectively protect infants and young children from *M. tuberculosis* infection, its efficacy on PTB varies, especially among adults [90]. Therefore, the emergence of new vaccines or new usage of existing vaccine is still worth looking forward to. The discovery of intravenous BCG by Darrah and colleagues provided greater protection to prevent TB [91]. Juan I. Moliva et al. pointed out that petroleum can be used to selectively remove many inflammatory lipids (including trehalose dimycolate, trehalose dimycolate, mycoside B, triacylglycerols, and phthiocerol dimycocerosates) of BCG, without affecting the vitality of BCG. This would make the processed vaccine safer by reducing inflammation [92].

In addition, there are many candidate vaccines under development. For example, a modified vaccine-MVA85A, which can express Ag85A, is the first therapeutic vaccine that undergo clinical efficacy trials in more than 60 years. However, the infants who received MVA85A as booster vaccination after BCG have been found no significant improvement in TB protection during three years' follow-up [93]. Thomas H. King et al. found that a new *Saccharomyces cerevisiae* immunotherapeutic vaccine named GI-19007 had immunogenicity in mice. This fusion vaccine can elicit strong IFN- $\gamma$  and IL-17 responses. The survival rate of guinea pigs treated with GI-19007 and BCG was higher than BCG alone, so it may be used to limit lung injury and expand chemotherapy regimens for TB treat [94]. With the rapid development of immunology and molecular biology, others new TB vaccines have emerged to provide new hope for the prevention and treatment of TB, including inactivated vaccines, recombinant live vaccines, attenuated live vaccines, subunit vaccines, and DNA vaccines, etc. [95].

## 4. Concluding remarks

Lung infection with *M. tuberculosis* usually presents as a chronic consumptive disease, but it can also cause acute pneumonia. Under the cover of various types of pneumonia, TP can be easily misdiagnosed, leading to more serious disease progression. No matter in the areas with high or low prevalence of TB, the attending doctor should be alert to *M. tuberculosis* infection for patients with doubtful pneumonia.

High sensitivity, high specificity and easy-to-use diagnostic tests are necessary for the rapid and accurate detection of *M. tuberculosis* infection. However, it's worth noting that many diagnostic tests are inadequate for young children who are prone to TP. In low income areas where TB is prevalent, affordability of diagnostic tools is also an important issue.

One difficulty in TP treatment is drug-resistant TB. Drug screening of infected patients will undoubtedly increase the treatment effect. TP is more common in special populations, such as children, the elderly, and HIV patients, individualized treatment should also be considered. Of course, the clinical application of new vaccines with stronger protection is more worthy of expectation, so as to realize the long-cherished desire to completely eliminate TB.

## Conflict of interest

The authors declare no conflict of interest.

## Acknowledgements

The work & review were supported by the Research Foundation of Anhui Provincial Education Department (KJ2019A0317 and KJ2019A0361), the Natural Science Research Foundation of Anhui Provincial (1708085MH192), the Research Fund of Bengbu Medical College (BYKY1811ZD, BYKY1835ZD and BYKY2019020ZD), the National Training Programs of Innovation and Entrepreneurship for Undergraduates (201810367037, 201910367007 and 201810367007).

## References

- [1] WHO. [https://www.who.int/tb/publications/global\\_report/en/](https://www.who.int/tb/publications/global_report/en/); 2019.
- [2] Nika ER, Mabilia Babela JR, Missambou Mandilou SV, Moyer G. Study of 9 cases of tuberculosis pneumonia in children at Chu of Brazzaville, Congo. *Global Pediatr Health* 2016;3: 2333794X16651512.
- [3] Lee SH, Hur GY, Jung KH, Lee SY, Lee SY, Kim JH, et al. Clinical investigation of tuberculous pneumonia. *Tuberc Respir Dis* 2004;57:19–24.
- [4] Gonzalo-Asensio J, Aguilo N, Marinova D, Martin C. Breaking transmission with vaccines: the case of tuberculosis. *Microbiol Spectr* 2017;5:249–61.
- [5] Peto L, Nadjm B, Horby P, Ngan TTD, van Doorn R, Kinh NV, et al. The bacterial aetiology of adult community-acquired pneumonia in Asia: a systematic review. *Trans R Soc Trop Med Hyg* 2014;108:326–37.
- [6] Naderi H, Sheybani F, Erfani SS, Amiri B, Nooghabi MJ. The mask of acute bacterial pneumonia may disguise the face of tuberculosis. *Electron Physician* 2017;9:3943–9.
- [7] Moreira J, Fochesatto JB, Moreira AL, Pereira M, Porto N, Hochegger B. Tuberculous pneumonia: a study of 59 microbiologically confirmed cases. *J Bras Pneumol* 2011;37:232–7.
- [8] Septimus EJ, Awe RJ, Greenberg SD, Raleigh JW. Acute tuberculous pneumonia. *Chest* 1977;71:774–5.
- [9] Pinner M. Pulmonary tuberculosis in the adult. Springfield, Ill., Charles C. Thomas, Co; 1945.
- [10] Ngo DT, Phan PH, Kawachi S, Nakajima N, Hirata N, Aina A, et al. Tuberculous pneumonia-induced severe ARDS complicated with DIC in a female child: a case of successful treatment. *BMC Infect Dis* 2018;18:294.
- [11] Petrillo TM, Heard ML, Fortenberry JD, Stockwell JA, Leonard Jr MK. Respiratory failure caused by tuberculous pneumonia requiring extracorporeal membrane oxygenation. *Perfusion* 2001;16:525–9.
- [12] Puri M, Kumar S, Prakash B, Lokender K, Jaiswal A, Behera D. Tuberculosis pneumonia as a primary cause of respiratory failure—report of two cases. *Indian J Tubercul* 2010;57:41–7.
- [13] Jacobs C, Goussard P, Gie RP. *Mycobacterium tuberculosis*, a cause of necrotising pneumonia in childhood: a case series. *Int J Tubercul Lung Dis* 2018;22: 614–6.
- [14] Rich AR. The pathogenesis of tuberculosis. *South Med J* 1944;37:593.
- [15] Larson A, Long ER. Experimental tuberculin pneumonia. *Am Rev Tubercul* 1931;23:41–4.
- [16] Yoshikawa M, Tokuda H, Kasai S, Kitagawa H, Oishi N, Nagase T. Clinical and radiological features of tuberculous pneumonia in patients with emphysema. *Kekkaku* 2010;85:453–60.
- [17] Lee JH, Park SS, Lee DH, Shin DH, Yang SC, Yoo BM. Endobronchial tuberculosis. Clinical and bronchoscopic features in 121 cases. *Chest* 1992;102:990–4.
- [18] Fish R, Pagel W. The morbid anatomy of epituberculosis. *J Pathol Bacteriol* 1938;47:593–601.
- [19] Graham EA, Burford TH, Mayer JH. Middle lobe syndrome. *Postgrad Med* 1948;4:29–34.
- [20] Chang T-M, Mou C-H, Shen T-C, Yang C-L, Yang M-H, Wu F-Y, et al. Retrospective cohort evaluation on risk of pneumonia in patients with pulmonary tuberculosis. *Medicine* 2016;95:e4000.
- [21] Nantongo JM, Wobudeya E, Mupere E, Joloba M, Ssengooba W, Kisembo HN, et al. High incidence of pulmonary tuberculosis in children admitted with severe pneumonia in Uganda. *BMC Pediatr* 2013;13:16.
- [22] Garcia R. Community-acquired pneumonia due to *streptococcus pneumoniae*: when to consider coinfection with active pulmonary tuberculosis. *Case Rep Infect Dis* 2019;2019:4618413.
- [23] Yong TS, Zhi LZ, Chiwala G, Bin KH, Pei HZ, Juan QH, et al. The effects of secondary pneumonia on the curative efficacy of multidrug-resistant tuberculosis: a retrospective cohort study. *Biomed Environ Sci* 2018;31:908–12.
- [24] Schwartz WS, Moyer RE. The management of massive tuberculous pneumonia; a therapeutic review of seventy-five cases. *Am Rev Tubercul* 1951;64: 41–9.
- [25] Lee KM, Choe KH, Kim SJ. Clinical investigation of cavitary tuberculosis and tuberculous pneumonia. *Korean J Intern Med* 2006;21:230–5.

- [26] Wang B, Li M, Ma H, Han F, Wang Y, Zhao S, et al. Computed tomography-based predictive nomogram for differentiating primary progressive pulmonary tuberculosis from community-acquired pneumonia in children. *BMC Med Imag* 2019;19:63.
- [27] Ankras AO, Glaudemans AWJM, Maes A, Van de Wiele C, Dierckx RAJO, Vorster M, et al. *Tubercul Semin Nucl Med* 2018;48:108–30.
- [28] Dai Y, Shan W, Yang Q, Guo J, Zhai R, Tang X, et al. Biomarkers of iron metabolism facilitate clinical diagnosis in *Mycobacterium tuberculosis* infection. *Thorax* 2019;74:1161–7.
- [29] Singhal R, Myneedu VP. Microscopy as a diagnostic tool in pulmonary tuberculosis. *Int J Mycobacteriol* 2015;4:1–6.
- [30] Foulds J, O'Brien R. New tools for the diagnosis of tuberculosis: the perspective of developing countries. *Int J Tubercul Lung Dis* 1998;2:778–83.
- [31] Zhang ZX, Sng LH, Yong Y, Lin LM, Cheng TW, Seong NH, et al. Delays in diagnosis and treatment of pulmonary tuberculosis in AFB smear-negative patients with pneumonia. *Int J Tubercul Lung Dis* 2017;21:544–9.
- [32] Law YN, Jian H, Lo NWS, Ip M, Chan MMY, Kam KM. Low cost automated whole smear microscopy screening system for detection of acid fast bacilli. *PLoS One* 2018;13:e0190988.
- [33] Yang L, Cao Y, Dan Z, Wang Z, Wang X. Community-acquired *Tsukamurella* pneumonia in a young immunocompetent adult: a case misdiagnosed as pulmonary tuberculosis and literature review. *Postgrad Med* 2017;129:563–6.
- [34] Matsuura H, Yamaji Y. Tuberculous pneumonia. *QJM* 2018;111:131.
- [35] Mendelson F, Griesel R, Tiffin N, Rangaka M, Boule A, Mendelson M, et al. C-reactive protein and procalcitonin to discriminate between tuberculosis, *Pneumocystis jirovecii* pneumonia, and bacterial pneumonia in HIV-infected inpatients meeting WHO criteria for seriously ill: a prospective cohort study. *BMC Infect Dis* 2018;18:399.
- [36] Huang SL, Lee HC, Yu CW, Chen HC, Wang CC, Wu JY, et al. Value of procalcitonin in differentiating pulmonary tuberculosis from other pulmonary infections: a meta-analysis. *Int J Tubercul Lung Dis* 2014;18:470–7.
- [37] Yoon C, Chaisson LH, Patel SM, Allen IE, Drain PK, Wilson D, et al. Diagnostic accuracy of C-reactive protein for active pulmonary tuberculosis: a meta-analysis. *Int J Tubercul Lung Dis* 2017;21:1013–9.
- [38] Yamauchi M, Kinjo T, Parrott G, Miyagi K, Haranaga S, Nakayama Y, et al. Diagnostic performance of serum interferon gamma, matrix metalloproteinases, and periostin measurements for pulmonary tuberculosis in Japanese patients with pneumonia. *PLoS One* 2020;15:e0227636.
- [39] Yoon NB, Son C, Um SJ. Role of the neutrophil-lymphocyte count ratio in the differential diagnosis between pulmonary tuberculosis and bacterial community-acquired pneumonia. *Ann Lab Med* 2013;33:105–10.
- [40] Jhun BW, Sim YS, Shin TR, Kim DG. The utility of delta neutrophil index in differentiation of pulmonary tuberculosis from community acquired pneumonia. *Sci Rep* 2018;8:1–7.
- [41] Drobniewski FA, Caws M, Gibson A, Young D. Modern laboratory diagnosis of tuberculosis. *Lancet Infect Dis* 2003;3:141–7.
- [42] Pai M, Behr M. Latent *Mycobacterium tuberculosis* infection and interferon-gamma release assays. *Microbiol Spectr* 2016;4:379–88.
- [43] Takasaki J, Manabe T, Morino E, Muto Y, Hashimoto M, Iikura M, et al. Sensitivity and specificity of QuantiFERON-TB gold Plus compared with QuantiFERON-TB gold in-tube and T-SPOT.TB on active tuberculosis in Japan. *J Infect Chemother* 2018;24:188–92.
- [44] Li G, Li F, Zhao HM, Wen HL, Li HC, Li CL, et al. Evaluation of a new IFN-γ release assay for rapid diagnosis of active tuberculosis in a high-incidence setting. *Front Cell Infect Microbiol* 2017;7:117.
- [45] Wang L, Tian XD, Yu Y, Chen W. Evaluation of the performance of two tuberculosis interferon gamma release assays (IGRA-ELISA and T-SPOT.TB) for diagnosing *Mycobacterium tuberculosis* infection. *Clin Chim Acta* 2018;479:74–8.
- [46] Zhu M, Zhu Z, Yang J, Hu K. Performance evaluation of IGRA-ELISA and T-SPOT.TB for diagnosing tuberculosis infection. *Clin Lab* 2019;65.
- [47] Parrish NM, Carroll KC. Role of the clinical mycobacteriology laboratory in diagnosis and management of tuberculosis in low-prevalence settings. *J Clin Microbiol* 2011;49:772–6.
- [48] CDC. Updated guidelines for the use of nucleic acid amplification tests in the diagnosis of tuberculosis. *MMWR Morb Mortal Wkly Rep* 2009;58:7–10.
- [49] Boehme CC, Nabeta P, Hillemann D, Nicol MP, Shenai S, Krapp F, et al. Rapid molecular detection of tuberculosis and rifampin resistance. *N Engl J Med* 2010;363:1005–15.
- [50] Trébuq A, Enarson DA, Chiang CY, Van Deun A, Harries AD, Boillot F, et al. Xpert® MTB/RIF for national tuberculosis programmes in low-income countries: when, where and how? *Int J Tubercul Lung Dis* 2011;15:1567–72.
- [51] Dorman SE, Schumacher SG, Alland D, Nabeta P, Armstrong DT, King B, et al. Xpert MTB/RIF Ultra for detection of *Mycobacterium tuberculosis* and rifampicin resistance: a prospective multicentre diagnostic accuracy study. *Lancet Infect Dis* 2018;18:76–84.
- [52] Honeyborne I, McHugh TD, Phillips PP, Bannoo S, Bateson A, Carroll N, et al. Molecular bacterial load assay, a culture-free biomarker for rapid and accurate quantification of sputum *Mycobacterium tuberculosis* bacillary load during treatment. *J Clin Microbiol* 2011;49:3905–11.
- [53] Honeyborne I, Mtafya B, Phillips PP, Hoelscher M, Ntinginya EN, Kohlenberg A, et al. The molecular bacterial load assay replaces solid culture for measuring early bactericidal response to antituberculosis treatment. *J Clin Microbiol* 2014;52:3064–7.
- [54] Cohen RA, Muzaffar S, Schwartz D, Bashir S, Luke S, McGartland LP, et al. Diagnosis of pulmonary tuberculosis using PCR assays on sputum collected within 24 hours of hospital admission. *Am J Respir Crit Care Med* 1998;157:156–61.
- [55] Williams CM, Abdulwhhab M, Birring SS, De Kock E, Garton NJ, Townsend E, et al. Exhaled *Mycobacterium tuberculosis* output and detection of subclinical disease by face-mask sampling: prospective observational studies. *Lancet Infect Dis* 2020;20:607–17.
- [56] Rawat DS. Antituberculosis drug research: a critical overview. *Med Res Rev* 2013;33:693–764.
- [57] Prideaux B, Via LE, Zimmerman MD, Eum S, Sarathy J, O'Brien P, et al. The association between sterilizing activity and drug distribution into tuberculosis lesions. *Nat Med* 2015;21:1223–7.
- [58] Cox HS, Sibilia C, Feuerriegel S, Kalon S, Polonsky J, Khamraev AK, et al. Emergence of extensive drug resistance during treatment for multidrug-resistant tuberculosis. *N Engl J Med* 2008;359:2398–400.
- [59] Shen GH, Tsao TC, Kao SJ, Lee JJ, Chen YH, Hsieh WC, et al. Does empirical treatment of community-acquired pneumonia with fluoroquinolones delay tuberculosis treatment and result in fluoroquinolone resistance in *Mycobacterium tuberculosis*? Controversies and solutions. *Int J Antimicrob Agents* 2012;39:201–5.
- [60] Grossman RF, Hsueh P-R, Gillespie SH, Blasi F. Community-acquired pneumonia and tuberculosis: differential diagnosis and the use of fluoroquinolones. *Int J Infect Dis* 2014;18:14–21.
- [61] Maryandyshev A, Pontali E, Tiberi S, Akkerman O, Ganatra S, Sadutshang TD, et al. Bedaquiline and delamanid combination treatment of 5 patients with pulmonary extensively drug-resistant tuberculosis. *Emerg Infect Dis* 2017;23:1718–21.
- [62] Tadolini M, Lingsang RD, Tiberi S, Enwerem M, D'Ambrosio L, Sadutshang TD, et al. First case of extensively drug-resistant tuberculosis treated with both delamanid and bedaquiline. *Eur Respir J* 2016;48:935–8.
- [63] Tiberi S, du Plessis N, Walzl G, Vjecha MJ, Rao M, Ntoumi F, et al. Tuberculosis: progress and advances in development of new drugs, treatment regimens, and host-directed therapies. *Lancet Infect Dis* 2018;18:e183–98.
- [64] Braunstein M, Hickey AJ, Ekins S. Why wait? The case for treating tuberculosis with inhaled drugs. *Pharm Res (N Y)* 2019;36:166.
- [65] Tanaka I, Okazawa M, Taniguchi M, Suzuki K, Tamura R, Sakakibara H, et al. A case of acute tuberculous pneumonia in a patient with asthma. *Allergol Int* 2000;49:269–73.
- [66] Boisson M, Jacobs M, Grégoire N, Gobin P, Marchand S, Couet W, et al. Comparison of intrapulmonary and systemic pharmacokinetics of colistin methanesulfonate (CMS) and colistin after aerosol delivery and intravenous administration of CMS in critically ill patients. *Antimicrob Agents Chemother* 2014;58:7331–9.
- [67] Stamm CE, Collins AC, Shiloh MU. Sensing of *Mycobacterium tuberculosis* and consequences to both host and bacillus. *Immunol Rev* 2015;264:204–19.
- [68] Di Liberto D, Caccamo N, Meraviglia S, Guggino G, La Manna MP, Sireci G, et al. Tuning inflammation in tuberculosis: the role of decoy receptors. *Microb Infect* 2009;11:821–7.
- [69] Garlanda C, Di Liberto D, Vecchi A, La Manna MP, Buracchi C, Caccamo N, et al. Dampening excessive inflammation and tissue damage in *Mycobacterium tuberculosis* infection by Toll IL-1 receptor 8/single Ig IL-1-related receptor, a negative regulator of IL-1/TLR signaling. *J Immunol* 2007;179:3119–25.
- [70] Harishankar M, Afsal K, Banurekha V, Meenakshi N, Selvaraj P. 1, 25-Dihydroxy vitamin D3 downregulates pro-inflammatory cytokine response in pulmonary tuberculosis. *Int Immunopharm* 2014;23:148–52.
- [71] Kim YJ, Pack KM, Jeong E, Na JO, Oh Y-M, Lee S, et al. Pulmonary tuberculosis with acute respiratory failure. *Eur Respir J* 2008;32:1625–30.
- [72] Cain DW, Cidlowski JA. Immune regulation by glucocorticoids. *Nat Rev Immunol* 2017;17:233–47.
- [73] Critchley JA, Young F, Orton L, Garner P. Corticosteroids for prevention of mortality in people with tuberculosis: a systematic review and meta-analysis. *Lancet Infect Dis* 2013;13:223–37.
- [74] Bourgi K, Fiske C, Sterling TR. Tuberculosis meningitis. *Curr Infect Dis Rep* 2017;19:39.
- [75] Nguyen HL, Duong Thanh H, Le TV, Tran Van N. *Mycobacterium tuberculosis*-associated necrotizing pneumonia with adjunctive corticosteroid therapy. *Case Rep Infect Dis* 2019;2019.
- [76] Ruiz A, Arabia C, Torres M, Juárez E. Resolvin D1 (RvD1) and maresin 1 (Mar1) contribute to human macrophage control of *M. tuberculosis* infection while resolving inflammation. *Int Immunopharm* 2019;74:105694.
- [77] Chin AT, Rylance J, Makumbirofa S, Meffert S, Vu T, Clayton J, et al. Chronic lung disease in adult recurrent tuberculosis survivors in Zimbabwe: a cohort study. *Int J Tubercul Lung Dis* 2019;23:203–11.
- [78] Harries AD, Ade S, Burney P, Hoa NB, Schluger NW, Castro JL. Successfully treated but not fit for purpose: paying attention to chronic lung impairment after TB treatment. *Int J Tubercul Lung Dis* 2016;20:1010–4.
- [79] Cheng S, Chen W, Yang Y, Chu P, Liu X, Zhao M, et al. Effect of diagnostic and treatment delay on the risk of tuberculosis transmission in Shenzhen, China: an observational cohort study, 1993–2010. *PLoS One* 2013;8:e67516.
- [80] Virenfeldt J, Rudolf F, Camara C, Furtado A, Gomes V, Aaby P, et al. Treatment delay affects clinical severity of tuberculosis: a longitudinal cohort study. *BMJ open* 2014;4:e004818.
- [81] Khan R, Malik NI, Razaque A. Imaging of pulmonary post-tuberculosis sequelae. *Pak J Med Sci* 2020;36:S75–82.

- [82] Stek C, Allwood B, Walker NF, Wilkinson RJ, Lynen L, Meintjes G. The immune mechanisms of lung parenchymal damage in tuberculosis and the role of host-directed therapy. *Front Microbiol* 2018;9:2603.
- [83] Liu S, Chen Q, Liu J, Yang X, Zhang Y, Huang F. Sinomenine protects against *E. coli*-induced acute lung injury in mice through Nrf2-NF- $\kappa$ B pathway. *Bio-med Pharmacother* 2018;107:696–702.
- [84] Shahzad M, Shabbir A, Wojcikowski K, Wohlmuth H, C Gobe G. The antioxidant effects of Radix Astragali (*Astragalus membranaceus* and related species) in protecting tissues from injury and disease. *Curr Drug Targets* 2016;17:1331–40.
- [85] Bayram H, Bauer AK, Abdalati W, Carlsten C, Pinkerton KE, Thurston GD, et al. Environment, global climate change, and cardiopulmonary health. *Am J Respir Crit Care Med* 2017;195:718–24.
- [86] Lepeule J, Litonjua AA, Gasparrini A, Koutrakis P, Sparrow D, Vokonas PS, et al. Lung function association with outdoor temperature and relative humidity and its interaction with air pollution in the elderly. *Environ Res* 2018;165:110–7.
- [87] Salcedo PA, Lindheimer JB, Klein-Adams JC, Sotolongo AM, Falvo MJ. Effects of exercise training on pulmonary function in adults with chronic lung disease: a meta-analysis of randomized controlled trials. *Arch Phys Med Rehabil* 2018;99:2561–9. e7.
- [88] Paranjape SM, Barnes LA, Carson KA, von Berg K, Loosen H, Mogayzel Jr PJ. Exercise improves lung function and habitual activity in children with cystic fibrosis. *J Cyst Fibros* 2012;11:18–23.
- [89] Martin C, Aguilo N, Gonzalo-Asensio J. Vaccination against tuberculosis. *Enferm Infecc Microbiol Clin* 2018;36:648–56.
- [90] Hussey G, Hawkridge T, Hanekom W. Childhood tuberculosis: old and new vaccines. *Paediatr Respir Rev* 2007;8:148–54.
- [91] Darrah PA, Zeppa JJ, Maiello P, Hackney JA, Wadsworth MH, Hughes TK, et al. Prevention of tuberculosis in macaques after intravenous BCG immunization. *Nature* 2020;577:95–102.
- [92] Moliva JJ, Hossfeld AP, Sidiki S, Canan CH, Dwivedi V, Beamer G, et al. Selective delipidation of *Mycobacterium bovis* BCG enables direct pulmonary vaccination and enhances protection against *Mycobacterium tuberculosis*. *Mucosal Immunol* 2019;12:805–15.
- [93] Tameris MD, Hatherill M, Landry BS, Scriba TJ, Snowden MA, Lockhart S, et al. Safety and efficacy of MVA85A, a new tuberculosis vaccine, in infants previously vaccinated with BCG: a randomised, placebo-controlled phase 2b trial. *Lancet* 2013;381:1021–8.
- [94] King TH, Shanley CA, Guo Z, Bellgrau D, Rodell T, Furney S, et al. GI-19007, a novel *Saccharomyces cerevisiae*-based therapeutic vaccine against tuberculosis. *Clin Vaccine Immunol* 2017;24. e00245-17.
- [95] Gong W, Liang Y, Wu X. The current status, challenges, and future developments of new tuberculosis vaccines. *Hum Vaccines Immunother* 2018;14:1697–716.