

# Pectoral Fascia Preservation in Oncological Mastectomy to Reduce Complications and Improve Reconstructions: A Systematic Review

Jaco Suijker, MD\*  
 Yara L. Blok, MD\*  
 Ralph de Vries, MSc†  
 Monique P. van den Tol, PhD‡  
 Nicole M. A. Krekel, PhD§

**Background:** Excision of the pectoral fascia (PF) is routinely performed in oncological mastectomies. Preservation of the PF may, however, decrease postoperative complication rates for bleeding, infections, and seroma. It may also improve reconstructive outcomes by better prosthesis coverage, thereby reducing implant extrusion rates and improving cosmetic outcomes.

**Methods:** A systematic review according to the Preferred Reporting Items for Systematic Reviews and Meta-Analysis principles was performed. Studies describing PF preservation were searched in 3 databases. All studies including more than 10 patients were included. The main outcomes were oncological safety (local recurrence, regional and distant metastases, and mortality rates), complication rates (bleeding, infections, seroma), loss of the prosthesis after reconstructive surgery, and cosmetic outcomes following reconstruction.

**Results:** Five studies were included. Three reported on 2 different randomized controlled trials ( $n = 73$ , and  $n = 244$ ), and 2 studies were retrospective case series ( $n = 203$  and  $n = 256$ ). PF preservation did not affect oncological outcomes in terms of local recurrences, regional and distant metastases, or mortality rates. One study described a significantly lower incidence of seroma in the PF preservation group. No differences were found for bleeding complications and infections. No objective data were provided for reconstructive complications or cosmetic outcomes.

**Conclusions:** The literature on PF preservation is scarce. Based on the current evidence, PF preservation seems oncologically safe while potentially reducing postoperative complication rates. It is expected that reconstructive outcomes will benefit from PF preservation, but these studies lack evidence on this topic. Future studies should provide insight into all aspects of PF preservation. (*Plast Reconstr Surg Glob Open* 2020;8:e2700; doi: [10.1097/GOX.0000000000002700](https://doi.org/10.1097/GOX.0000000000002700); Published online 23 March 2020.)

## INTRODUCTION

Over the past decades, there has been a tendency toward less extensive oncological breast surgery. Mastectomy procedures changed from Halsted's radical mastectomy, including removal of the pectoralis major muscle (PM) toward the simple mastectomy, in which

the PM was preserved and only the pectoral fascia (PF) was resected. This resulted in less postoperative pain and better biomechanical outcomes.<sup>1-3</sup> Increased focus on long-term outcomes subsequently led to the introduction of skin and nipple-sparing mastectomies, as well as the emergence of breast-conserving surgery as an oncological equivalent alternative for mastectomy in many cases. Furthermore, the axillary lymph node dissection has been largely replaced by the sentinel node procedure.<sup>3-5</sup> Most of these changes are driven by the realization that more extensive surgery does not necessarily result in better oncological outcomes and may worsen long-term cosmetic results and quality of life.

Removal of the PF is still widely performed in the modified radical mastectomy and simple mastectomy. However, the necessity of this procedure is questionable. The PF is part of the muscular anatomy instead of the breast glandular tissue and, therefore, it seems theoretically of no oncological benefit to excise the PF except in those cases of tumor invasion in the PF. There is a strict adherence of the PF to the

From the \*Department of Surgery, Rode Kruis Ziekenhuis, Beverwijk, The Netherlands; †Medical Library, Amsterdam Medical Centre Location VUmc, Amsterdam, The Netherlands; ‡Department of Surgical Oncology, Amsterdam Medical Centre Location VUmc, Amsterdam, The Netherlands; and §Department of Plastic and Reconstructive Surgery, Leiden University Medical Centre, Leiden, The Netherlands.

Received for publication September 20, 2019; accepted January 21, 2020.

Copyright © 2020 The Authors. Published by Wolters Kluwer Health, Inc. on behalf of The American Society of Plastic Surgeons. This is an open-access article distributed under the terms of the [Creative Commons Attribution-Non Commercial-No Derivatives License 4.0 \(CCBY-NC-ND\)](https://creativecommons.org/licenses/by-nc-nd/4.0/), where it is permissible to download and share the work provided it is properly cited. The work cannot be changed in any way or used commercially without permission from the journal.

DOI: [10.1097/GOX.0000000000002700](https://doi.org/10.1097/GOX.0000000000002700)

**Disclaimer:** The authors have no financial interest to declare in relation to the content of this article.

underlying PM. No separating epimysium is present between the PF and the PM, in contrary to the deep fascia in many other body parts (limbs, thoracolumbar fascia, rectal sheet, and neck fasciae).<sup>6</sup> The PF and PM should, therefore, be viewed as one myofascial unit in which the PF has a role in proprioception, due to its many nerve endings. Therefore, excision of the PF is both from a functional and surgical technical point of view not the most obvious choice.<sup>7,8</sup>

It is hypothesized that preservation of the PF has several advantages. It may reduce postoperative bleeding complications by preventing injury to the PM itself. Studies showed that 50% of postoperative bleeding requiring reoperation following mastectomy originated from the PM.<sup>9</sup> Furthermore, PF preservation may decrease postoperative seroma formation due to its function in lymph drainage.<sup>10</sup> From a reconstructive point of view, the strong fibroelastic layer, although thin (mean thickness  $151 \pm 37 \mu\text{m}$ ), can be a valuable aid in implant coverage.<sup>8</sup> The previously described subfascial breast reconstructions that have been applied emphasize the strength of the PF as an extra layer covering the breast implant.<sup>11,12</sup> PF preservation may, therefore, reduce the rates of postoperative implant extrusion. Previous studies even described the use of the PF in the mediocaudal lower pole to improve projection, making direct-to-implant reconstruction possible instead of 2-stage breast reconstruction.<sup>7,13</sup> PF preservation may thereby expand reconstructive possibilities and improve cosmetic outcomes.

A systematic review of the literature was initiated to evaluate the current evidence for PF preservation. The main outcome measures were oncological safety, postoperative complications such as bleeding and seroma, reconstructive complications, and cosmetic outcomes.

## METHODS

### Search Strategy

A review protocol was developed based on the Preferred Reporting Items for Systematic Reviews and Meta-analysis-statement ([www.prisma-statement.org](http://www.prisma-statement.org)). A comprehensive search was performed in the bibliographic databases PubMed, Embase.com, and Wiley/Cochrane Library in collaboration with a medical librarian. Databases were searched from inception up to March 26, 2018.

The following terms were used (including synonyms and closely related words) as index terms or free-text words: “mastectomy,” “breast amputation,” “breast ablation,” “fasciectomy,” “fascia,” and “pectoral.” The search was performed without date, language, or publication status restriction. Duplicate articles were excluded. Cross-reference check was also performed on screened full-text articles.

### Study Selection

Two researchers used the blinded mode on rayyan.org, the systematic review web app, to identify all prospective and retrospective studies on PF preservation, regardless of whether or not a control group was made. Only studies written in English were included. Studies that did not describe preservation of the PF in relation

to complications or oncological outcomes were excluded. Case reports, case series with less than 10 patients, letters, and reviews were excluded as well.

All articles for which no consensus on exclusion or inclusion was reached initially were discussed. When no agreement was reached, the final decision was made in consultation with the third (senior) author. Details of the flow diagram of studies in this review are presented in [Figure 1](#).

### Outcomes

Oncological outcomes of interest were local recurrences, regional recurrences, distant metastasis, and mortality. Local recurrence was defined as the recurrence of malignant cells in the scar, in the skin surrounding the scar or on the chest wall after complete initial tumor removal. Regional recurrences, or regional metastases, were defined as metastases located in the ipsilateral axillary lymph nodes, internal mammary nodes, or infraclavicular nodes. Distant metastases were all tumor depositions located further away or not included in those defined as local or regional.

Complications of interest were postoperative bleeding, especially those cases requiring reoperation, seroma formation, infectious complications for which antibiotics were started or adjacent surgeries were required, and implant extrusion. Seroma formation was defined as any clinically detected collection of fluid anywhere along the skin incisions leading to discomfort.

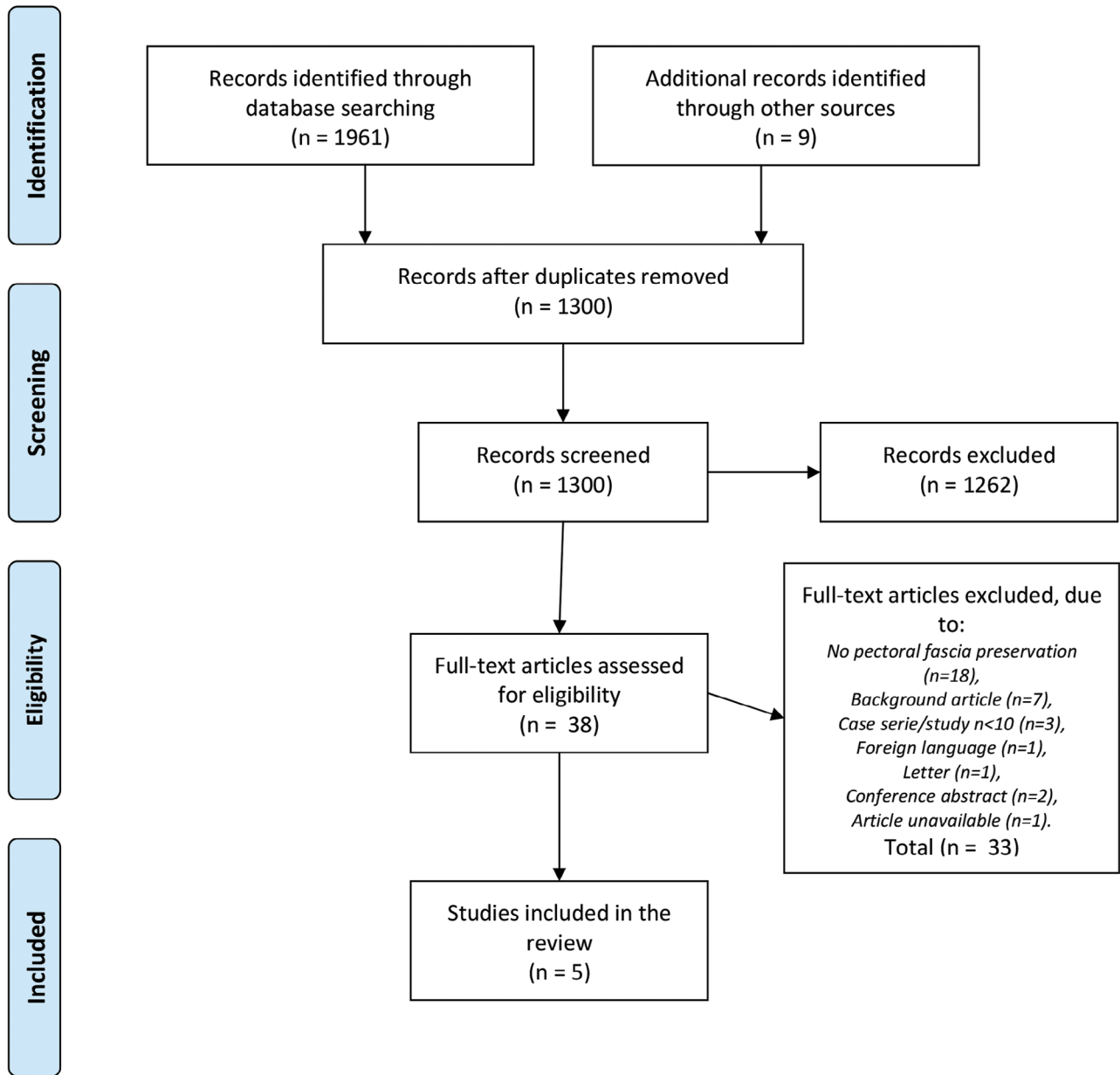
The cosmetic appearance of the breast after reconstruction as assessed by the surgeon was evaluated as well.

## RESULTS

### Study and Patient Characteristics

A total of 1,961 articles were identified. Nine possibly relevant articles were identified by cross-reference check. After removal of duplicates, 1,300 articles remained, and 38 were found to be possibly relevant after screening titles and abstracts. These 38 manuscripts were assessed for eligibility, of which 5 articles were included ([Fig. 1](#); [Table 1](#)).

Three articles reported outcomes of 2 randomized controlled trials (RCTs).<sup>10,14,15</sup> Two of those concerned the RCT reported by Dalberg et al,<sup>14,15</sup> with different lengths of follow-up. In this study  $n = 244$ , female patients were randomized to either mastectomy with PF preservation ( $n = 123$ ) or PF removal ( $n = 121$ ). Patients with invasive breast cancer ( $n = 227/91.9\%$ ) or Ductal Carcinoma in Situ (DCIS) ( $n = 20/8.9\%$ ) age 75 or younger and requiring a mastectomy were included. Exclusion criteria were inflammatory breast cancer or a tumor located close to the PF clinically or on mammogram. This “close relationship to the PF” was not further specified. The median follow-up was 11 years (10–14 years). This study was a cross trial, in which randomization for PF preservation versus PF removal also was randomized between short (1 day) or long (multiple days) axillary drainage. For the oncological outcomes, presented in both publications, the most recent publication was



**Fig. 1.** Flowchart according to the PRISMA principles describing the selection process of this systematic review of the literature towards pectoral fascia preservation in oncological mastectomy. PRISMA, Preferred Reporting Items for Systematic Reviews and Meta-analysis.

used.<sup>15</sup> The first publication was used for data on complications, because those were not reported in the most recent article.<sup>14</sup>

The other RCT was reported by Abdelhamid et al,<sup>10</sup> in which a total of 73 women with Grade 1 or 2 breast cancer were randomized into mastectomy with PF preservation or PF removal. The total follow-up was median 41 months (34–48 months). No data were provided for regional recurrences, distant metastasis, or mortality rates.<sup>10</sup>

Two of the included articles were retrospective case series.<sup>13,16</sup> Sandelin et al<sup>16</sup> described a total of 203 patients who received a mastectomy with PF preservation for ductal carcinoma (n = 113, 56%), lobular carcinoma (n = 21, 10%), or invasive (ductal or lobular) in combination with

DCIS (n = 69, 34%). No patients with inflammatory carcinoma were included. All underwent a standard or skin-sparing mastectomy followed by reconstruction, either with tissue expander, permanent implants, or transverse rectus abdominis muscle (TRAM) flap autologous reconstruction. The follow-up time was at least 5 years.<sup>16</sup>

Salgarello et al<sup>13</sup> reported the results of 220 patients receiving 256 mastectomies with PF preservation. All patients received an immediate one-stage reconstruction with a definitive prosthesis using the PF to cover the prosthesis in the lower pole. Tumor types were either invasive breast cancer (n = 234, 91.5%) or DCIS (n = 22, 8.5%). The length of the follow-up was relatively short with a mean of 29 months (range: 3 months–5 years).<sup>13</sup>

**Table 1. Study and Patient Characteristics of the 5 Included Studies**

Study Reference	Study Type	Country	No. Patients	Age; Mean (SD)	No. Mastectomies	Invasive Carcinoma, N (%)	Positive Lymph Nodes, N (%)	Inflammatory Carcinoma Included	Carcinoma Invading or Close to PF Included	Minimal Tumor Distance (mm)	Follow-up (y) Median (range)	Comments
Dalberg et al <sup>14</sup>	RCT	Sweden	247	58.1 (-)	247	227 (91.9%)	116 (51.1%)	No	No	—	>5 (-)	Cross trial 2 x 2 in which also was randomized for drain duration
Dalberg et al <sup>15</sup>	RCT	Sweden	244	58.2 (-)	244	224 (91.8%)	115 (51.3%)	No	No	—	11 (10–14)	Long-term outcomes of same group as RCT Dalberg et al <sup>14</sup>
Abdelhamid et al <sup>10</sup>	RCT	Egypt	73	56.7 (-)	73	73 (100%)	41 (56.2%)	No	No	5	— (2.8–4.0) Mean 3.4	
Sandelin et al <sup>16</sup>	Retrospective	Sweden	203	— (-) Median (range) 48 (23–70)	203	203 (100%)	61 (30.0%)	No	No	—	—	
Salgarello et al <sup>13</sup>	Retrospective	Italy	220	47.5 (-) (range) (25–72)	256	234 (91.4%)	140 (60%)*	No	—	—	2.4 (0.3–5)	

\*Forty percent had no indication for total axillary lymph node dissection after sentinel node procedure. Therefore, the described group of 140 (60%) patients who underwent total axillary lymph node dissection are expected to be the number of patients with positive lymph nodes.

**Oncological Outcomes**

In the RCT of Dalberg et al,<sup>15</sup> chest wall recurrences occurred in 18 patients (14.6%) in the PF preservation group, compared to 10 patients (8.3%) in the PF removal group, which was not statistically significant ( $P = 0.12$ ). No significant difference ( $P = 0.82$ ) in regional recurrences was observed, with 7 (5.7%) regional recurrences in the PF preservation group versus 8 (6.6%) in the PF removal group. No difference ( $P = 0.61$ ) in the occurrence of distant metastasis was observed with 39 (31.7%) in the PF preservation group versus 35 (28.9%) of  $n = 121$  patients in the PF removal group, and mortality rates were similar as well (43.1% versus 38.8%, respectively,  $P = 0.47$ ; Table 2).<sup>15</sup>

There were no local recurrences in both groups in the RCT by Abdelhamid et al.<sup>10</sup>

In the retrospective study of Sandelin et al,<sup>16</sup> locoregional recurrences were reported in 13 of 203 patients (6.4%), of which 9 (4.4%) were chest wall recurrences, and 4 (2.0%) were regional recurrences. Distant metastases were reported in 6 patients (3%). Thirty-one patients (15.4%) died due to advanced breast cancer.<sup>16</sup>

Salgarello et al<sup>13</sup> reported two chest wall recurrences (1.1%). No data on regional recurrences, distant metastasis, or mortality rates were provided.<sup>13</sup>

**Complications**

**Postoperative Bleeding**

Information on bleeding complications was provided in 2 publications.<sup>13,16</sup> In the study of Sandelin et al,<sup>16</sup> only the bleeding complications that required reoperation were reported, being 2 of  $n = 188$  patients (1.1%) who underwent implant reconstruction, and 3 of  $n = 13$  patients (23.1%) who underwent TRAM flap reconstruction, in which the location of the bleeding was not further specified.<sup>16</sup> Salgarello et al<sup>16</sup> reported the presence of postoperative hematoma in 6 of 256 (2.7%) mastectomies, of whom 4 (1.8%) required reoperation (Table 3).<sup>13</sup>

**Seroma**

Occurrence of seroma was compared between the 2 mastectomy groups in the trial by Dalberg et al,<sup>15</sup> in which seroma was defined as any clinically detected collection of fluid requiring aspiration in the axilla or anywhere along the skin incisions. Data on the occurrence of seroma were collected in 198 of the total of 244 patients in this trial. Of those in the PF preservation group, 31 out of 100 patients (31%) developed seroma versus 39 out of 98 patients (39.8%) in the PF removal group. This difference was not statistically significant ( $P = 0.20$ ).<sup>14</sup> Abdelhamid et al<sup>10</sup> reported a significant reduction of the incidence of seroma in the PF preservation group (5.6% versus 24.3%,  $P = 0.025$ ).<sup>10</sup> In the study by Salgarello et al,<sup>13</sup> 3 seromas were reported (1.3%). However, the definition of seroma was not provided in both studies. Sandelin et al<sup>16</sup> did not report on the occurrence of seroma.

**Infectious Complications**

Infectious complications were reported in 2 of the 5 included articles.<sup>13,16</sup> In the report by Sandelin et al,<sup>16</sup> 5 patients (2.7%) developed an infection, resulting in

**Table 2. Oncological Outcomes in the 5 Included Studies**

Study Reference	Local Recurrence			Regional Recurrence			Metastasis			Mortality		
	PF Preservation	PF Removal	P	PF Preservation	PF Removal	P	PF Preservation	PF Removal	P	PF Preservation	PF Removal	P
Dalberg et al <sup>4</sup>	n = 16 (12.8%)	n = 8 (6.6%)	0.09	n = 8 (6.4%)	n = 8 (6.6%)	0.99	n = 30 (24.0%)	n = 28 (23.0%)	0.73	n = 35 (28.0%)	n = 28 (23.0%)	0.37
Dalberg et al <sup>5</sup>	n = 18 (14.6%)	n = 10 (8.3%)	0.12	n = 7 (5.7%)	n = 8 (6.6%)	0.82	n = 39 (31.7%)	n = 35 (28.9%)	0.61	n = 53 (43.1%)	n = 47 (38.8%)	0.47
Abdelhamid et al <sup>10</sup>	n = 0 (0.0%)	n = 0 (0.0%)	1.0	—	—	—	—	—	—	—	—	—
Sandelin et al <sup>16</sup>	n = 9 (4.4%)	—	—	n = 5 (2.5%)	—	—	—	—	—	n = 31 (15.4%)	—	—
Salgarello et al <sup>13</sup>	n = 2 (1.1%)	—	—	—	—	—	—	—	—	—	—	—

**Table 3. Occurrence of Complications in 4 Studies Reporting on Complications**

Study Reference	Seroma		Postoperative Bleeding		Infection		Skin Slough/Necrosis	
	PF Preservation	PF Removal	P	PF Preservation	PF Removal	P	PF Preservation	PF Removal
Dalberg et al <sup>4</sup>	n = 31* (31.0%)	n = 39* (39.8%)	0.20	—	—	—	—	—
Abdelhamid et al <sup>10</sup>	n = 2 (5.6%)	n = 9 (24.3%)	0.025	—	—	—	—	—
Sandelin et al <sup>10</sup>	—	—	—	n = 2 (1.1%) †	—	—	n = 5 (2.7%) † implant loss n = 3 (1.6%)	—
Salgarello et al <sup>13</sup>	n = 3 (1.3%)	—	—	n = 6 (2.7%)	—	—	n = 13 (6.4%) implant loss n = 2 (0.9%)	n = 17 (8%)

\*Measured in the part of the total study sample also enrolled in the drainage trial. In the drainage, trial patients were randomized between axillary drainage <24 hours regardless of drain production (n = 99) or drainage until drain production <40 cc/24h (n = 99).

†Measured in the n = 188 with implant reconstruction. The n = 13 with TRAM reconstruction were left out of this table since it is impossible to know if complications are due to the mastectomy or TRAM reconstruction based on the current information provided.



3 cases (1.6%) of implant removal.<sup>16</sup> Salgarello et al<sup>13</sup> reported 13 wound infections (6.4%). In 2 cases (0.9%), reoperation with implant removal was required.

### Reconstructive Outcomes

Reconstructive outcomes were described in the retrospective case series by Salgarello et al.<sup>13</sup> These outcomes were not standardized, but based on the operator and other surgeons' perception of the cosmetic result. The reconstructive outcomes of all immediate reconstructions with a definitive prosthesis were found to be very good or good in 78.6%, acceptable in 14.0%, and poor in 7.3% of all cases. In 12 cases (5.4%), additional surgery was necessary to improve cosmetic results.

Abdelhamid et al<sup>13</sup> mentioned an improved aspect of the skin flaps after fascia preservation, but these statements were not based on any objective data.<sup>13</sup>

## DISCUSSION

This systematic review was performed to provide a comprehensive overview of the current literature concerning preservation of the fascia over the PM. Relevant outcomes were assessed, including oncological outcomes, complications and reconstructive results. The systematic (Preferred Reporting Items for Systematic Reviews and Meta-analysis) method that was used for this systematic review leads to a complete overview of the current literature concerning PF preservation. Unfortunately, the number of studies on PF preservation is low. Moreover, the current studies are heterogeneous and patient groups included are relatively small.

The RCT by Dalberg et al<sup>14,15</sup> reported no significant difference in local recurrences. It should be mentioned that the differences reported might have become significant if more patients were included. On the other hand, there were no cases of local recurrence in both groups in the RCT by Abdelhamid et al, and local recurrence rates were low in both retrospective case series being 4.5% at 5-year FU and 1.1% at 29 months (3 months–5 years).<sup>10,13,16</sup>

Obviously, tumor invasion into the PF increases the risk of developing local recurrence when preserving the PF, and a risk factor for tumor invasion into the PF is the proximity of the tumor to the PF.<sup>17–20</sup> Unfortunately, no definite data are available for the minimal safe distance from the tumor to PF. Dalberg et al<sup>14,15</sup> described that PF removal was performed when the tumor was infiltrating the PF or located close to the PF, but no definition of “close” was provided. The actual distance from the tumor to the PF may be a key factor in determining whether or not to remove the PF. Several studies have shown that PF invasion can occur when tumors are located within 5 mm of the PF and is less likely to occur with more than 5 mm distance.<sup>19,20</sup> The study of Abdelhamid et al<sup>10</sup> supports this view of tumor to PF distance as an important factor. In all cases, the tumor to PF distance was at least 5 mm, and no locoregional recurrences occurred in both study arms ( $P = 1.0$ ).<sup>10</sup> In support of this is also the fact that the PF is preserved in almost all lumpectomies without resulting in inferior oncological outcomes, except for when the tumor is located too close to the PF.<sup>21</sup> Based on the current literature, it can be stated that with

proper patient selection—in terms of minimal (more than 5 mm) tumor distance to the PF—the effect of PF preservation on locoregional recurrence is not clinically relevant and routine removal of the PF does not seem evident.<sup>20,22</sup> It is recommended to remove the PF at the tumor site when the tumor is located within 5 mm of the PF, to obtain clear margins. Direct macroscopic invasion of the PF warrants not just removal of the PF but also removal of a portion of the underlying muscle. Furthermore, postmastectomy radiation therapy should be considered in these cases.

The 10-year incidence of regional metastasis after mastectomy has previously been reported to be 3.8%.<sup>23</sup> The observed 5.7% in the PF preservation group and 6.6% in the PF removal group in the study by Dalberg et al<sup>14,15</sup> are somewhat higher. However, multiple factors influence these recurrence rates, including tumor stage at the time of the operation, tumor biology, and adjuvant therapy. More importantly, no significant difference was observed between the 2 treatment arms. Sandelin et al<sup>16</sup> reported a low incidence of 2.0% regional recurrences. Based on these data, there are no indications that preservation of the PF leads to higher rates of regional recurrence, distant metastasis, or mortality.<sup>15</sup> These oncological outcomes seem reasonable, because multiple studies showed that breast cancer is a systemic disease from the start without any influence of the *status localis* on the systemic outcomes of distant metastasis and mortality.<sup>21,24,25</sup>

The amount of bleeding complications requiring reoperation was 1.1% and 1.8%.<sup>13,16</sup> These data are in concordance or lower when compared with the previously described 1.0%–3.9% in simple mastectomy with direct reconstruction.<sup>9,26,27</sup> It seems reasonable that preservation of the PF decreases the incidence of postoperative bleeding complications requiring reoperation, because 50% of postoperative bleeding complications requiring reoperation have been found to originate from the PM (caused by dissection on the surface of the well-vascularized muscular tissue).<sup>9</sup>

Seroma is a burdensome problem for patients and caregivers, often leading to multiple additional hospital visits. The incidence of seroma differs widely in the literature, and studies' report ranges from 3 to 85%.<sup>28</sup> These wide ranges are probably caused by the various definitions that are given to the complication “seroma,” for example, in terms of drainage days or seroma requiring a reoperation. Salgarello et al<sup>13</sup> reported an incidence of 1.2% in their study, but these rates could be an underestimation being a retrospective analysis without a primary focus on seroma rates. The results from the RCTs are more suitable to answer the question if PF preservation lowers the incidence of seroma. In Dalberg et al<sup>14,15</sup> RCT, the incidence of seroma was slightly lower in the PF preservation arm (31% versus 39.8%), but these differences were not statistically significant. In the RCT by Abdelhamid et al,<sup>10</sup> a significant lower incidence of seroma formation was observed in the PF preservation group of 5.6% versus 24.3%. Unfortunately, no definition of seroma was provided in this study.<sup>10</sup>

Better coverage of the prostheses by PF preservation may theoretically lower the infection rates as well as the rates of implant extrusion.<sup>7,13</sup> There is a 3.8% incidence of infectious complications in breast surgery in general (including

mastectomy and lumpectomy).<sup>29</sup> Higher rates of infections have been reported for mastectomies, ranging from 5.3% to 8.9%,<sup>30–32</sup> and of 6.0% of all patients undergoing a mastectomy with tissue expander placement.<sup>33</sup> In the studies by Sandelin et al and Salgarello et al, the occurrence of infections after mastectomy with PF preservation was 2.7% and 6.4%, respectively. The rates of implant extrusion of 1.6% and 0.9% in studies by Sandelin et al and Salgarello et al, respectively, are lower than the least (1.9%) reported in the literature.<sup>34</sup> However, based on these two studies, no definite conclusions can be drawn on these topics.

By removing the fascia, the oncologic surgeon may also compromise the underlying muscle to a certain extent. This may cause a risk for implant extrusion, but may also result in localized and irregular bulging of the muscle as expansion occurs. Unfortunately, there are very little data about assessing the esthetic results with and without the fascia being preserved.

The cosmetic outcomes reported were based on the subjective surgeons' and their colleagues' opinions. These data do not seem to be sufficient to answer the question if PF preservation leads to better reconstructive outcomes.<sup>13</sup> Abdelhamid et al<sup>10</sup> only described an improvement of skin flap appearance after PF preservation, but did not provide any information on how this was tested. Future studies should focus on the objective assessment of the effect of PF preservation on reconstructive outcomes.

Additional advantages of PF preservation reported were decreased intraoperative blood loss, decreased operative time, decreased drain output, and decreased time to drain removal.<sup>10</sup> However, these are results from only one study, and the techniques and drainage protocols may differ from other centers.

A frequently heard argument to promote PF resection is that it facilitates pathological examination of the dorsal margins. However, in our experience, the PF is rarely identified microscopically and it is not likely that a preserved fascia will lead to more false-positive margins.<sup>14,16</sup>

## CONCLUSIONS

Although breast cancer surgery is increasingly focusing on less extensive procedures, the need for a standard removal of the PF during mastectomy has not frequently been questioned nor studied. The studies described are heterogenic with relatively small patient groups. Based on the current literature, PF preservation seems to be an oncologically safe procedure, especially when the tumor is located at a safe distance from the PF.

Preservation of the PF might decrease the postoperative seroma formation. It may also decrease bleeding complications, infection rates, and the rates of implant extrusion while improving cosmetic outcomes. However, the current literature lacks evidence on these topics. More studies are required to systematically assess all relevant outcomes.

Jaco Suijker, MD

Department of Surgery

Red Cross Hospital

Vondellaan 13, 1942 LE, Beverwijk

The Netherlands

E-mail: jsuijker@rkz.nl.

## ACKNOWLEDGMENTS

We would like to note our appreciation to those that contributed to this report but do not qualify as authors. First of all to Marcel J.G. Andriessen and M. Elma van Rossen, since conversations with them about this subject triggered the initiation of this study. We also want to thank Annabeth de Vries and Anouk Pijpe for their support and the fact they facilitated in providing time to work on this study.

## REFERENCES

- Halsted WS. I. The results of operations for the cure of cancer of the breast performed at the Johns Hopkins Hospital from June, 1889, to January, 1894. *Ann Surg.* 1894;20:497–555.
- Patey DH, Dyson WH. The prognosis of carcinoma of the breast in relation to the type of operation performed. *Br J Cancer.* 1948;2:7–13.
- Zurrida S, Bassi F, Arnone P, et al. The changing face of mastectomy (from mutilation to aid to breast reconstruction). *Int J Surg Oncol.* 2011;2011:980158.
- Kennedy CS, Miller E. Simple mastectomy for mammary carcinoma. *Ann Surg.* 1963;157:161–162.
- Cody HS III. Sentinel lymph node mapping in breast cancer. *Breast Cancer.* 1999;6:13–22.
- Stecco C, Macchi V, Porzionato A, et al. The fascia: the forgotten structure. *Ital J Anat Embryol.* 2011;116:127–138.
- Vallejo da Silva A, Rodriguez FR, Loures CM, et al. Mastectomy in the era of implant-based reconstruction: should we be removing the pectoralis fascia? *Breast.* 2012;21:779–80.
- Stecco A, Masiero S, Macchi V, et al. The pectoral fascia: anatomical and histological study. *J Bodyw Mov Ther.* 2009;13:255–261.
- Seth AK, Hirsch EM, Kim JY, et al. Hematoma after mastectomy with immediate reconstruction: an analysis of risk factors in 883 patients. *Ann Plast Surg.* 2013;71:20–23.
- Abdelhamid MI, Alkilany MM, Lofty M. Pectoral fascia preservation during modified radical mastectomy: why and when. *Egypt J Surg.* 2017;36:333–5.
- Jinde L, Jianliang S, Xiaoping C, et al. Anatomy and clinical significance of pectoral fascia. *Plast Reconstr Surg.* 2006;118:1557–1560.
- Benito-Ruiz J, Raigosa M, Manzano M, et al. Subfascial breast augmentation: thickness of the pectoral fascia. *Plast Reconstr Surg.* 2009;123:31e–32e.
- Salgarello M, Barone-Adesi L, Terribile D, et al. Update on one-stage immediate breast reconstruction with definitive prosthesis after sparing mastectomies. *Breast.* 2011;20:7–14.
- Dalberg K, Johansson H, Signomklao T, et al. A randomised study of axillary drainage and pectoral fascia preservation after mastectomy for breast cancer. *Eur J Surg Oncol.* 2004;30:602–609.
- Dalberg K, Krawiec K, Sandelin K. Eleven-year follow-up of a randomized study of pectoral fascia preservation after mastectomy for early breast cancer. *World J Surg.* 2010;34:2539–2544.
- Sandelin K, Wickman M, Billgren AM. Oncological outcome after immediate breast reconstruction for invasive breast cancer: a long-term study. *Breast.* 2004;13:210–218.
- Fowble B, Gray R, Gilchrist K, et al. Identification of a subgroup of patients with breast cancer and histologically positive axillary nodes receiving adjuvant chemotherapy who may benefit from postoperative radiotherapy. *J Clin Oncol.* 1988;6:1107–1117.
- Katz A, Strom EA, Buchholz TA, et al. The influence of pathologic tumor characteristics on locoregional recurrence rates following mastectomy. *Int J Radiat Oncol Biol Phys.* 2001;50:735–742.
- Nakao K, Miyata M, Aono T, et al. Cancer cell emboli in the pectoral lymphatics of patients with breast cancer. *Jpn J Surg.* 1989;19:392–397.

20. Vallejo da Silva A, Rodriguez FR, Lopes VG. Oncological safety of pectoralis fascia preservation in modified radical mastectomies. *Int J Cancer Res.* 2015;49:1626–30.
21. Veronesi U, Cascinelli N, Mariani L, et al. Twenty-year follow-up of a randomized study comparing breast-conserving surgery with radical mastectomy for early breast cancer. *N Engl J Med.* 2002;347:1227–1232.
22. Ahlborn TN, Gump FE, Bodian C, et al. Tumor to fascia margin as a factor in local recurrence after modified radical mastectomy. *Surg Gynecol Obstet.* 1988;166:523–526.
23. Clemons M, Danson S, Hamilton T, et al. Locoregionally recurrent breast cancer: incidence, risk factors and survival. *Cancer Treat Rev.* 2001;27:67–82.
24. van Dongen JA, Bartelink H, Fentiman IS, et al. Randomized clinical trial to assess the value of breast-conserving therapy in stage I and II breast cancer, EORTC 10801 trial. *J Natl Cancer Inst Monogr.* 1992;11:15–8.
25. Fisher B, Anderson S, Bryant J, et al. Twenty-year follow-up of a randomized trial comparing total mastectomy, lumpectomy, and lumpectomy plus irradiation for the treatment of invasive breast cancer. *N Engl J Med.* 2002;347:1233–1241.
26. Manning AT, Sacchini VS. Conservative mastectomies for breast cancer and risk-reducing surgery: the Memorial Sloan Kettering Cancer Center experience. *Gland Surg.* 2016;5:55–62.
27. Winther Lietzen L, Cronin-Fenton D, Garne JP, et al. Predictors of re-operation due to post-surgical bleeding in breast cancer patients: a Danish population-based cohort study. *Eur J Surg Oncol.* 2012;38:407–412.
28. Kumar S, Lal B, Misra MC. Post-mastectomy seroma: a new look into the aetiology of an old problem. *J R Coll Surg Edinb.* 1995;40:292–294.
29. Platt R, Zucker JR, Zaleznik DF, et al. Perioperative antibiotic prophylaxis and wound infection following breast surgery. *J Antimicrob Chemother.* 1993;31 Suppl B:43–48.
30. Hoefler RA Jr, DuBois JJ, Ostrow LB, et al. Wound complications following modified radical mastectomy: an analysis of perioperative factors. *J Am Osteopath Assoc.* 1990;90:47–53.
31. Wagman LD, Tegmeier B, Beatty JD, et al. A prospective, randomized double-blind study of the use of antibiotics at the time of mastectomy. *Surg Gynecol Obstet.* 1990;170:12–16.
32. Lipshy KA, Neifeld JP, Boyle RM, et al. Complications of mastectomy and their relationship to biopsy technique. *Ann Surg Oncol.* 1996;3:290–294.
33. Sue GR, Sun BJ, Lee GK. Complications after two-stage expander implant breast reconstruction requiring reoperation: a critical analysis of outcomes. *Ann Plast Surg.* 2018;80(5S Suppl 5):S292–S294.
34. Darragh L, Robb A, Hardie CM, et al. Reducing implant loss rates in immediate breast reconstructions. *Breast.* 2017;31:208–213.