

Rare case of superior vesical fissure with hypospadias: variants of classic bladder exstrophy

Sudhir Singh , Jiledar Rawat, Nitin Pant

To cite: Singh S, Rawat J, Pant N. Rare case of superior vesical fissure with hypospadias: variants of classic bladder exstrophy. *World Jnl Ped Surgery* 2023;6:e000552. doi:10.1136/wjps-2022-000552

Received 9 January 2023
Accepted 26 April 2023

Rare variants of bladder exstrophy are pseudo-exstrophy, covered exstrophy, duplicate exstrophy, superior vesical fissure, visceral sequestration, and omphalocele, exstrophy of the cloaca, imperforate anus, and spinal defects syndrome. They comprise 10% of all cases of the exstrophy–epispadias complex.¹ Here, we managed a 1-year-old male child who presented with a 2.5 cm diameter mucosal opening in the hypogastric region, draining urine through it. The child also had distal penile hypospadias with a stenotic meatus through which he passed urine. The prepuce was hooded, and there was no chordee. On inserting a small-caliber feeding tube through the stenotic meatus, it is visible through the hypogastric region defect. A low-lying umbilicus was present (figure 1A,B). Widening of the symphysis pubis both clinically and on an X-ray was present. There was a divergence of the rectus abdominis muscle. Both testes were in the scrotum. He was continent of urine. Blood investigations were normal, including

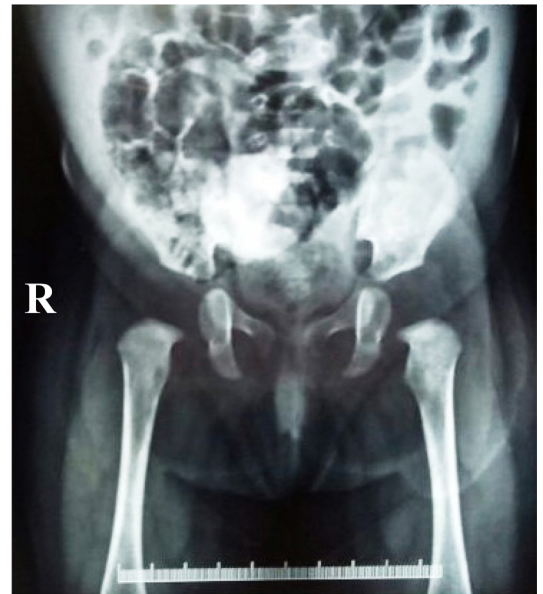

Figure 2 Cystogram (radiograph of the bladder with contrast, not properly visualized as not holding the contrast). R, right.

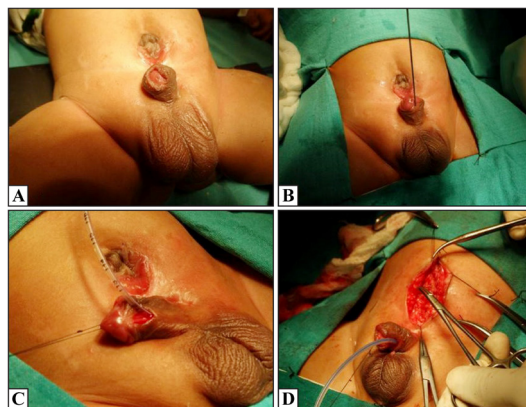
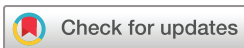

Figure 1 Clinical and operative pictures of the case of superior vesical fissure with hypospadias. (A) Low-set umbilicus and hypospadias meatus. (B) Hypospadias meatus. (C) Picture showing hypospadias meatus, meatotomy performed. (D) Intraoperative view showing repair of abdominal wall after repair of the bladder.

serum creatinine, and ultrasonography of the bilateral kidney and ureter was normal. The anatomy of the bladder was studied preoperatively via contrast study, although the bladder was open and not holding the contrast, so proper VCUG (voiding cystourethrogram) was not possible to perform at that time (figure 2). At 1 year of age, the child was planned for surgical correction. A circumferential bladder fissure incision with a lower abdominal midline incision was made; the upper part of the bladder was mobilized extraperitoneal. The bladder was repaired in two layers, and then the rectus muscle was approximated in the midline. Meatotomy was performed because of the stenotic meatus (figure 1C,D). The patient tolerated closure well. The child developed a right inguinal hernia at follow-up. The second surgery was performed at 2 years of age. Snodgrass repair for hypospadias along with right inguinal hernia was performed. The child was doing



© Author(s) (or their employer(s)) 2023. Re-use permitted under CC BY-NC. No commercial re-use. See rights and permissions. Published by BMJ.

Pediatric Surgery, King George's Medical University, Lucknow, Uttar Pradesh, India

Correspondence to

Dr Sudhir Singh; drsudhir_singh25@yahoo.in



well at the 2-year follow-up. The outcome in these cases of continence and renal function is better, as no bladder neck is involved and bladder capacity and compliance are good.

The exstrophy–epispadias complex occurs due to mechanical disruption or enlargement of the cloacal membrane during embryonic life, and the timing of the rupture causes varied presentation. Animal models of the exstrophy–epispadias complex summarized that agenesis of the dorsal part of the cloacal membrane may form the basis of congenital malformations of cloaca-derived orifices, such as hypospadias, epispadias, bladder, and cloacal exstrophy, double urethra, and cloacal membrane agenesis, although hypospadias is not described with exstrophy bladder.² Hypospadias associated with an exstrophy variant is rare, with only one prior report that is associated with pseudo-exstrophy. Jindal *et al* reported that a 2-month-old child presented with an exposed bladder plate at the hypogastrium, which looked like a classic exstrophy–epispadias complex. As in our case, diastasis of the pubis and divergence of the rectus abdominis muscle were present, and both testes were in the scrotal position. The baby also had a hypospadias urethral opening. This urethral opening was draining the underlying normal bladder located posterior to the exstrophy bladder patch.³ In this case, the hypospadias is associated with a superior vesical fissure, which is the first case in the literature. This is the congenital anomaly of a variant of bladder exstrophy involving the urinary system, musculoskeletal system, pelvic floor, abdominal wall, and genitalia, as in this case of hypospadias.

Contributors SS—contributions to the conception, analysis, and interpretation of data, revising it critically, final approval, and accountability for all aspects. JR—conception, analysis, interpretation of data, revising it critically, and final approval. NP—conception, analysis, interpretation of data, revising it critically, and final approval.

Funding The authors have not declared a specific grant for this research from any funding agency in the public, commercial or not-for-profit sectors.

Competing interests None declared.

Patient consent for publication Parental/guardian consent obtained.

Ethics approval This study involves human participants and has been approved by the hospital ethics committee. Participants gave informed consent to participate in the study before taking part.

Provenance and peer review Not commissioned; externally peer reviewed.

Data availability statement No data are available.

Open access This is an open access article distributed in accordance with the Creative Commons Attribution Non Commercial (CC BY-NC 4.0) license, which permits others to distribute, remix, adapt, build upon this work non-commercially, and license their derivative works on different terms, provided the original work is properly cited, appropriate credit is given, any changes made indicated, and the use is non-commercial. See: <http://creativecommons.org/licenses/by-nc/4.0/>.

ORCID iD

Sudhir Singh <http://orcid.org/0000-0003-4419-214X>

REFERENCES

- 1 Lowentritt BH, Van Zijl PS, Frimberger D, *et al*. Variants of the exstrophy complex: a single institution experience. *J Urol* 2005;173:1732–7.
- 2 van der Putte SCJ. Normal and abnormal development of the anorectum. *Journal of Pediatric Surgery* 1986;21:434–40.
- 3 Jindal B, Kumar KL, Jagdish S. Duplicate bladder exstrophy with hypospadias: a rare exstrophy variant with unusual association. *J Indian Assoc Pediatr Surg* 2017;22:192–3.