

## RARE CASE OF A HETEROZYGOUS MICRODELETION 9q21.11-q21.2: CLINICAL AND GENETIC CHARACTERISTICS

Ivanov HY<sup>1,\*</sup>, Stoyanova V<sup>1,2</sup>, Ivanov I<sup>1,2</sup>, Linev A<sup>1,2</sup>,  
Vazharova R<sup>3,4</sup>, Ivanov S<sup>4</sup>, Balabanski L<sup>4</sup>, Toncheva D<sup>4,5</sup>

**\*Corresponding Author:** Dr. Hristo Y. Ivanov, Department of Pediatrics and Medical Genetics, Medical University Plovdiv, Vasil Aprilov 15-A Str., Plovdiv 4002, Bulgaria. Tel: +359-884-827-070. Fax: +359-326-022-338. E-mail: doctorhristoivanov@yahoo.com

### ABSTRACT

Intellectual disability is affecting 3.0-4.0% of the general population. Copy number variants (CNVs) are a significant cause leading to neurodevelopmental disorders such as intellectual disability, epilepsy, autism spectrum disorders and developmental delay. The use of single nucleotide polymorphism (SNP)-array and array comparative genomic hybridization (aCGH) as diagnostic tools has led to the recognition of new microdeletion/microduplication syndromes associated with neurodevelopmental disorders. It is also useful for further characterization of marker chromosomes. Here, we report a girl with mild intellectual disability and mild facial dysmorphism. Cytogenetic analysis showed a marker chromosome in some percent of the cells and was followed by SNP-array karyotyping that detected, in addition, a 9655 Mb *de novo* interstitial deletion at 9q21.1-9q21.2.

**Keywords:** Deletion at 9q21.1; Interstitial deletion; Single nucleotide polymorphism (SNP)-array.

### INTRODUCTION

Copy number variants (CNVs) are a significant cause leading to neurodevelopmental disorders such as intellectual disability, epilepsy, autism spectrum disorders and developmental delay. Up to 3.0-4.0% of the general population is affected by intellectual disability, which makes it one of the most common neurological disorders [1]. Intellectual disability has been observed in patients carrying chromosomal aberrations or gene mutations.

Boudry-Labis *et al.* [2] proposed a novel microdeletion syndrome, involving a deletion at 9q21.13 and presenting with intellectual disability, speech delay, epilepsy, and characteristic facial features. They have reported 13 patients [2]. The range of the deletion spanned from 2.2 to 12.6 Mb and included a different number of genes. Here, we report a girl with mild intellectual disability, speech delay and mild facial dysmorphism with 9q21.11-q21.2 microdeletion of about 9655 Mb in size.

### CLINICAL REPORT

The proband is a 10-year-old girl. She was referred to us for genetic consultation because of mild intellectual disability, speech delay and mild facial dysmorphism.

She was born full-term to non consanguineous healthy parents after an uneventful pregnancy with no evidence of asphyxia. At birth, weight, length, and head circumference were normal. There was no relevant family history. She had a history of global developmental delay in infancy. She walked at the age of 2 years. She said her first words at 18

<sup>1</sup> Department of Pediatrics and Medical Genetics, Medical University Plovdiv, Plovdiv, Bulgaria

<sup>2</sup> Department of Medical Genetics, University Hospital "St. George," Plovdiv, Bulgaria

<sup>3</sup> Department of Biology, Medical Genetics and Microbiology, Sofia University "St. Kliment Ohridski," Sofia, Bulgaria

<sup>4</sup> Department of Genomics, Hospital "Dr. Malinov," Sofia, Bulgaria

<sup>5</sup> Department of Medical Genetics, Medical University Sofia, Sofia, Bulgaria

months of age and her first short sentence at the age of 2 years. At the age of 6 she was admitted to the hospital to establish a diagnosis regarding her developmental delay and short stature. She attends a mainstream school with teacher aide support.

On examination, her height was 135 cm, weight 29 kg and head circumference 53.2 cm. She had an elongated face with a prominent chin, broad forehead, arched bushy eyebrows and long eyelashes. She had hypertelorism and the palpebral fissures were down-slanting. Her nose had a broad prominent root. Her palate was narrow and highly arched. She had a thin upper lip, long philtrum, dystrophic teeth and excessive salivation. She had pes planus with large feet and short toes (Figure 1). After a walk of kilometer and a half she complained of cramp (pain) in her calves. A consultation with a child psychologist showed a mild intellectual disability (IQ ~55, Wechsler Intelligence Scale for Children was used), cognitive deficits in attention with reduced volume, stability and concentration. Memory: difficulty in remembering and reproducing information. Thinking: clearly, figuratively. Cranial computed tomography (CT) scans and ultrasound of internal organs were performed and were normal.

Cytogenetic analysis was performed on cultured lymphocytes and skin fibroblasts by G-banding according to standard procedures. The SNP-array karyotyping was performed using microarray Illumina Human CytoSNP-12 (Illumina Inc., San Diego, CA, USA). The microchip contains a total of number of 301,232 SNP variants representative of the entire human genome. Genomic positions refer to the Human Genome February 2009 assembly (GRCh37/hg19).

Cytogenetic analysis revealed a low-level mosaicism in blood and skin of the girl with a cell line carrying a small additional marker ring chromosome:  $\text{mos}47,XX,+mar[4]/46,XX[96]$  (lymphocytes) and  $\text{mos}47,XX,+mar[16]/46,XX$

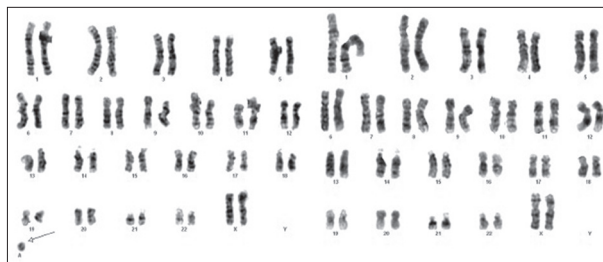


Figure 2. Karyotype of the proband.

[84] (skin fibroblasts). The mother had a normal karyotype. Chromosomal analyses of the father could not be carried out due to his lack of consent. (Figure 2).

For further characterization of the found marker chromosomes we applied SNP-array of genomic DNA from buccal swab, which showed a heterozygous partial deletion of the long arm of the chromosome 9 with size of about 9655 Mb. The deletion encompasses 43 human genes (Figure 3). To clarify the origin of the marker chromosome we offered fluorescent *in situ* hybridization (FISH) analysis, but the mother refused.

## DISCUSSION

Here, we report a girl with a 9655 Mb *de novo* deletion at 9q21.11-q21.2 presenting with mild intellectual disability, speech delay and characteristic facial features. Review of the literature showed that only 13 patients with a micro-deletion 9q21 have been reported [2,3]. The clinical symptoms observed in our patient are similar to those seen in the other patients with a deletion at 9q21.11-q21.2. In the cases described by Boudry-Labis *et al.* [2], they found mental retardation and speech delay in all patients, autistic behaviour, epilepsy and mild facial dysmorphism

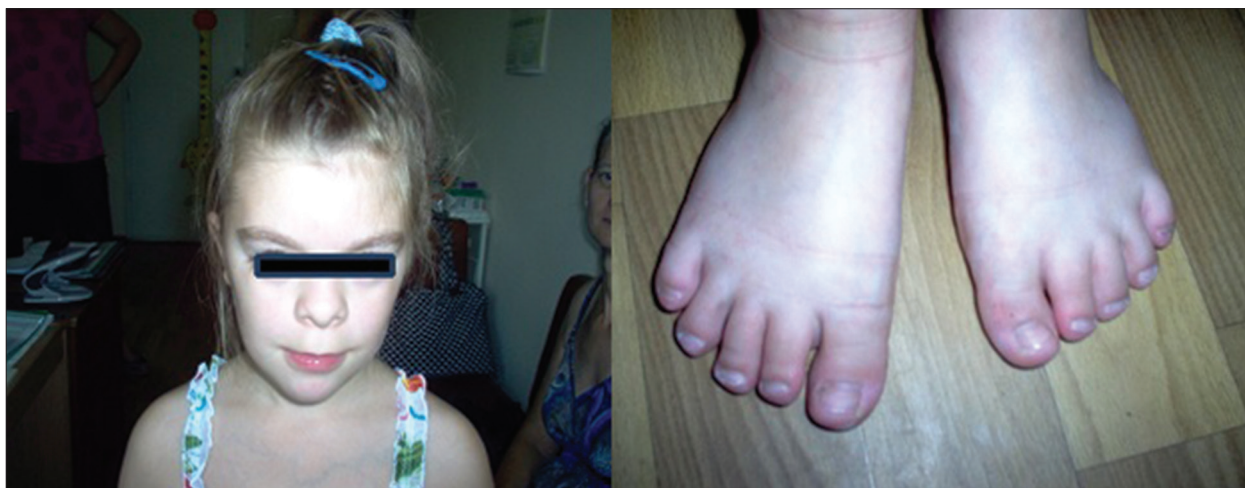

Figure 1. Phenotype of the proband.





lum, retina and spinal cord [11]. Recent studies suggested this gene as candidate gene to susceptibility to Alzheimer's disease and intellectual disability [11].

The *PCSK5* gene is involved in transmitting of the nerve signals and is highly expressed in the nervous system, especially in the spinal cord and in the pineal gland. A recent study reported that zebra fish embryos lacking the coorthologue of the *PCSK5* gene, *PC5.1*, have abnormal deposition of the neuromast within the lateral line system and have an abnormal touch response. This is consistent with the knowledge that the lateral line plays a role in the sensing the environment and in spatial awareness [12].

Mutations in the *TRPM6* gene are associated with hypomagnesemia with secondary hypocalcemia (OMIM 602014). These patients presented with generalized convulsions or signs of increased neuromuscular excitability, such as muscle spasms or tetany, which can explain our patient's complaint of pain in the calves. In agreement with Boudry-Labis *et al.* [2], we could speculate that among the genes of the interstitial deletion at 9q21.11-q21.2, *RORβ*, *PRUNE2*, *PCSK5* and *TRPM6* could best explain the phenotype of our patient, characterized by mild intellectual disability and characteristic facial features.

In conclusion we can say that this case illustrates the need to implement high resolution methods in patients with intellectual disability and mild dysmorphism. Moreover, the genes associated with intellectual disability may warrant further investigation.

**ACKNOWLEDGMENTS**

Published with a grant under Project № BG-05M2OP001-2.009-0025, "Doctoral training at MU-Plodiv for Competence, Creativity, Originality, Realization and Academism in Science and Technology - 2 (DOCTORANT - 2)", funded under the Operational Programme "Science and Education for Smart Growth", co-funded by the Structural and Investment Funds of the EU

**Declaration of Interest.** The authors report no conflicts of interest. The authors alone are responsible for the content and writing of this article.

**REFERENCES**

1. Leonard H, Wen X. The epidemiology of mental retardation: Challenges and opportunities in the new millennium. *Ment Retard Dev Disabil Res Rev.* 2002; 8(3): 117-134.
2. Boudry-Labis E, Demeer B, Le Caignec C, Isidor B, Mathieu-Dramard M, Plessis G, *et al.* A novel micro-

- deletion syndrome at 9q21.13 characterised by mental retardation, speech delay, epilepsy and characteristic facial features. *Eur J Med Genet.* 2013; 56(3): 163-170.
3. Baglietto Mg, Caridi G, Gimelli G, Mancardi M, Prato G, Ronchetto P, *et al.* RORB gene and 9q21.13 mi-crodeletion: Report on a patient with epilepsy and mild intellectual disability. *Eur J Med Genet.* 2014; 57(1): 44-46.
4. Liehr T, Claussen U, Starke H. Small supernumerary marker chromosomes (sSMC) in humans. *Cytogenet Genome Res.* 2004; 107(1-2): 55-67.
5. Azadi S, Zhang Y, Caffè AR, Holmqvist B, Van Veen T Thyroid-β2 and the retinoid RAR-α, RXR-γ and RORβ2 receptor mRNAs; expression profiles in mouse retina, retinal explants and neocortex. *Neuroreport.* 2002; 13(6): 745-750.
6. Nakagawa Y, O'Leary DD. Dynamic patterned expression of orphan nuclear receptor genes RORα and RORβ in developing mouse forebrain. *Dev Neurosci.* 2003; 25(2-4): 234-244.
7. Andre E, Conquet F, Steinmayr M, Stratton SC, Porciatti V, Becker-Andre M. Disruption of retinoid-related orphan receptor β changes circadian behavior, causes retinal degeneration and leads to vacillans phenotype in mice. *EMBO J.* 1998b;17(14):3867-3877.
8. Masana MI, Sumaya IC, Becker-Andre M, Dubocovich ML. Behavioral characterization and modulation of circadian rhythms by light and melatonin in C3H/HeN mice homozygous for the RORβ knockout. *Am J Physiol Regul Integr Comp Physiol.* 2007; 292(6): R2357-R2367.
9. Mcgrath CL, Glatt SJ, Sklar P, Le-Niculescu H, Kuczenski R, Doyle AE, *et al.* Evidence for genetic association of RORB with bipolar disorder. *BMC Psychiatry.* 2009; 9:70.
10. Ersland Km, Christoforou A, Stansberg C, Espeseth T, Mattheisen M, Mattingsdal M, *et al.* Gene-based analysis of regionally enriched cortical genes in GWAS data sets of cognitive traits and psychiatric disorders. *PLoS One.* 2012; 7(2): e31687.
11. Potkin SG, Guffanti G, Lakatos A, Turner JA, Krugel F, Fallon JH, *et al.* Hippocampal atrophy as a quantitative trait in a genome-wide association study identifying novel susceptibility genes for Alzheimer's disease. *PLoS One.* 2009; 4(8): e6501.
12. Chitramuthu BP, Baranowski DC, Cadieux B, Rouselet E, Seidah NG, Bennett HP. Molecular cloning and embryonic expression of zebra fish PCSK5 co-orthologues: Functional assessment during lateral line development. *Dev Dyn.* 2010; 239(11): 2933-2946.