

1983;309:1482-5.

8. Long RG, Bryant MG, Mitchell SJ, Adrian TE, Polak JM, Bloom SR. Clinicopathological study of pancreatic and ganglioneuroblastoma tumours secreting vasoactive intestinal polypeptide (vipomas). *Br Med J* 1981; 282:1767 – 71.
9. Massironi S, Sciola V, Peracchi M, Ciafardini C, Spampatti MP, Conte D. Neuroendocrine tumors of the gastro-entero-pancreatic system. *World J Gastroenterol* 2008 , 21; 14(35): 5377-84.
10. Nikou GC, Toubanakis C, Nikolaou P, Giannatou E, Safioleas M, Mallas E, Polyzos A. VIPomas: an update in diagnosis and management in a series of 11 patients. *Hepatogastroenterology*. 2005 Jul-Aug;52(64):1259-65.
11. Soga J, Yakuwa Y. Vipoma/diarrheogenic syndrome: a statistical evaluation of 241 reported cases. *J Exp Clin Cancer Res*. 1998;17(4):389-400.
12. Yao JC, Hassan M, Phan A, Dagohoy C, Leary C, Mares JE, Abdalla EK. One hundred years after "carcinoid": epidemiology of and prognostic factors for neuroendocrine tumors in 35.825 cases in the United States. *J Clin Oncol* 2008; 26:3063-72.

**ABCDDV/1043**

ABCD Arq Bras Cir Dig Letter to the Editor  
2014;27(3):224-225

## PRIMARY RETROPERITONEAL MUCINOUS CYSTADENOMA - CASE REPORT

*Cistadenoma mucinoso retroperitoneal primário - relato de caso*

Marco Aurelio **SANTO-FILHO**, Ramiro **COLLEONI**, David Carlos **SHIGUEOKA**, Ricardo **ARTIGIANI**, Milton **SCALABRINI**, Gaspar de Jesus **LOPES-FILHO**

From the Disciplina de Gastroenterologia Cirúrgica, Escola Paulista de Medicina - UNIFESP (Surgical Gastroenterology Service, Paulista School of Medicine - UNIFESP), São Paulo, SP, Brazil

### Correspondence:

Marco Aurelio Santo Filho  
Email: aureliosanto@uol.com.br

Financial source: none  
Conflicts of interest: none

Received for publication: 17/06/2013  
Accepted for publication: 13/05/2014

## INTRODUCTION

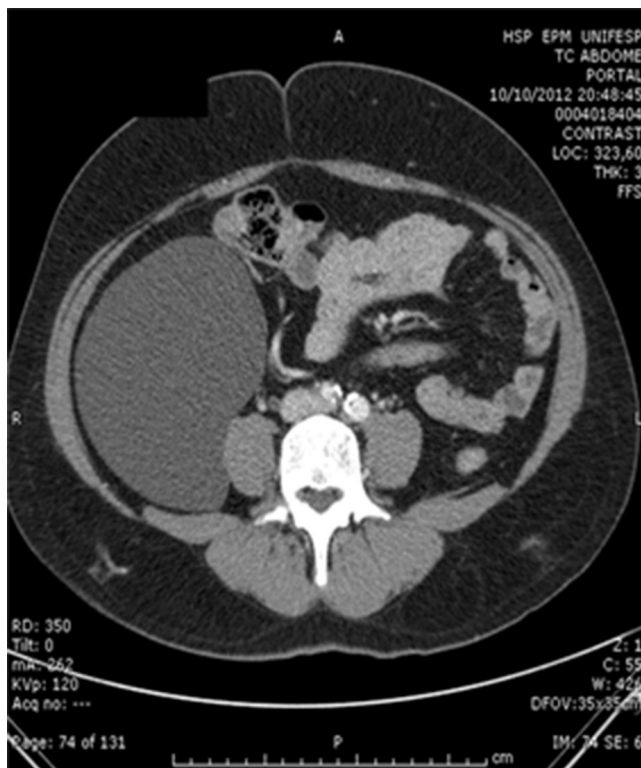
The primary retroperitoneal cystadenoma is very rare tumor, described by Handfield-Jones in 1924 and observed almost exclusively in women<sup>1</sup>. The symptoms are usually nonspecific, hampering its differential diagnosis with other retroperitoneal masses and makes them with imaging and surgical approach for diagnosis and treatment<sup>2</sup>.

The present report is of one case of a primary benign retroperitoneal mucinous cystadenoma.

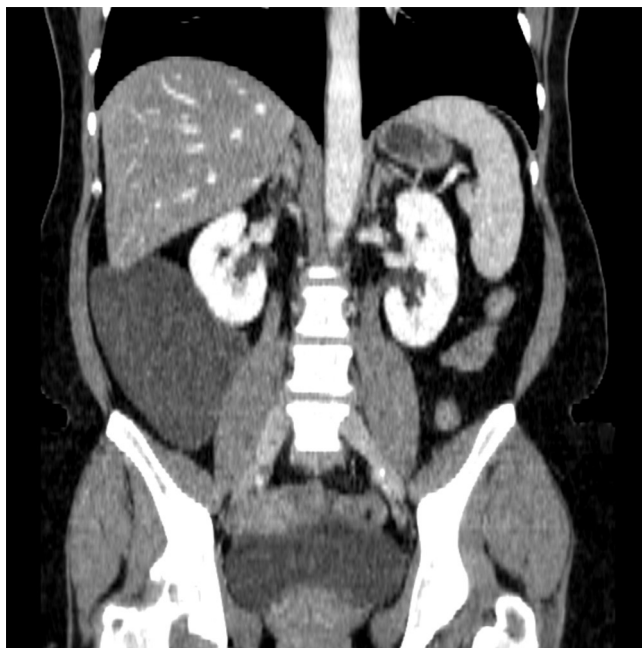
## CASE REPORT

Woman 51 year old referred abdominal pain since one year ago, located on the right flank and radiating to the lumbar region, with progressive worsening. Physical examination revealed a palpable mass in the right flank, painless. Was submitted to ultrasound examination which identified a bulky abdominal cystic lesion. Computed tomography (Figures 1 and 2) revealed homogeneous retroperitoneal cystic lesion measuring 15x12, 5x5, 5 cm and medially displacing the ascending colon, suggesting the diagnosis of cystic lymphangioma. The patient underwent exploratory laparotomy (Figures 3 and 4),

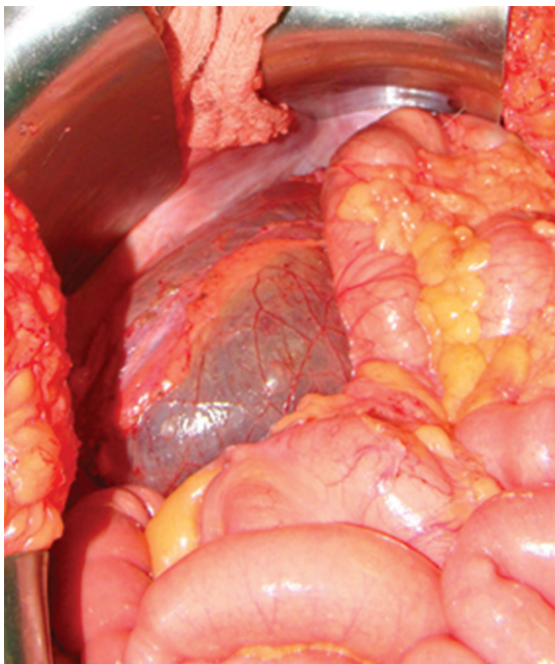
which identified massive retroperitoneal cystic lesion which was dissected from adjacent structures with ease, allowing complete resection. The pancreas and ovaries showed no alterations or contiguity with the injury. No complications were observed during the postoperative course. Pathological examination of the surgical specimen revealed retroperitoneal mucinous cystadenoma benign (Figures 5 and 6).



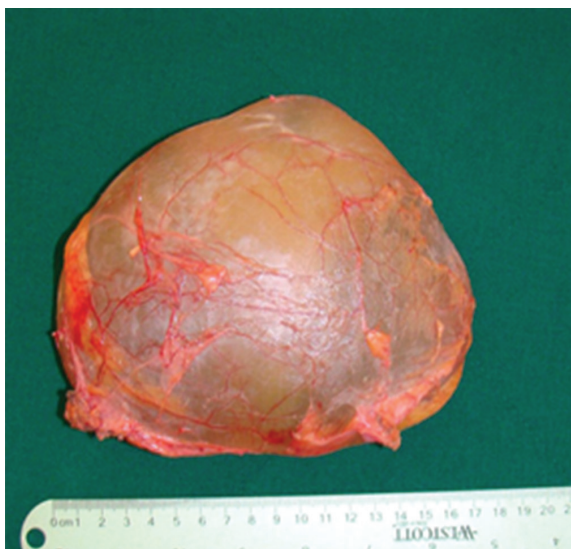**FIGURE 1** - Computed tomography of the abdomen: shows a cystic image of regular walls without mural nodules or vegetations



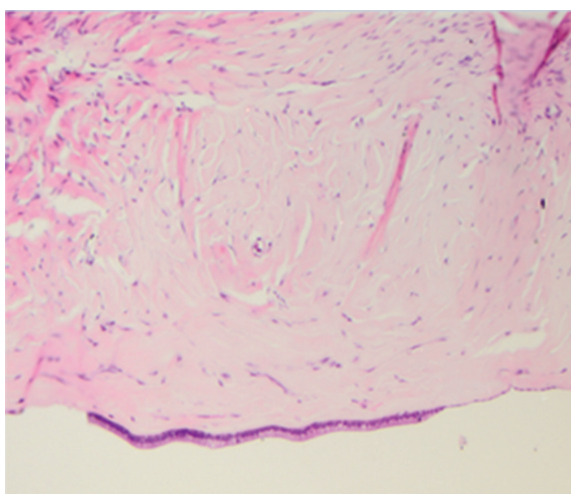
**FIGURE 2** - Computed tomography of the abdomen: shows massive retroperitoneal cystic lesion occupying the right flank and iliac fossa



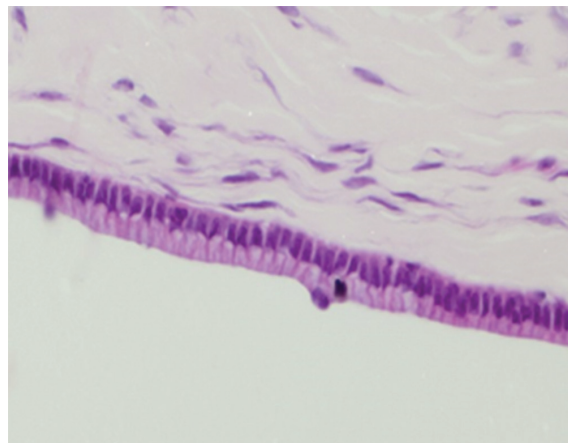
**FIGURE 3** - Intraoperative aspect: bulky retroperitoneal cystic lesion medially displacing the ascending colon



**FIGURE 4** - Surgical aspect: cystic lesion fully and completely resected



**FIGURE 5** - The cyst wall (hematoxylin and eosin, 100x)



**FIGURE 6** - Wall of the cyst: goblet cells without tissue invasion, characterizing benign cyst (hematoxylin and eosin - 400x)

## DISCUSSION

Most patients have a palpable mass, asymptomatic or accompanied by mild abdominal pain that may be associated with nonspecific gastrointestinal complaints<sup>2</sup>. The differential diagnosis must be made with cystic lymphangioma, cystic teratoma, cystic neoplasms of the pancreas and ovary. The assessed by CT or MRI identifies retroperitoneal cystic lesion, but does not define its exact nature<sup>3</sup>; so, confirmation of the diagnosis can be established only after histological examination of the surgical specimen. Thus, the surgical approach is indicated for proper evaluation of the topography and resection of the lesion.

Histologically primary retroperitoneal mucinous cystadenoma can be classified in three types: benign, borderline and malignant<sup>4</sup>. Benign, the most common, with no recurrence after surgical resection; borderline, with adjacent proliferative columnar epithelium and small malignant potential; malignant, which can be recurrent and metastatic<sup>5</sup>. It shares histological similarities with ovarian mucinous cystadenoma and can be located anywhere in the retroperitoneum without connections to the ovary. The histogenesis remains incompletely understood. However, there are two main assumptions. According to the first, as there is similarity with ovarian mucinous cystadenoma, it is possible originated from an ectopic ovarian tissue<sup>6</sup>; however, ovarian tissue was found in the cyst wall only in few cases<sup>7</sup> and have been described in men<sup>8</sup>. The second hypothesis suggests that they originate from an invagination of multipotent mesothelial cells with subsequent mucinous metaplasia of the mesothelial cells<sup>6</sup>.

Complete surgical resection of the lesion, as well as allowing adequate diagnostic evaluation, represents the best treatment<sup>9</sup>.

## REFERENCES

1. Calo PG, Congiou A, Ferrelli C, Nikolosi A, Tarquin A. Primary retroperitoneal tumors. Our experience. *Minerva Chirurgica* 1994;49:43-9.
2. Roma AA, Malpica A: Primary retroperitoneal mucinous tumors: a clinicopathologic study of 18 cases. *AmJ Surg Pathol* 2009;33:526-33.
3. Falidas E, Konstandoudakis S, Vlachos K, Archontovasilis F, Mathioulakis S, Boutzouvis S et al. Primary retroperitoneal mucinous cystadenoma of borderline malignancy in a male patient. Case report and review of the literature. *World Journal of Surgical Oncology* 2011;9:98.
4. Navin P, Meshkat B, McHugh S, Beegan C, Leen E, Prins H, Aly S. Primary retroperitoneal mucinous cystadenoma — A case study and review of the literature. *International Journal of Surgery Case Reports* 3 2012;486-488.

5. Min BW, Kim JM, Um JW, Lee ES, Son GS, Kim SJ et al. The First Case of a Retroperitoneal Mucinous Cystadenoma in Korea: A Case Report. *The Korean Journal of Internal Medicine* 2004;19:282-284.
6. Matsubara M, Shiozawa T, Tachibana R, Hondo T, Osasda K, Kawaguchi K, et al. Primary retroperitoneal mucinous cystadenoma of borderline malignancy: a case report and review of the literature. *International Journal of Gynecological Pathology* 2005;24:218-23.
7. Pennell TC, Gusdon Jr JP. Retroperitoneal mucinous cystadenoma. *American Journal of Obstetrics and Gynecology* 1989;160:1229-31.
8. Lai KKT, Chan YJR, Chin ACW, Ng WF, Huang YHH, Mak YLM, et al. Primary retroperitoneal mucinous cystadenoma in a 52-year-old man. *Journal of Hong Kong College Of Radiologists* 2004;7:223-5.
9. Tapper EB, Shrewsbury AB, Oprea G, Majmudar B. A unique benign mucinous cystadenoma of the retroperitoneum: a case report and review of the literature. *Archives of Gynecology and Obstetrics* 2010;281:167-9.

ABCDDV/1044

ABCD Arq Bras Cir Dig Letter to the Editor  
2014;27(3):226-226

## MIRIZZI SYNDROME: A SURGICAL CHALLENGE

*Síndrome de Mirizzi: um grande desafio cirúrgico*

Patrícia de Souza **LACERDA**, Manuel Rios **RUIZ**,  
Ana **MELO**, Leonardo Simão **GUIMARÃES**,  
Rubem Alves da **SILVA-JUNIOR**, Gerson Suguiyama **NAKAJIMA**

From the Clínica Cirúrgica, Hospital Universitário Getúlio Vargas, Universidade Federal do Amazonas (Surgical Clinic, Getúlio Vargas Hospital, Federal University of Amazonas), Manaus, AM, Brazil

### Correspondence

Gerson S. Nakajima

E-mail: gnakajima@ufam.edu.br

Financial source: none

Conflicts of interest: none

Received for publication: 10/04/2013

Accepted for publication: 25/03/2014

## INTRODUCTION

The Mirizzi syndrome consists of the obstruction either of the common hepatic duct or the choledocus, secondary to the extrinsic compression due to the impact of calculus in the cystic duct or in the gallbladder infundibulum<sup>4</sup>. The first description is due to Pablo Mirizzi (1948), when he observed some factors which could cause extra hepatic cholestasis in certain groups of patients carrying cholelithiasis<sup>9</sup>. It generally occurs in female with advanced age. Depending on the degree of involvement of the biliary tract, the patients may be grouped into five distinct groups according to the new rating of the Mirizzi syndrome<sup>1,6</sup>.

The goal of this report is to present a case of a patient carrying type IV, surgically treated through the laparotomy approach.

## CASE REPORT

A 56-year-old woman was admitted into the Service of Surgery of Getúlio Vargas Hospital with history of pain in the right hypochondrium with dorsal irradiation, daily evening fever during three months, and a previous episode of choloria lasting 10 days. The physical examination of admission was normal; laboratory tests demonstrated transaminases changes: glutamic oxalacetic transaminase: 75U/L and glutamic pyruvic transaminase: 62U/L; and the canalicular enzymes: alkaline phosphatase: 1924 U/L, and gama

glutamyl transferase: 884 U/L; the bilirubins were normal. The abdomen ultrasound showed cholelithiasis, bile duct of increased caliber measuring 1.7 cm, showing the "double barreled" with the portal vein, with presence of hyperechoic image measuring 1.1 cm, compatible with calculus; intra-hepatic biliary tract had normal sonographic appearance. The magnetic cholangiography showed cholelithiasis with intra and extra-hepatic biliary tract dilation up to the level of the distal common bile duct, which measured 1.6 cm.

The patient underwent surgical procedure through the laparotomy approach with right subcostal incision. Intraoperatively, there were adhesions of the transverse colon, duodenum and stomach in the gallbladder, which was found to be scleroatrophic and full of calculus. It was decided to perform anterograde cholecystectomy (Torek's). During the procedure, it was observed the presence of fistula between the gallbladder infundibulum and the choledocus, with erosion of its entire anterior wall covering from the implantation of the cystic duct to the proximity of the duodenum, which was classified as type IV Mirizzi. Choledococopy through the fistula was performed with flexible choledocoscope, and a single calculus in the distal choledocus, was identified and removed. The irrigation of the biliary tract with physiological saline solution without elimination of additional calculus, and endside choledocojejunal anastomosis in Roux-en-Y was performed with ligature of the distal choledocus. The peritoneal cavity was drained with latex laminar drain. The diet was released on the second day after surgery, with good acceptance. The drain debit oscillated between 20 and 755 ml, showing bilious secretion until the 10<sup>th</sup> day, when it was removed due to the volume reduction. The patient was discharged on the 12<sup>th</sup> day after surgery.

## DISCUSSION

Mirizzi syndrome is a rare complication and it occurs approximately on 0.5 to 4% of the patients carrying cholelithiasis. It's more frequent on women between 21 to 90 years old, probably a reflection of the gallstones preponderance in this group. It is the complication of long standing cholecistolithiasis<sup>5,6</sup>.

The constant compression of the calculus associated to the inflammation of the involved structures may result in fistula between the gallbladder infundibulum or the cystic duct, and the extra hepatic biliary tract. In the cholecystobiliary fistula, the calculus may migrate to the main biliary tract, while in the coloentericystic fistula the patient may show intestinal obstruction called biliary ileus<sup>9</sup>.

The importance of the recognition the Mirizzi syndrome derives from the high risk of lesions of the biliary duct during the surgical procedures. Summing up to this fact is the difficulty for the preoperative diagnosis because there is no specific clinic and laboratory presentation<sup>4,7,10</sup>. The most frequent signs and symptoms are abdominal pain followed by jaundice and cholangitis. Nausea, vomits, choluria, itch, hepatomegaly and, less frequently, acute pancreatitis, gallbladder perforation and weight loss<sup>3,4,5,8</sup>.

The Mirizzi syndrome, which was previously classified into four types, currently the coloentericystic fistula is being included in as complication (type V)<sup>1</sup> (Figure 1). The types are: I) extrinsic compression of the common/choledocus hepatic duct by calculus in the gallbladder infundibulum or cystic duct; II) presence of cholecystoenteric biliary fistula with erosion of the diameter less than 1/3 of the common/choledocus hepatic duct circumference; III) presence of cholecystoenteric biliary fistula with a diameter bigger than 2/3 of the common/choledocus hepatic duct circumference; IV) presence of cholecystoenteric biliary fistula involving the entire common/choledocus hepatic duct circumference; V) any type, plus cholecystoenteric biliary fistula (Va - without biliary ileus, and Vb - with biliary ileus).