




Effectiveness of ultrasound screening in right upper quadrant pain: A comparative study in a basic emergency service

Sérgio Miravent¹  | Manuel Lobo²  | Teresa Figueiredo³  | Carmen Jiménez⁴ | Rui Almeida⁵ 

¹Algarve Regional Health Administration, Shared Assistance Resources Unit (URAP) - Basic Emergency Service of Vila Real de Santo António, Higher Health School, University of Algarve, Faro, Portugal

²Local Health Unit of the Northeast, Polytechnic Institute of Castelo Branco, International Society of Clinical Ultrasound (SIEC), Medical Imaging and Radiotherapy Portuguese Association (APIMR), Bragança, Portugal

³Algarve Integrated Diagnostic Centre, University of Algarve, Faro, Portugal

⁴University Hospital Center of Algarve and Basic Emergency Service of Vila Real de Santo António, Faro, Portugal

⁵Medical Imaging and Radiotherapy Department, Center for Health Studies (CES-ESSUALG) and CHRC (Comprehensive Health Research Center), APIMR Secretary, University of Algarve, Faro, Portugal

Correspondence

Manuel Lobo, Local Health Unit of the Northeast, Polytechnic Institute of Castelo Branco, International Society of Clinical Ultrasound (SIEC), Medical Imaging and Radiotherapy Portuguese Association (APIMR), Bragança, Portugal.
Email: manuel_lobo@ipcb.pt

Abstract

Background and Aims: The use of ultrasound screening is primarily facilitated by point-of-care ultrasound (POCUS) and its integration into healthcare systems is a result of the versatility of this imaging technique. This study intends to compare the accuracy and pertinence of sonographic findings obtained by a sonographer in a Basic Emergency Service (BES) with that of radiologists at referral hospital (RH) in Portugal.

Methods: Twenty patients with right upper quadrant (RUQ) pain and suspected cholecystitis or biliary pathology underwent sonography screening using POCUS in the BES. They were then forwarded to the RH where a radiologist performed a conventional ultrasound exam on the same patients. The results of both exams were compared to determine if the findings obtained in the BES were confirmed by the radiologist in the RH.

Results: In our sample, 60% of cases were related to biliary pathology, 20% were liver-related, 10% had hepatopancreatic biliary etiology, and 10% had unknown etiology. A strong association between the sonographic findings in the BES and the RH was found in the variables “Sonographic Murphy sign” ($V = 0.859$; $p = 0.001$), “Cholelithiasis/Gallbladder sludge” ($V = 0.840$; $p = 0.001$), and “Intrahepatic biliary tract dilatation” ($V = 0.717$; $p = 0.006$). Adequate measures of agreement between the findings of the radiographer and radiologist were obtained for the “Sonographic Murphy sign” ($k = 0.664$; $p = 0.001$) and the presence of “Cholelithiasis/Gallbladder sludge” ($k = 0.712$; $p = 0.000$).

Conclusion: Major biliary abnormalities were detected in patients with RUQ pain in BES using sonography. The correlation between the sonographic findings obtained by the sonographers at BES and those obtained by radiologists at the RH in Portugal was strong, showing that POCUS screening could be extended to other similar settings; however, more studies are needed.

KEYWORDS

abdominal pain, patients, POCUS, radiologists, screening, sonographers, ultrasound

This is an open access article under the terms of the Creative Commons Attribution-NonCommercial License, which permits use, distribution and reproduction in any medium, provided the original work is properly cited and is not used for commercial purposes.

© 2023 The Authors. *Health Science Reports* published by Wiley Periodicals LLC.

1 | INTRODUCTION

The utilization of sonography, specifically point-of-care ultrasound (POCUS), in a Basic Emergency Service (BES) setting has been shown to aid clinical decisions that can be lifesaving.^{1–4} It is evident that a diverse range of healthcare professionals are increasingly incorporating POCUS into patient screening practices.^{5–8} However, some radiologists remain skeptical about its benefits for patients.^{6,7,9} Therefore, it would be useful to assess the accuracy of POCUS findings made in a prehospital context, where there are no radiologists available. Although there have been studies demonstrating substantial agreement between sonographic evaluations performed by trained sonographers and radiologists,^{10–13} final diagnoses must always be made or validated by a radiologist. In the absence of a radiologist in the BES, POCUS examinations are usually conducted by a sonographer, who is a radiographer with academic and clinical training in ultrasound. This reflects the current reality of POCUS usage in the context of our study. The primary aim of employing POCUS in our specific context is to identify abnormalities and gather diagnostic information that could guide us toward a suspicion of a specific clinical pathology and facilitate appropriate referral to a central hospital when deemed necessary.

Acute cholecystitis is a leading cause of right upper quadrant (RUQ) pain¹⁴ and is consistently diagnosed with higher sensitivity through POCUS compared to other bedside investigations.¹⁵ The RUQ can have a diverse range of etiologies, and approximately one-third of patients exhibit a clinically positive Murphy sign or sonographic Murphy sign when undergoing RUQ pain assessment using a probe.^{16,17} This condition is a common cause of hospital admission and contributes to 3%–10% of all cases of abdominal pain.¹⁸ In nearly 95% of cases, cholecystitis is associated with cholelithiasis.¹⁹

Cholecystitis is a multi-etiology pathology with a wide range of sonographic presentations, which can be primarily divided into calculous and acalculous forms.²⁰ The primary diagnostic criterion for sonography is the presence of the sonographic Murphy sign in association with gallstones. Secondary signs of acute cholecystitis include mural thickening greater than 3 mm, stratification, distension, or hydropic gallbladder, and pericholecystic fluid.²¹ Elevated white blood cell (WBC) count²² and symptoms such as nausea and vomiting may also be present.²³

Patients presenting with a wide range of conditions and severity levels may present to this peripheral emergency department (ED) in Southern Portugal, which faces limitations in diagnostic technology and the absence of radiologists. Furthermore, this particular BES is located 60 km from the referral hospital (RH), requiring a minimum travel time of 45 min to reach it. In this resource-limited setting, the implementation of POCUS in the BES has proven to be an innovative tool on initial patient screening and assessment.

Therefore, this study aimed to evaluate the accuracy of sonographic findings of abnormalities in the BES that prompted made the patients referral to RH. The focus will be on a common and frequent pathology in the right upper abdominal quadrant, such as cholecystitis, and suspected biliary diseases.

2 | METHODS

2.1 | Sample and instruments

The data for this cross-sectional study was collected from a sample of 35 patients at a peripheral BES located in southern Portugal, covering a period from 2016 to June 2022. The sonographic exams in the BES were performed using a Toshiba Némio XG ultrasound equipment with a convex probe, while the exams at the RH were performed by radiologists using a General Electric S8 with three different probes (linear, convex, and micro-convex). The data was descriptively analyzed using Microsoft Office Excel version 2019, and statistical analysis and correlation tests between variables were performed using IBM SPSS Statistics version 28 software. The sonographic images and their reports were retrieved from the local Picture Archiving and Communication System (PACS) and reporting digital clinical systems.

From an initial sample of 191 abdominal ultrasounds performed on patients presenting with nonspecific abdominal pain or acute abdomen, 35 ultrasound examinations were selected based on the presence of RUQ pain and either a positive or doubtful sonographic Murphy sign. The inclusion criteria for the study were: (I) RUQ pain, (II) clinical suspicion of cholecystitis or biliary pathology, (III) presence or doubtful sonographic Murphy sign during ultrasound procedure, (IV) sonographic screening performed in the BES by a radiographer/sonographer, (V) conventional sonography performed by a radiologist in the RH under the same emergency episode, (VI) retrieval of sonography images and respective radiologist reports from the PACS, and (VII) retrieval of the patient's clinical process.

From the initial 35 selected patients, 15 were excluded for not fulfilling 1 or more of the predefined inclusion criteria.

2.2 | Statistical analysis

Descriptive statistical analysis (percentages and frequencies) was performed for the variables under study (Table 1). Cramer's V test was used to measure association between variables and Cohen's Kappa coefficient was employed to measure interrater reliability among sonography performers, both for a 95% confidence interval.

2.3 | Ultrasound protocols covered in the study

The acquisition of the sonographic images followed a specific and systematic abdominal protocol²⁴ to ensure thorough coverage of all organs intended to be studied in each examination. The protocol was adaptable based on the patient's condition/cooperation and the sonographic findings, considering the appearance of any abnormalities during the examination. The ultrasound findings or images and the corresponding clinical assessments were considered and documented as in the Figure 1.

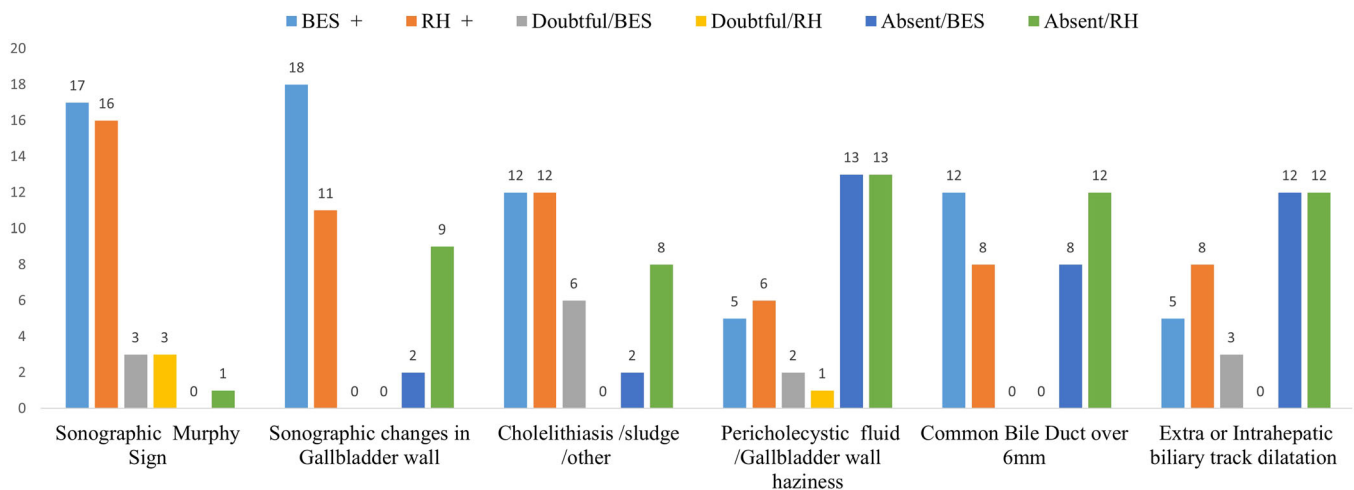
In recent years, there have been several studies which have proposed updated normal values for gallbladder wall thickness

TABLE 1 Category/variable evaluation and options for classification.

Category criteria in data evaluation	Option for classification
Exam place	BES or RH
Sonographic Murphy sign	Present, absent, or doubtful
Sonographic changes in gallbladder wall	Present, absent, or doubtful
Cholelithiasis/gallbladder sludge	Present, absent, or doubtful
Pericholecystic fluid or hazy wall delineation	Present, absent, or doubtful
Common bile duct measure above 6 mm	Present, doubtful, and absent means no measure was done or the measure was inferior to 6 mm
Intra or extrahepatic biliary tract dilation	Present, absent, or doubtful
Pathology suggestion by radiologist	Present or absent
Cholecystitis suggestion by radiologist	Present or absent
Cholestasis suggestion by radiologist	Present or absent
Pancreatitis suggestion by radiologist	Present or absent
High white blood cell count	Present, normal, absent information

Abbreviations: BES, basic emergency service; RH, referral hospital.

Sonographic variables and respective results

**FIGURE 1** Sonographic findings/variables comparing BES versus RH. (BES - Basic Emergency Service; RH- Referral Hospital).

(GBWT) and common bile duct (CBD) diameter. The values of 3.5²⁵ and 7 mm,^{26,27} respectively, have been reported. However, in this study, the most widely cited and conservative values were used as normal ranges. A GBWT of 3 mm was considered normal^{28,29} and a CBD diameter of 6 mm was used as the upper limit of normality.^{30,31}

In the category of "Sonographic Changes in Gallbladder Wall," radiologists at the RH often do not measure the GBWT, instead opting for descriptive analysis that characterizes the wall thickening. Thus, in this study, we combined the data from RH's positive measurements over 3 mm and positive qualitative assessments of gallbladder wall thickening.

In the category of "Pericholecystic Fluid or Hazy Wall Delineation," we used the older concept in ultrasonography of "hazy wall

definition"³² or "pericholecystic haziness,"³³ which is more evident on older sonography equipment like the one used in the BES.

All ultrasound examinations were conducted by a single radiographer/sonographer, who collected and recorded on a data file built for that purpose. The sonographer performed, analyzed, and classified the ultrasound results using the criteria outlined in Figure 1. Together with the BES physician, some patients were referred to the RH for further evaluation. However, due to the lack of connection of the ultrasound equipment with the PACS, it wasn't possible to send sonographic images from BES to the RH. The only information that the RH radiologists had regarding the initial screening performed at the BES was a brief report written by the BES physician indicating any deviations from normal findings observed during the POCUS examination.

3 | RESULTS

The final sample size of this study consisted of 20 patients, with 5 (25%) being male and 15 (75%) being female. The average age of the patients was 65 years. Abdominal radiographs were performed on 15 (75%) of the patients, and only in 1 patient (7%) was an image possibly related to biliary tract pathology observed. The WBC count was obtained for 18 (90%) patients, with 15 (75%) of these patients having elevated values and 3 (15%) having normal values. In addition to the sonography exam performed at the RH, 4 (20%) patients underwent a computed tomography scan based on the decision of the radiologists. The results of the study are summarized in Figure 1.

Only 10% of the study sample was found to have normal abdominal ultrasound findings related to specific biliary pathology, yet they were referred to RH due to elevated WBC in 1 case and worsening abdominal pain in the other. In both cases, the BES did not provide any indication of the worsening of their condition or the etiology of the pathologies. This 10% represents the added advantage of sonographic screening, as it allows for the primary exclusion of some life-threatening pathologies, enabling more rational and objective decisions by BES physicians. The remaining 60% of the patients showed abnormalities in the biliary system, liver, and possibly pancreas, which could explain their RUQ pain and elevated WBC in some cases.

3.1 | Descriptive analysis and interpretation of sonographic findings between BES and RH

The study variables/categories were analyzed in terms of BES+/RH+ (%), as well as doubtful and absent for BES/RH. The percentages were calculated based on 20 patients. The results (Figure 1) showed that the positive sonographic Murphy sign had a high degree of similarity, with 17 out of 16 (80%) patients being considered positive by both BES and RH. Only 1 patient (5%) was not considered positive for sonographic Murphy sign by the radiologists, and both observers had doubts in 3 cases (15%).

In the category Sonographic changes in Gallbladder wall, there was a degree of similarity between observers in 18 out of 11 patients (55%). Radiologists did not perform gallbladder wall measurements in 9 (45%) patients. The evaluation of symptoms and signs by BES and RH may have differed, as the therapeutic intervention had already been initiated by the time of the ultrasonography performed by radiologists.

In the category of "Cholelithiasis/Gallbladder sludge" there was similarity between the two observers in the positive identification of the presence of cholelithiasis or gallbladder sludge in 12 out of 12 cases (60%). However, the sonographer was uncertain in 6 cases (30%) and the radiologists considered 8 patients (40%) to be absent for cholelithiasis. Regarding pericholecystic fluid or hazy wall delineation, there was similarity in 5 out of 6 positive cases (25%) with a difference of 1 case (5%) in the analysis. There was complete similarity in the classification of absent pericholecystic fluid in 13 out of 13 cases (65%). There were 2 cases (10%) with uncertainty from the sonographer and 1 case (5%) with uncertainty from the radiologists. Pericholecystic fluid was present in 2 patients (33%).

In the assessment of the CBD diameter, a positive measurement of greater than 6 mm was identified in 12 out of 8 (40%) patients, with a 4 (20%) patient difference between the observers. Radiologists did not measure the CBD in 12 (60%) patients. Regarding extra-intrahepatic biliary tract dilatation, there was a similarity in the positive identification in 5 out of 8 (25%) patients. The sonographer had 3 (15%) doubtful cases in this category. There was complete agreement in the evaluation of absent dilatation in the CBD in 12 out of 12 (60%) patients.

For pathology suggestion, the sonographer in the sonographic screening only reports normal or abnormal findings and does not make a diagnosis suggestion because it is the radiologists responsibility. Radiologists suggested pathology in 16 (80%) scanned patients.

The radiologists suggested cholecystitis in 6 (30%) patients. All 6 cases of cholecystitis were characterized by the presence of sonographic Murphy sign, sonographic changes in the gallbladder wall, and cholelithiasis. One of these cases also showed dilatation of the CBD.

There were 2 cases (10%) suggesting cholestasis and pancreatitis by radiologists. The complete blood analysis performed by RH provided by the doctors had the ability to simultaneously evaluate multiple parameters, supplementing the imaging evaluation for a more comprehensive assessment of specific pathologies.

3.2 | Inferential statistics

Cramer's V test was conducted to assess the association between variables (ultrasound findings in the BES and the RH), and Kappa test was utilized to evaluate the reliability among the sonography performers. The results are summarized in Table 2.

TABLE 2 Cramer's V test and Kappa measure of agreement values for the different tested variables.

Variables under study	Cramer's V	Sig	Kappa measure of agreement	Sig
Sonographic Murphy sign	0.859	0.001	0.664	0.001
Sonographic gallbladder wall changes	0.464	0.038	0.355	0.038
Cholelithiasis/gallbladder sludge	0.840	0.001	0.712	0.000
Pericholecystic fluid/hazy wall delineation	0.597	0.006	0.497	0.006
Common bile duct measure above 6 mm	0.667	0.003	0.615	0.003
Extra or intrahepatic biliary tract dilation	0.717	0.006	0.537	0.002

Cramer's *V* test demonstrated a very strong association in the sonographic findings obtained in the BES and the RH ($V > 0.6$) in four variables: "Sonographic Murphy sign" ($V = 0.859$; $p = 0.001$), "Cholelithiasis/Gallbladder sludge" ($V = 0.840$; $p = 0.001$), "Extra-Intrahepatic biliary tract dilatation" ($V = 0.717$; $p = 0.006$), and "Common Bile Duct measure, above 6 mm" ($V = 0.667$; $p = 0.003$). The variable "Pericholecystic fluid" showed strong association with a Cramer's *V* of 0.597 ($p = 0.006$). "Sonographic changes in Gallbladder wall" was found with moderate association ($V = 0.464$; $p = 0.038$).

The Kappa test indicated moderate similarity between observers in "Sonographic Murphy Sign"; "Cholelithiasis/Gallbladder sludge"; and "Common Bile Duct over 6 mm" variables ($0.60 \geq k \leq 0.79$). "Extra-Intrahepatic Biliary Tract Dilatation" and "Pericholecystic Fluid/Hazy Wall Delineation" variables showed weak association ($0.40 \geq k \leq 0.59$). The "Sonographic Changes in Gallbladder Wall" variable showed a minimum similarity ($0.21 \geq k \leq 0.39$).

4 | DISCUSSION

In this study, cholecystitis was confirmed in 30% of patients presenting with RUQ pain, which is consistent with findings from previous studies.^{34,35} The sonographic Murphy sign, changes in the gallbladder wall, and presence of cholelithiasis were the most favorable sonographic findings for suspected cholecystitis, as reported in the literature.³⁶ Moreover, a high WBC count was observed in 67% of patients with cholecystitis, which aligns with previous studies.^{37,38}

Considering only the relationship BES+/RH+ for each variable, our results show a 13.3% discrepancy in sonographic findings between BES and RH, which is lower than the 15.5% reported by Dawkins et al.¹⁰ Moreover, studies by Kari and Gerhardsen and Williams et al. found high agreement in abdominal sonography between Norwegian sonographers and radiologists (95.5% concordance) and between remote sonographers and teleradiologists (97.2% accuracy), respectively.¹¹

Schneider et al.¹³ concluded that sonographer findings in cases of abdominal ultrasound referred by the ED have a high level of agreement with radiologists, with a discrepancy of 14% between the two. This is similar to the 13.3% discrepancy found in our study.

In our study, inferential statistical analysis revealed statistically significant associations between variables, as indicated by Cramer's *V* test values. These significant associations suggest that sonographic findings for biliary track pathology evaluation are reproducible if specific sonographic criteria are followed, regardless of whether the exam is performed by BES or RH. This high degree of similarity between different performers (BES/RH) in detecting changes of the biliary structures was found for both screening and orthodox ultrasound exams.

Further comparative data between radiographers/sonographers and radiologists would be valuable to enhance the existing academic education, both theoretically and practically, and to increase the use of sonographic screening by BES.⁷ This benefit of integrating ultrasound performed by radiographers/sonographers and its cost-effectiveness for the National Health System has been documented by Lobo et al.³⁹

Results also emphasize the importance of not disregarding orthodox exams performed by specialists. Radiologists have a minimum of 6 years of specialized training, in addition to their previous medical education degree program (6 years) and possess a comprehensive knowledge of pathologies and the use of various imaging methods for diagnosis.

4.1 | Limitations of the study

The BES ultrasound equipment from 2006 has probe limitations and a lower image quality compared to GE equipment used by radiologists in the RH. Abdominal scanning for solid abdominal organs typically does not require the use of a specialized probe. However, the capabilities of older ultrasound machines may restrict the ability of the sonographer to obtain sufficient details of certain pathologies. This limitation may arise due to factors such as decreased spatial resolution, reduced image quality, or limited depth penetration, which can make it challenging to accurately observe certain conditions. Additionally, a lower level of expertise among sonographer compared to radiologists may contribute to the discrepancies in the obtained results.

There were some patients with evident biliary pathology who were referred to RH but ended up leaving this medical care facility (left the Basic Emergency Center) reducing the representativeness of our sample. Additionally, there were cases that were excluded from the study because although the sonography exam was repeated at RH, the images and report were not retrievable from PACS for unknown reasons.

5 | CONCLUSION

The use of POCUS for screening in a prehospital setting was found to be highly effective in guiding patient referrals to RH. In this study, all patients referred to the RH were correctly identified as having an urgent pathology that required further investigation or treatment. The findings align with current literature, demonstrating a high degree of concordance between the screening results and those obtained from orthodox ultrasound exams, regardless of the operator's location (either in the prehospital setting or the reference hospital).

POCUS in prehospital screening demonstrated its efficacy as a valuable tool in directing physician decision-making regarding patient referral and management based on clinical findings.

While the objectives of POCUS screening and conventional sonography may differ, both rely on a shared imaging foundation. It is important to note that this POCUS screening does not intend to make a diagnostic determination. Sonographers can contribute to the screening process without encroaching on the responsibilities of other medical specialists, and their involvement has been shown to add value to patient care in certain situations and in specific contexts.

Further studies with larger sample sizes and wider geographical scope should be conducted. This would provide a more comprehensive understanding of the phenomenon under investigation and help validate and refine the outcomes of this study.

AUTHOR CONTRIBUTIONS

Sérgio Miravent: Conceptualization; data curation; formal analysis; investigation; resources; validation; visualization; writing—original draft; writing—review and editing. **Manuel Lobo:** Formal analysis; methodology; supervision; validation; visualization; writing—review and editing. **Teresa Figueiredo:** Supervision; validation; visualization. **Carmen Jiménez:** Supervision; validation; visualization. **Rui Almeida:** Data curation; formal analysis; software; supervision; validation; visualization; writing—review and editing.

CONFLICT OF INTEREST STATEMENT

The authors declare no conflict of interest.

DATA AVAILABILITY STATEMENT

The authors state that the anonymized data that support the findings of this study are available from the corresponding author upon reasonable request.

ETHICS STATEMENT

This study was approved by the Institutional Review Board from the BES. All ultrasound exams were ordered by emergency physicians. Some patients were unable to provide informed consent due to their health conditions. In these cases, the consent was obtained by the legal representative. To ensure compliance with the general data protection law, no patient or institutional data was recorded. The primary aim of the study was to demonstrate the significance and utility of sonographic screening in a prehospital setting. The study adhered to ethical standards for scientific investigation, including the principles outlined in the Declaration of Helsinki and the applicable national data protection legislation.

TRANSPARENCY STATEMENT

The lead author Manuel Lobo affirms that this manuscript is an honest, accurate, and transparent account of the study being reported; that no important aspects of the study have been omitted; and that any discrepancies from the study as planned (and, if relevant, registered) have been explained.

ORCID

Sérgio Miravent  <https://orcid.org/0000-0002-1345-5747>

Manuel Lobo  <http://orcid.org/0000-0002-2529-1719>

Teresa Figueiredo  <https://orcid.org/0000-0002-0569-4764>

Rui Almeida  <http://orcid.org/0000-0001-7524-9669>

REFERENCES

- Jones D. Point of care ultrasound: emerging trend. *Nursing Palliative Care*. 2019;4(4):1-3. doi:10.15761/NPC.1000208
- Doniger SJ, Ng N. Cardiac point-of-care ultrasound reveals unexpected, life-threatening findings in two children. *Ultrasound J*. 2020;12(1):4. doi:10.1186/s13089-020-0154-3
- Abu-Zidan FM, Cevik AA. Diagnostic point-of-care ultrasound (POCUS) for gastrointestinal pathology: state of the art from basics to advanced. *World J Emerg Surg*. 2018;13(1):47. doi:10.1186/s13017-018-0209-y
- Scharonow M, Weillbach C. Prehospital point-of-care emergency ultrasound: a cohort study. *Scand J Trauma Resusc Emerg Med*. 2018;26(1):49. doi:10.1186/s13049-018-0519-9
- Shaddock L, Smith T. Potential for use of portable ultrasound devices in rural and remote settings in Australia and other developed countries: a systematic review. *J Multidiscip Healthc*. 2022;15(March):605-625. doi:10.2147/jmdh.s359084
- Chawla TP, Cresswell M, Dhillon S, et al. Canadian association of radiologists position statement on point-of-care ultrasound. *Can Assoc Radiol J*. 2019;70(3):219-225. doi:10.1016/j.carj.2019.06.001
- Dietrich CF, Sirlin CB, O'Boyle M, Dong Y, Jenssen C. Editorial on the current role of ultrasound. *Applied Sciences*. 2019;9(17):3512. <https://www.mdpi.com/2076-3417/9/17/3512/htm>
- Edwards HE, Sidhu PS. Who's doing your scan? A European perspective on ultrasound services Wer macht die Untersuchung? *Ultraschall aus der Europäischen Perspektive*. 2017;38(5):479-482. doi:10.1055/s-0043-117449
- European Society of Radiology. Position statement and best practice recommendations on the imaging use of ultrasound from the European Society of Radiology ultrasound subcommittee. *Insights Imaging*. 2020;11(1):115. doi:10.1186/s13244-020-00919-x
- Dawkins A, George N, Ganesh H, et al. Radiologist and sonographer interpretation discrepancies for biliary sonographic findings: our experience. *Ultrasound Q*. 2017;33(4):261-264. doi:10.1097/RUQ.0000000000000280
- Kari B, Gerhardsen V. The accuracy of sonographers carrying out upper abdominal ultrasound examinations. *Radiography*. 2014;19(3):186-189. doi:10.1016/j.radi.2013.05.001
- Williams I, Baird M, Schneider M. Comparison between radiographers with sonography education working in remote Australia and radiologists' interpretation of ultrasound examinations. *J Med Radiat Sci*. 2022;69(3):293-298. doi:10.1002/jmrs.576
- Schneider M, Bloesch J, Lombardo P. Abdominal ultrasound referred by the emergency department—can sonographer findings help guide timely patient management? *Radiography*. 2014;20(1):4-7. doi:10.1016/j.radi.2013.10.010
- Bennett GL. Cholelithiasis, cholecystitis, choledocholithiasis, and hyperplastic cholecystoses. *Textb Gastrointest Radiol*. 2008;2:1411-1456. doi:10.1016/B978-1-4160-2332-6.50084-1
- Hilsden R, Leeper R, Koichopolos J, et al. Point-of-care biliary ultrasound in the emergency department (BUSED): implications for surgical referral and emergency department wait times. *Trauma Surg Acute Care Open*. 2018;3(1):e000164. <https://tsaco.bmj.com/content/3/1/e000164>
- Jones J, Knipe H. Sonographic murphy sign. Radiopaedia.org [Internet]. 2013. <https://radiopaedia.org/articles/sonographic-murphy-sign-1>
- The University of British Columbia. How-to guide: ultrasounf for the gallbladder [Internet]. 2020. <https://med-fom-house.sites.olt.ubc.ca/files/2020/10/2020-09-25-How-To-Guide-Gallbladder.pdf>
- Niknejad M, Radwiki T. Acute cholecystitis. Radiopaedia.org [Internet]. 2010. <http://radiopaedia.org/articles/12084>
- Yoo MC, Yoo SD, Chon J, Han YR, Lee SA. Acute cholecystitis as a rare and overlooked complication in stroke patients: a retrospective monocentric study. *Medicine*. 2019;98(9):14492. doi:10.1097/MD.00000000000014492
- Segura Grau A, Joleini S, Díaz Rodríguez N, Segura Cabral JM. Ecografía de la vesícula y la vía biliar. *Semer-Med Fam*. 2016;42(1):25-30. doi:10.1016/j.semerg.2014.09.004
- Gore RM, Levine MS. *Textbook of Gastrointestinal Radiology*. Elsevier Health Sciences; 2014.
- Faikhongngoen S, Chenthanakij B, Wittayachamnankul B, Phinyo P, Wongtanasarasin W. Developing a simple score for diagnosis of acute cholecystitis at the emergency department. *Diagnostics*. 2022;12(9):2246. <https://www.mdpi.com/2075-4418/12/9/2246/htm>
- Lindenmeyer C. Acute cholecystitis. MSD manual—professional version [Internet]. 2022. <https://www.msmanuals.com/professional/hepatic->

- and-biliary-disorders/gallbladder-and-bile-duct-disorders/acute-cholecystitis
24. Block B. *Abdominal Ultrasound Step by Step 2e*. Thieme; 2012:292.
 25. Imhof M, Raunest J, Ohmann C, Röher HD. Acute acalculous cholecystitis complicating trauma: a prospective sonographic study. *World J Surg*. 1992;16:1160-1165. doi:10.1007/BF0206708926
 26. Bowie JD. What is the upper limit of normal for the common bile duct on ultrasound: how much do you want it to be? *Am J Gastroenterol*. 2000;95(4):897-900. https://journals.lww.com/ajg/Fulltext/2000/04000/What_Is_The_Upper_Limit_of_Normal_for_The_Common.7.aspx
 27. Rizvi A, Sethi A, Poneris J, Visrodia KH. Does incidentally detected common bile duct dilation need evaluation? *Cleve Clin J Med*. 2022;89(6):315-319. doi:10.3949/ccjm.89a.21029
 28. Van Breda Vriesman AC, Engelbrecht MR, Smithuis RHM, Puylaert JBCM. Diffuse gallbladder wall thickening: differential diagnosis. *Am J Roentgenol*. 2007;188(2):495-501. doi:10.2214/AJR.05.1712
 29. Kalra N. Radiological evaluation of the enhancement patterns of thickened gallbladder wall to differentiate benign from malignancy. *J Gastroenterol, Pancreatol Liver Disorders*. 2017;4(1):1-6. doi:10.15226/2374-815X/4/1/00181
 30. Becker BA, Chin E, Mervis E, Anderson CL, Oshita MH, Fox JC. Emergency biliary sonography: utility of common bile duct measurement in the diagnosis of cholecystitis and choledocholithiasis. *J Emerg Med*. 2014;46(1):54-60. doi:10.1016/j.jemermed.2013.03.024
 31. Lahham S, Becker BA, Gari A, et al. Utility of common bile duct measurement in ED point of care ultrasound: a prospective study. *Am J Emerg Med*. 2018;36(6):962-966. doi:10.1016/j.ajem.2017.10.064
 32. Marchal GJF, Casaer M, Baert AL, Goddeeris PG, Kerremans R, Fevery J. Gallbladder wall sonolucency in acute cholecystitis. *Radiology*. 1979;133(2):429-433. doi:10.1148/133.2.429
 33. Yeo DM, Jung SE. Differentiation of acute cholecystitis from chronic cholecystitis. *Medicine*. 2018;97(33):e11851. doi:10.1097/md.00000000000011851
 34. Rifenburg R, Litchke C, Chan S. 348 diagnosing acute cholecystitis with bedside ultrasonography. *Ann Emerg Med*. 2014;64(4):S123. doi:10.1016/j.annemergmed.2014.07.376
 35. Gore RM, Thakrar KH, Wenzke DR, Silvers RI, Mehta UK. Berlin, Geraldine Mogavero Newmark JWB. The acute abdomen. *Textb Gastrointest Radiol 2-Volume Set*. 2015;2:1207-1224. doi:10.1016/B978-1-4557-5117-4.00124-0
 36. O'Connor OJ, Maher MM. Imaging of cholecystitis. *Am J Roentgenol*. 2011;196(4):367-374. <https://pubmed.ncbi.nlm.nih.gov/21427298/>
 37. Hwang H, Marsh I, Doyle J. Does ultrasonography accurately diagnose acute cholecystitis? Improving diagnostic accuracy based on a review at a regional hospital. *Can J Surg*. 2014;57(3):162-168. <https://www.canjsurg.ca/content/cjs/57/3/162.full.pdf>
 38. Kapoor V. Acute cholecystitis clinical presentation: history, physical examination [Internet]. 2022. <https://emedicine.medscape.com/article/171886-clinical>
 39. Lobo MJCD, Tavares SCCNM, Pereira de Almeida RP. Point of care prehospital ultrasound in basic emergency services in Portugal. *Heal Sci Reports*. 2022;5(5):1-8. doi:10.1002/hsr2.847

How to cite this article: Miravent S, Lobo M, Figueiredo T, Jiménez C, Almeida R. Effectiveness of ultrasound screening in right upper quadrant pain: a comparative study in a basic emergency service. *Health Sci Rep*. 2023;6:e1251. doi:10.1002/hsr2.1251