

# Animal Challenge Models of Henipavirus Infection and Pathogenesis

Thomas W. Geisbert, Heinz Feldmann and Christopher C. Broder

**Abstract** The henipaviruses, Hendra virus (HeV), and Nipah virus (NiV), are enigmatic emerging pathogens that causes severe and often fatal neurologic and/or respiratory disease in both animals and humans. Amongst people, case fatality rates range between 40 and 75% and there are no vaccines or treatments approved for human use. A number of species of animals including guinea pigs, hamsters, cats, ferrets, pigs, and African green monkeys have been employed as animal models of human henipavirus infection. Here, we review the development of animal models for henipavirus infection, discuss the pathology and pathogenesis of these models, and assess the utility of each model to recapitulate important aspects of henipavirus-mediated disease seen in humans.

## Contents

1	Introduction.....	154
2	Naturally Occurring Henipavirus Infections .....	155
2.1	Henipavirus Infection in Humans .....	155
2.2	Henipavirus Infections in Animals .....	156

---

T. W. Geisbert (✉)

Galveston National Laboratory, Department of Microbiology and Immunology,  
University of Texas Medical Branch, Galveston, TX, USA  
e-mail: tom.geisbert@utmb.edu

H. Feldmann

Laboratory of Virology, Rocky Mountain Laboratories,  
Division of Intramural Research,  
National Institute of Allergy and Infectious Diseases,  
National Institutes of Health, Hamilton, MT, USA

C. C. Broder

Department of Microbiology and Immunology,  
Uniformed Services University, Bethesda, MD, USA

3	Animal Modeling of Henipavirus Infection .....	158
3.1	Initial Experimental Infections of Animals .....	158
3.2	Henipavirus Infection Experiments in Their Pteropid Bat Hosts .....	159
4	Well-Established Animal Models of Henipavirus Infection.....	160
4.1	Guinea Pig Model.....	160
4.2	Pig Model.....	160
4.3	Horse Model .....	165
4.4	Cat Model .....	166
4.5	Golden Syrian Hamster Model .....	167
4.6	Ferret Model .....	168
4.7	Nonhuman Primate Model .....	168
5	Routes of Experimental Exposure and Dose.....	171
6	Epilogue.....	172
	References.....	172

## 1 Introduction

Hendra virus (HeV) and Nipah virus (NiV) are members of the genus *Henipavirus* (family *Paramyxoviridae*) that can cause severe respiratory illness and/or encephalitis in a wide variety of mammals, including humans (Selvey et al. 1995; Chua et al. 1999). HeV was identified as the causative agent of an acute respiratory disease in horses in 1994 in Queensland, Australia (Selvey et al. 1995) and to date there have now been 32 outbreaks in Australia since, with at least one or more occurrences per year since 2006. Every outbreak of HeV has involved horses as the initial infected host and there have been a total of seven human cases arising from exposure to infected horses. Four human fatalities have occurred (Playford et al. 2010) with the most recent occurring in August 2009 (Anonymous 2009). NiV was first identified during an outbreak of severe encephalitis in Malaysia and Singapore in 1998–1999 with at least 265 human cases and 105 deaths, with pigs serving as the intermediate amplifying host (Chua et al. 1999; Paton et al. 1999; Goh et al. 2000; Chua 2003). Since 1998 there have been more than a dozen recognized occurrences of human NiV infection, primarily in Bangladesh and India (Chadha et al. 2006; Harit et al. 2006; Luby et al. 2009b; Arankalle et al. 2011). In the majority of subsequent spillover events, the mortality rate among humans has been higher (~ 75%) along with evidence of multiple rounds of person-to-person transmission (Gurley et al. 2007; Homaira et al. 2010).

Several species of fruit bats of the *Pteropus* genus (flying foxes) appear to be the principle natural reservoirs of both NiV and HeV [reviewed in Bishop and Broder (2008)] but serological evidence of NiV or Nipah-like virus infection has recently been reported in several additional frugivorous and insectivorous bats (Hayman et al. 2008; Li et al. 2008). NiV has been isolated from bat urine and partially eaten fruit (Chua et al. 2002; Reynes et al. 2005) and direct transmission of NiV from flying foxes to humans from contaminated food sources has been suggested (Harit et al. 2006; Luby et al. 2006).

The development and characterization of suitable animal models for henipavirus infection is essential for studying features of the virus such as shedding and transmission and in the case of henipaviruses the underlying mechanisms of pathogenesis and recrudescence. In addition, the availability of well characterized animal models is essential for fulfilling the critical needs for the *in vivo* evaluation of potential prophylactic and antiviral modalities for human use. Of particular importance, the U.S. Food and Drug Administration (FDA) implemented the Animal Efficacy Rule which came into effect in 2002. This rule specifically applies to the development of medical countermeasures when human efficacy studies are not possible or ethical, such as is often the case with highly virulent emerging pathogens like the henipaviruses. Essentially, this rule allows for the evaluation of vaccines or therapeutics using data derived from studies carried out in two animal models. Here, we provide a literature review of small and large animal models of HeV and NiV infection.

## 2 Naturally Occurring Henipavirus Infections

### 2.1 *Henipavirus Infection in Humans*

Both HeV and NiV are zoonotic viral infections of humans but each can also infect various mammalian species in spillover events from their natural pteropid bat reservoir hosts [reviewed in Eaton et al. (2006)]. Among the known susceptible animal hosts, including humans, each can cause a systemic infection and the central features of acute henipavirus infection and pathogenesis in humans are widespread vasculitis with endothelial cell tropism with syncytia, thrombosis, ischemia and necrosis, along with parenchymal cell infection and pathogenesis of many major organs but is particularly prominent in the brain, lung, heart, and kidney (Chua et al. 1999; Wong et al. 2002, 2009). Reflecting the major involvement of both the lung and brain, severe henipavirus disease in humans can manifest as acute interstitial pneumonitis, encephalitis, or a combination of both.

To date there have been only seven (four fatal) confirmed human cases of HeV, all in Australia, since 1994 (Murray et al. 1995a; Selvey et al. 1995; Hooper et al. 1996; Rogers et al. 1996; Hanna et al. 2006; Anonymous 2009; Playford et al. 2010). Of these seven human cases (three in 1994 and one in 2004) four had initially presented with influenza-like illness and two survived infection, whereas the two linked cases in 2008 experienced initial influenza-like illness but later, following clinical resolution including abatement of fever, progressed to encephalitic disease with widespread cortical, subcortical, and deep white matter involvement similar to NiV encephalitis with one patient succumbing to infection (Playford et al. 2010). The seventh and fatal case of HeV infection presented with encephalitis ~3 weeks following exposure to a horse that died of HeV infection (Anonymous 2009).

In contrast, there have been many hundreds of cases of human NiV infection since the initial Malaysian outbreak together with more than a dozen outbreaks in Bangladesh and India [reviewed in Bishop and Broder (2008); Luby et al. (2009b)]. NiV human infection reveals central nervous system (CNS) vascular pathology as more severe in comparison to other organ systems, with necrosis, edema and inflammation often associated with viral antigen (Wong et al. 2002). Systemic vasculitis, extensive thrombosis, and parenchymal necrosis, particularly within the CNS, along with endothelial cell damage, evident syncytia and widespread presence of viral antigen in endothelial and smooth muscle cells of blood vessels. Viral antigen was also present in various parenchymal cells, notably in neurons, and NiV infection of endothelial cells and neurons along with vasculitis and thrombosis seem to be critical to the pathogenesis of NiV infection in humans (Wong et al. 2002; Wong and Ong 2011).

In addition, human henipavirus infection outcomes can take a prolonged course following an initial infection, a process first observed in the second fatal HeV case which occurred in an individual who died from encephalitis 13 months after an aseptic meningitic illness that was only retrospectively determined to have been caused by HeV (O'Sullivan et al. 1997). The majority of human cases of NiV infection in Malaysia presented with acute encephalitis with ~25% of cases also showing respiratory signs (Chua 2003); however, it was noted that neurological disease could present later (>10 weeks) following a nonencephalitic, asymptomatic infection, or patients who recovered from acute encephalitis. Relapsed-encephalitis presented from several months to as late as 4 years after infection (Wong et al. 2001; Tan et al. 2002; Chong and Tan 2003; Tan and Wong 2003). A recent comparative analysis of the first two fatal human cases of HeV infection (acute respiratory and relapsed encephalitis) has been reported (Wong et al. 2009). Immuno- and histopathological findings showed that HeV was neurotropic in both cases and could cause CNS infections that can result in either acute encephalitis (in the absence of apparent clinical encephalitis) or relapsed encephalitis with pathological features similar to acute and relapsed NiV encephalitis. How these viruses escape immunological clearance for such an extended period is unknown, and relapsed or late onset encephalitis are considered to be caused by recrudescence and replication of virus within the CNS (Tan et al. 2002; Wong et al. 2009). To our knowledge, attempts to recreate this recrudescence process of HeV or NiV infection in an animal model has not been attempted although several groups have proposed it.

## 2.2 *Henipavirus Infections in Animals*

The natural reservoirs for HeV and NiV are several species of *Pteropus* fruit bats. Early, serological surveys revealed that all four Australian-mainland species of *Pteropus* fruit bats can be naturally infected with HeV (Young et al. 1996) and HeV has been isolated from two of these bat species from uterine fluids or fetal

tissues (Halpin et al. 2000, 2011) and more recently from pooled urine samples (Smith et al. 2011). NiV neutralizing antibodies were identified in both Island flying foxes (*P. hypomelanus*) and Malayan flying foxes (*P. vampyrus*) (Yob et al. 2001). Subsequently, NiV was isolated from pooled urine samples as well as from a swab sample taken from a partially eaten fruit from Island flying foxes (Chua et al. 2002). NiV has also been isolated from the urine of flying foxes in Cambodia (Reynes et al. 2005). No occurrence of clinical disease caused by HeV (Halpin et al. 2000; Field et al. 2001) or NiV (Rahman et al. 2010; Sohayati et al. 2011) infection has been reported in naturally infected fruit bats.

The first appearance and recognition of HeV with associated disease occurred in Australia in 1994 among horses whereas the initial occurrence of NiV was associated with an outbreak in farmed pigs in Malaysia in 1998 [reviewed in Eaton et al. (2006)]. HeV occurs only in Australia, and in total, there have now been 32 separate spillover events of HeV along that country's coast from Queensland to New South Wales, with the last 18 episodes occurring between June and October of 2011 (Anonymous 2011b; Smith et al. 2011). Every appearance of HeV infection in animals with associated disease has been in domestic horses. The only other known natural HeV infection in another animal species was reported in 2011 with serological evidence observed in a healthy dog from a HeV-infected property (Anonymous 2011a).

In addition to pigs, there were other naturally occurring NiV infections recorded in cats, dogs, and horses in the initial Malaysian outbreak (Hooper et al. 2001). Serological evidence of natural NiV infection among other animals revealed that dogs in those areas associated with the farms in the Malaysian outbreak were susceptible to NiV infection (Field et al. 2001). Diseased dogs however were uncommon, and only two animals (one found dead and another sick) were examined (Hooper et al. 2001; Wong and Ong 2011). A more recent assessment of natural NiV infection in dogs by serological analysis has confirmed that natural infection is possible, but the presence of NiV does not appear to be maintained within the population in an absence of infected pigs (Mills et al. 2009). Subsequent NiV outbreaks have occurred nearly every year in Bangladesh and India since its discovery in Malaysia in 1999 (Harit et al. 2006; Luby et al. 2009b; Arankalle et al. 2011); however, these appearances of the virus have all been associated with severe disease and high fatality rates in humans, with more than half of these cases attributed to person-to-person transmission (Luby et al. 2009b; Homaira et al. 2010). The initial introduction of the virus into humans was primarily associated with the consumption of raw date palm sap contaminated with NiV from bats (Luby et al. 2009a; Rahman et al. 2011); however, a few cases were associated with contact with sick animals including cows (Hsu et al. 2004), pigs, and diseased goats (Luby et al. 2009a). Experimental infection of a variety of animals with HeV, NiV, or both has since been carried out by a number of laboratories with most of the species that were noted to be susceptible to natural infection, including fruit bats, and these will be discussed below.

### 3 Animal Modeling of Henipavirus Infection

#### 3.1 Initial Experimental Infections of Animals

The first animal infection experiments with HeV (then called equine morbillivirus) were carried out in horses as a means of reproducing the syndrome observed in those animals during the first recorded outbreak (Murray et al. 1995a, b). The initial HeV infection experiments in horses produced primarily a respiratory disease yielding pulmonary edema and congestion and hemorrhage. Follow-up experiments have provided more detail and will be discussed below.

Additional HeV challenge experiments in horses have detailed the presence of viral antigen noted in endothelial cells in a wide variety of organs including lungs, lymph nodes, kidneys, spleen, bladder, and meninges. A series of other animal infection experiments were conducted with HeV soon after its discovery in 1994 at the Australian Animal Health Laboratories (AAHL). A challenge experiment was carried out in mice, guinea pigs, rats, chickens, rabbits, cats, and dogs, each of which were challenged with a 5,000 TCID<sub>50</sub> dose of HeV by subcutaneous (s.c.) inoculation (Westbury et al. 1995). Mice, rats, rabbits, chickens, and dogs did not develop any signs of clinical disease, and only cats and guinea pigs developed HeV disease. Two of two cats developed respiratory distress and inappetance by the 5th and 6th day and both succumbed to infection a day later, while four of five guinea pigs developed similar clinical signs between day 7 and 12 each died a day following disease onset. The remaining guinea pig remained well and did not develop HeV neutralizing antibody. At necropsy, both cats and guinea pigs exhibited gross pathological lesions of pneumonia with cats having a more severe presentation, and histologically these lesions were similar to those reported from horses that died of HeV disease (Murray et al. 1995a, b). Virus could also be isolated from a variety of tissue samples from infected cats and guinea pigs. No lesions were observed in any of the other animal species tested; however, rats, rabbits, and one dog seroconverted, while mice and chickens did not. A limited number of experimental horse inoculations with HeV were also carried out which essentially reproduced the clinical and pathological findings reported from equine field cases (Hooper et al. 1997a), characterized as a systemic vascular disease and parenchymal infection in a wide variety of organs with severe lesions in the lungs with hemorrhage, edema, and necrosis and syncytia in the endothelium of pulmonary vessels. Vascular and parenchymal lesions were also seen in the heart, kidney, brain, spleen, lymph node, and stomach. Follow-up HeV infection experiments carried out at the AAHL focused on the cat and guinea pig models (Westbury et al. 1996; Hooper et al. 1997b; Williamson et al. 1998, 2000, 2001).

The isolation and characterization of NiV as a newly discovered agent of encephalitic disease in humans and respiratory disease among farmed pigs in Malaysia came at the close of the 1990s (Anonymous 1999; Chua et al. 1999, 2000). The first animal infection experiments with NiV were also conducted at the AAHL as early as 1999, and these included pigs, cats, and bats (Hooper et al. 2001;

Middleton et al. 2002). Both nervous and respiratory disease with fever was reproduced in pigs, between day 7 and 9, by s.c. inoculation with a 50,000 TCID<sub>50</sub> dose of NiV (a nonplaque purified, low passaged isolate obtained from the CNS of a fatal human case in Malaysia), while pigs exposed orally or by in-contact with infected pigs resulted in active infection with virus shedding in respiratory secretions, particularly from tonsillar swabs, but in the absence of any significant clinical signs or pathological findings. Diseased pigs exhibited histological evidence of systemic vasculitis, alveolitis, and meningitis with some endothelial syncytia, along with detectable viral antigen (Middleton et al. 2002). In this same study, two cats that were inoculated oronasally with the same dose of virus were more severely diseased than pigs and became febrile and depressed with increased respiratory rates by day 6. One animal progressed to severe breathing difficulty and was euthanized and second began to recover by day 10 (Middleton et al. 2002). The clinical and pathological findings were comparable to those observed in HeV-infected cats (Westbury et al. 1996) but infection of the respiratory tract was more severe. Virus could be recovered from urine, tonsils, and blood. The pathological findings by histological and immunohistochemical analysis also revealed the systemic vasculitis, alveolitis, and meningitis in a field a case of NiV infection in a cat with most severely affected organs being the brain, kidney, liver, and lung (Hooper et al. 2001; Middleton et al. 2002).

### ***3.2 Henipavirus Infection Experiments in Their Pteropid Bat Hosts***

A limited number of studies have also examined experimental henipavirus infection in fruit bats, including HeV infection in *P. poliocephalus* and *P. alecto* (Williamson et al. 1998, 2000; Halpin et al. 2011) and NiV infection in *P. poliocephalus* and *P. vampyrus* (Middleton et al. 2007; Halpin et al. 2011). All of these studies have been carried out at the AAHL, and in all experiments, no clinical disease or gross pathological findings has ever been observed in fruit bats experimentally infected with either HeV or NiV, even with high doses (50,000 TCID<sub>50</sub>) of virus by s.c. inoculation, but most bats do seroconvert. Only occasional and varied histopathological findings were noted in some bats and most of these observations came from animals inoculated s.c. with HeV (Williamson et al. 1998, 2000; Middleton et al. 2007). Vasculitis with positive immunostaining, associated with the spleen and kidney was observed in some *P. poliocephalus* bats infected with HeV, and this study also confirmed transplacental transmission of HeV in bats showing positive immunostaining of two placentas and virus isolation from a fetus (Williamson et al. 2000). However, fetal tissues showed no evidence of pathology or HeV by immunostaining.

Notably, in the two largest studies of henipavirus infection in pteropid bats, all tissues were found negative by immunohistochemical staining for viral antigen, including tissues which showed histopathological findings (Middleton et al. 2007; Halpin et al. 2011). These studies also revealed that virus shedding from experimentally infected bats does occur, although recovery of virus was rare and only

from urine (Middleton et al. 2007; Halpin et al. 2011). HeV genome could be detected in urine, blood, and rectal and throat swabs, as well as some tissues *P. alecto*, whereas NiV genome was rarely detected in *P. vampyrus* and only in mucosal swabs and not in tissues (Halpin et al. 2011).

## 4 Well-Established Animal Models of Henipavirus Infection

The principal clinical and pathological findings of HeV and NiV infection in animal models and their potential limitations in comparison to human infection are shown in Table 1.

### 4.1 Guinea Pig Model

Guinea pigs were first examined by experimental infection with HeV but the pathology seen in guinea pigs differed significantly in several respects as compared to human cases as well as both naturally and experimentally infected horses such as little or no pulmonary edema being noted (Hooper et al. 1997b; Williamson et al. 2001). The clinical response to either HeV or NiV infection in guinea pigs has been reported to be often mild and variable, ranging from an inapparent infection following challenge to sudden death. Further, in several reports, only a proportion of animals presented with clinical signs, such as transient weight loss, depression, ataxia, lethargy, and twitching (Williamson et al. 2001; Wong et al. 2003). One study demonstrated that intraperitoneal (i.p.) inoculation with high doses of NiV ( $10^7$  PFU) resulted only a transient fever with minor weight loss after 5–7 days and later recovered (Wong et al. 2003). Another study conducted a 50,000 TCID<sub>50</sub> challenge with NiV by i.p. administration, and here also only three of eight animals exhibited any signs of clinical disease which were only ruffled fur, mild behavioral changes, and ataxia (Middleton et al. 2007). The vascular tropism of HeV infection in guinea pigs is evident in many organs and when severe disease occurred death from widespread vascular disease was apparently the cause (Hooper et al. 1997b; Torres-Velez et al. 2008). In a model of HeV encephalitis in the guinea pig, it was reported that only a proportion of infected animals would develop encephalitis with virus observed in blood vessels and neurons (Williamson et al. 2001). The general consensus of the guinea pig is that it is not a suitable animal model for challenge and protection studies.

### 4.2 Pig Model

NiV infection of pigs is frequently asymptomatic, this was especially noted following natural infections but also later during experimental challenge of pigs with NiV by the ocular and oronasal route (Mohd Nor et al. 2000; Middleton et al. 2002;



**Table 1** Comparison of disease in animal models of henipavirus infection with human infection

Animal model	Principal clinical and pathological findings in animal models in comparison to human infections	
	Hendra Virus <sup>a</sup>	Nipah Virus <sup>b</sup>
<i>Guinea pig</i> <sup>c</sup>	Systemic vascular disease	
HeV:	Endothelial syncytia evident; gross signs of pneumonia	Vasculitis with endothelial syncytia
Subcutaneous; $5 \times 10^3$ ;		Viral antigen in endothelium and vessels
$3 \times 10^4$ – $5 \times 10^4$ ; or $5 \times 10^4$		
TCID <sub>50</sub>	Virus in kidney and urine; female reproductive tract; placenta with fetal transmission	
NiV:	Encephalitis with neuronal infection	
Intranasal; $6 \times 10^5$ PFU,		<i>Limitations</i>
Intraperitoneal; $1 \times 10^7$ PFU		Clinical response frequently mild. Evidence of infection in only a small proportion of challenged animals
Intraperitoneal; $5 \times 10^4$		Transient fever and weight loss with full recovery
TCID <sub>50</sub>		Encephalitis not observed
Intraperitoneal; $2.5 \times 10^5$ PFU		No lesions in the lung
		Virus isolate, route of inoculum, and dose effect outcome
		Intranasal infection not productive
<i>Pig</i> <sup>d,e</sup>		
HeV:	Respiratory and neurological disease signs (minipig); respiratory disease (Landrace pig), with fever	Respiratory and neurological disease signs
Oronasal; $6.6 \times 10^6$ PFU,		Interstitial pneumonia
Landrace pigs		Meningoencephalitis
Intranasal; $2 \times 10^7$ PFU,	Interstitial pneumonia	Virus shed in nasal, oral, pharyngeal, rectal, and ocular secretions
Gottingen minipigs	Syncytia frequent	
NiV:	Virus shed in nasal, oral, recta and ocular secretions	
Subcutaneous; $5 \times 10^4$ TCID <sub>50</sub>		<i>Limitations</i>
Oral; $5 \times 10^4$ TCID <sub>50</sub>		Respiratory system is primary organ target
		Although evident, CNS involvement was rarer
		Syncytia rare
		No virus in urine

(continued)

**Table 1** (continued)

Principal clinical and pathological findings in animal models in comparison to human infections		
Animal model	Hendra Virus <sup>a</sup>	Nipah Virus <sup>b</sup>
<i>Hamster<sup>f,g,h</sup></i>		
HeV:	Systemic vascular disease and parenchymal infection in a wide variety of organs	Systemic vascular disease and parenchymal infection in a wide variety of organs
Intranasal; $1-10^5$ PFU	Lung and brain severely affected with vascular and parenchymal lesions. Endothelial syncytia evident	Lung and brain severely affected with vascular and parenchymal lesions. Endothelial syncytia evident
Intranasal; $1-10^5$ TCID <sub>50</sub>	Neurological signs evident	Neurological signs evident
Intraperitoneal; $1-10^5$ TCID <sub>50</sub>	Virus shed in urine	Virus shed in urine
NIV:	Route of inoculum and dose shown to effect outcome, intranasal high dose yielding greater acute respiratory disease while low dose yielding greater neurological disease with respiratory disease	Route of inoculum and dose shown effect outcome, intranasal high dose yielding greater acute respiratory disease while low dose yielding greater neurological disease with respiratory disease
Intraperitoneal; $10-10^6$ PFU		
Intranasal; $1-10^4$ PFU		
<i>Cat<sup>i</sup></i>		
HeV:	Systemic vascular disease and parenchymal infection in a wide variety of organs. Fever and respiratory distress	Systemic vascular disease and parenchymal infection in a wide variety of organs. Fever and respiratory distress
Subcutaneous; $5 \times 10^3$ TCID <sub>50</sub>	Severe effects in the lungs, interstitial pneumonia	Severe effects in the lungs with edema and hemorrhage.
Intranasally; $5 \times 10^3$ TCID <sub>50</sub>	Endothelial syncytia evident	Endothelial syncytia evident
Oral; $5 \times 10^3$ TCID <sub>50</sub>	Extensive inflammation in the respiratory epithelium associated with viral antigen	Extensive inflammation in the respiratory epithelium associated with viral antigen
NIV:		
Subcutaneous; $500-5 \times 10^3$ TCID <sub>50</sub>	Virus in kidney and in urine	Virus shed in urine
Oronasal; $5 \times 10^4$ TCID <sub>50</sub>		Virus in female reproductive tract; placenta with fetal transmission
<i>Limitations</i>		
	Virus detected in brain but rare and no evidence of encephalitis	Virus detected in brain but encephalitis uncommon

(continued)

Table 1 (continued)

Principal clinical and pathological findings in animal models in comparison to human infections	
Animal model	
	Hendra Virus <sup>a</sup>
<i>Ferre<sup>1</sup>g</i>	Systemic vascular disease and parenchymal infection in a wide variety of organs. Fever and respiratory distress
HeV:	Lung and brain severely affected with vascular and parenchymal lesions
Oronasal; $50\text{--}5 \times 10^4$ TCID <sub>50</sub>	Neurological signs evident
NiV:	Virus shed in pharyngeal and rectal secretions
Oronasal; $500\text{--}5 \times 10^4$ TCID <sub>50</sub>	Syncytia prominent
	Nipah Virus <sup>b</sup>
<i>African Green Monkey<sup>k,g</sup></i>	Systemic vascular disease and parenchymal infection in a wide variety of organs
HeV:	Lung and brain severely affected with vascular and parenchymal lesions
Intratracheal; $4 \times 10^5$ TCID <sub>50</sub>	Neurological signs evident
NiV:	Virus shed in pharyngeal and rectal secretions
Intratracheal; oral; $8.1 \times 10^4\text{--}1.3 \times 10^6$ PFU	Syncytia prominent
Intratracheal; $2.5 \times 10^3\text{--}6.5 \times 10^4$ PFU	Systemic vascular disease and parenchymal infection in a wide variety of organs
<i>Squirrel monkey<sup>l</sup></i>	Lung and brain severely affected with vascular and parenchymal lesions, with edema and hemorrhage, with fibrinoid necrosis in the lung
NiV:	Neurological signs evident
Intravenous; $1 \times 10^3$ or $1 \times 10^7$ PFU	Endothelial syncytia prominent
Intranasal; $1 \times 10^3$ or $1 \times 10^7$ PFU	Potential rectal, throat and oronasal shedding
	Experimental infections not reported
	Systemic vascular disease and parenchymal infection in a variety of organs
	Respiratory and neurological signs evident
	<i>Limitations</i>
	Route of inoculum and dose effect outcome. Intranasal infection less productive, with subject recovery
	Clinical response can be mild even with intravenous virus challenge. Evidence of infection and clinical signs in only a proportion of animals
	Vasculitis and brain abnormalities were less evident
	No evidence of virus in urine

(continued)

**Table 1** (continued)

Animal model	Principal clinical and pathological findings in animal models in comparison to human infections	
	Hendra Virus <sup>a</sup>	Nipah Virus <sup>b</sup>
<i>Horse</i> <sup>m,n</sup>	Systemic vascular disease and parenchymal infection in a wide variety of organs. Endothelial syncytia prominent	
HeV:	Experimental infections not reported	
Intravenous + intranasal-aerosol; infected spleen and lung tissue homogenate intravenous;	Elevated heart rate, fever Respiratory disease, interstitial pneumonia Neurological signs, CNS vasculitis including meninges	
$1 \times 10^8$ TCID <sub>50</sub> + intranasal-aerosol; $2 \times 10^8$ TCID <sub>50</sub> oronasal; $2 \times 10^6$ TCID <sub>50</sub>	Virus shed in nasal, oral, pharyngeal and rectal secretions, and urine	

Summary of clinical and pathological outcomes of experimental animal infection models of Hendra virus and Nipah virus; and noted potential model limitations in comparison to natural cases of human infection. *PFU* plaque forming unit, *TCID*<sub>50</sub> 50% tissue culture infectious dose

<sup>a</sup> Human infection and pathogenesis (Hanna et al., 2006; O'Sullivan et al., 1997; Playford et al., 2010; Selvey et al., 1995; Wong et al., 2009)

<sup>b</sup> Human infection and pathogenesis (Chadha et al., 2006; Goh et al., 2000; Hsu et al., 2004; Wong et al., 2002)

<sup>c</sup> HeV-infected guinea pig (Hooper et al., 1997b; Torres-Velez et al., 2008; Westbury et al., 1995; Williamson et al., 2000, 2001); NiV-infected guinea pig (Middleton et al., 2007; Wong et al., 2003)

<sup>d</sup> HeV-infected pig (Li et al., 2010); NiV-infected Pig (Berhane et al., 2008; Middleton et al., 2002; Weingartl et al., 2005, 2006)

<sup>e</sup> Model developed for porcine and/or livestock vaccine development

<sup>f</sup> HeV-infected hamster (Guillaume et al., 2009; Rockx et al., 2011); NiV-infected hamster (Georges-Courbot et al., 2006; Guillaume et al., 2004; Guillaume et al., 2006; Rockx et al., 2011; Wong et al., 2003)

<sup>g</sup> Pulmonary and neurological pathology is similar to human pathology

<sup>h</sup> LD50 for NiV and HeV in hamsters is 270 PFU (Wong et al., 2003) vs 12 PFU (Guillaume et al., 2009), respectively

<sup>i</sup> HeV-infected cat (Hooper et al., 1997b; Middleton et al., 2002; Westbury et al., 1996); NiV-infected cat (McEachern et al., 2008; Mungall et al., 2006; Mungall et al., 2007)

<sup>j</sup> HeV-infected ferret (Pallister et al., 2011); NiV-infected ferret (Bossart et al., 2009; Pallister et al., 2009)

<sup>k</sup> HeV-infected African green monkey (Bossart et al., 2011; Rockx et al., 2010); NiV-infected African green monkey (Geisbert et al., 2010)

<sup>l</sup> NiV-infected squirrel monkey (Marianneau et al., 2010)

<sup>m</sup> HeV-infected horse (Hooper et al., 1997a; Marsh et al., 2011; Murray et al., 1995a, 1995b; Williamson et al., 1998)

<sup>n</sup> Model developed for equine and/or livestock vaccine development

Weingartl et al. 2006; Berhane et al. 2008; also refer to the chapter on Henipaviruses in their natural host (Middleton and Weingartl, this issue). When symptoms were apparent, they varied in relation to the age of the pig, with older animals predominantly exhibiting a neurological disease syndrome in contrast to younger pigs which primarily presented with a respiratory syndrome. The virus manifests respiratory and neurologic tropisms in both asymptomatic and clinical infections (Middleton et al. 2002; Weingartl et al. 2005). In pigs, neurological disease manifested as trembling, twitches, muscle spasms, and uncoordinated gait (Mohd Nor et al. 2000). NiV challenge of younger pigs by the ocular and oronasal routes revealed that virus replication occurs in the oropharynx and then spreads sequentially to the upper respiratory tract and submandibular lymph nodes, followed by replication in the lower respiratory tract, and additional lymphoid tissues (Weingartl et al. 2005). Virus replication and presence of detectable viral antigen can be widespread and accompanied by frequent syncytial cell formation, which is particularly evident in clinically ill animals, resulting from virus tropism and replication in endothelial and smooth muscle cells of medium to large veins and arteries within the respiratory system, CNS, and lymphoid tissues (Hooper et al. 2001; Middleton et al. 2002; Weingartl et al. 2005). NiV has also been reported to invade the CNS by route of the cranial nerves and crossing the blood–brain barrier (Weingartl et al. 2005). Infectious NiV could also be recovered from a wide variety of tissues in the infected pig, including tonsil, nasal, and throat swabs and lung, but only infrequently recovered from the urine of shedding animals (Daniels et al. 2001; Middleton et al. 2002; Weingartl et al. 2005).

There has been one report of HeV infection of Landrace and Gottingen minipig breeds. Oronasal or nasal inoculations were both demonstrated to cause infection (Li et al. 2010) with clinical signs mainly respiratory, but with possible neurological involvement seen only in the Gottingen minipig. Virus was detected mainly in tissues from respiratory and lymphoid systems in both Landrace and Gottingen pigs and histological and immunohistological analysis revealed frequent syncytia. 5-week-old Landrace pigs appeared to produce a more severe clinical disease in comparison to NiV infection (Weingartl et al. 2005, 2006), but in these experiments the inoculating dose of HeV was significantly higher compared to NiV ( $\sim 10^7$  compared to  $10^5$ ). Importantly, virus could be isolated from nasal, oral, and rectal swabs, indicating the possible routes for virus shedding and risk of transmission.

### ***4.3 Horse Model***

Experimental HeV infection of horses by either intravenous (i.v.) or intranasal (i.n.) routes is almost uniformly fatal with death or euthanasia occurring  $\sim 5$ – $10$  days following virus challenge. Experimental NiV infection of horses has not been carried out. Horses have been identified to have been naturally infected, and some do survive and some can experience asymptomatic infection with

seroconversion (Murray et al. 1995a, b; Williamson et al. 1998). HeV infection in horses yields a predominantly respiratory syndrome initially with elevated heart rate and fever which can rapidly progress to more severe respiratory disease. In field cases, the airways are often filled with a blood-tinged frothy exudate but this has not been experimentally reproduced, and could be a result of the infecting dose of virus. In addition, signs of neurological disease can occur but appear less frequent and have been reported in both terminally ill horses as well as in horses that recovered from HeV infection (Rogers et al. 1996; Williamson et al. 1998).

The first experimental reproductions of HeV disease were carried out using a mixture of virus-infected lung and spleen homogenate that was prepared from two naturally infected horse field cases and used to inoculate horses i.v. and i.n. In addition, other horses were inoculated i.v. with a high dose of cell culture derived virus, ( $1 \times 10^7$  TCID<sub>50</sub> + i.n.-aerosol;  $2 \times 10^7$  TCID<sub>50</sub>) (Murray et al. 1995a, b). HeV infection was characterized by pulmonary edema and congestion, hemorrhage, thrombosis of capillaries, necrosis, and syncytial cells in the endothelium of pulmonary vessels. Additional HeV challenge experiments in horses have detailed the presence of viral antigen in endothelial cells in a wide variety of organs including lungs, lymph nodes, kidneys, spleen, bladder, and meninges. Virus can be recovered from a number of internal organs, including lung, and from saliva and urine (Murray et al. 1995a, b; Hooper et al. 1997a; Williamson et al. 1998; Marsh et al. 2011). The development of an experimental model of HeV infection in horses has been important for understanding the pathogenesis of the virus and the associated risk of transmission to humans, and will also be critical for the testing of vaccines against HeV infection of horses.

#### ***4.4 Cat Model***

Following either NiV or HeV infection in the cat by either s.c. or oronasal inoculation, the first clinical signs are typically observed between 4 and 8 days and include depression, fever, and elevated rates of respiration (Westbury et al. 1995, 1996; Hooper et al. 1997b; Mungall et al. 2006). Most infected cats die or require euthanasia within 24 h after the appearance of respiratory distress. HeV or NiV infection and the resulting disease in cats closely resembles the respiratory disease presentation that is seen in naturally occurring HeV-infected horses, often with copious frothy sanguineous fluid in the bronchi and hemorrhage or congestion of the tracheal epithelium (Hooper et al. 1997b). Virus replication and resulting systemic vasculitis is present in both arteries and arterioles and syncytia are observed in the endothelia especially in the lungs, but also in gastrointestinal, spleen, and lymphoid organs.

Cats inoculated with HeV also shed virus in urine and infected cats in similar cages were able to transmit infection to one of three contact horses. A notable difference between NiV and HeV infection of cats is the extensive degree to which NiV, but not HeV, infects the respiratory epithelium (Middleton et al. 2002).

In addition, NiV can transplacentally infect and replicate in fetal tissues with high levels of recoverable virus from the placenta and uterine fluid (Mungall et al. 2007). Taken together, despite some limitations, particularly that henipavirus encephalitis in the cat has not been experimentally reproduced these studies indicated that the cat was a viable and reproducible animal model for lethal henipavirus infection and disease. The cat model has been successfully used in challenge and protection experiments in the evaluation of a subunit vaccine for NiV (McEachern et al. 2008).

#### ***4.5 Golden Syrian Hamster Model***

Studies in hamsters have yielded different results following NiV infection. One study showed that pathological lesions were most severe and extensive in the hamster brain (Wong et al. 2003). In this study hamsters succumbed 5–9 days after i.p. administration of 100–10,000 PFU and 24 h after the appearance of tremors and limb paralysis. In this same study, hamsters inoculated i.n. with doses as high as  $10^3$ – $10^6$  PFU succumbed between 9 and 15 days after NiV challenge, displaying progressive deterioration with limb paralysis, lethargy, limb twitching, and breathing difficulties. Vascular pathology was observed in a range of organs, including brain, lung, liver, kidney, and heart, and viral antigen and genome were found in endothelial cells. The vascular and parenchyma lesions were consistent with CNS-mediated clinical signs. A more recent study reported that hamsters inoculated i.n. or i.p. with  $10^5$  TCID<sub>50</sub> succumbed within 5 days after exposure to NiV while hamsters inoculated i.n. or i.p. with  $10^2$  TCID<sub>50</sub> died by day 12 after NiV challenge (Rockx et al. 2011). This study also reported that disease in hamsters exposed to higher doses of NiV resulted in acute respiratory distress (ARDS) whereas infection of hamsters with lower doses of NiV resulted in the development of neurological signs and more systemic spread of the virus through involvement of the endothelium. It is unclear why one study using doses of  $10^3$  to  $10^6$  PFU caused a disease dominated by neurologic signs (Wong et al. 2003) where a similar study using a similar dose ( $10^5$  TCID<sub>50</sub>) caused a disease dominated by respiratory signs (Rockx et al. 2011). The NiV hamster model has been successfully used in experiments to evaluate several vaccines and postexposure treatments (Guillaume et al. 2004, 2006; Georges-Courbot et al. 2006; Freiberg et al. 2010).

HeV infection of hamsters appears to more closely resemble the pathology seen in acute human cases, including both respiratory and brain pathology (Guillaume et al. 2009). HeV-induced pathology in the hamster consisted of endothelial infection and vasculitis with thrombosis and microinfarction, with evidence of direct parenchymal cell infection, notably in the CNS. As was reported for NiV disease in hamsters exposed to higher doses NiV (Rockx et al. 2011), higher doses of HeV ( $10^5$  TCID<sub>50</sub>) resulted in ARDS whereas infection of hamsters with lower doses of HeV ( $10^2$  TCID<sub>50</sub>) resulted in the development of neurological signs (Rockx et al. 2011). Hamsters have been used in a few studies to evaluate the potential of antiviral therapies against HeV (Guillaume et al. 2009; Freiberg et al. 2010).

Of additional importance regarding the use of hamsters as models for henipavirus infection are findings suggesting that the sensitivity to HeV infection may decrease with the increasing age of the animals (Guillaume et al. 2009).

#### ***4.6 Ferret Model***

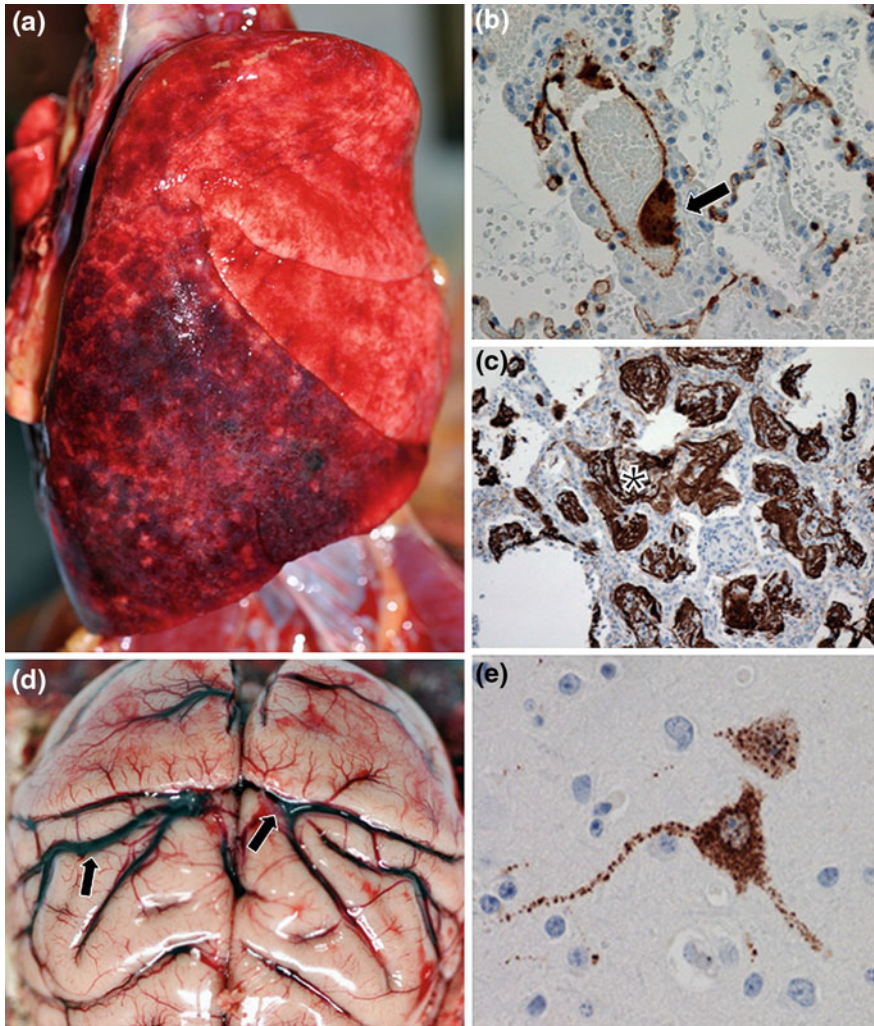
Ferret models of NiV and HeV infection and pathogenesis have been recently developed and characterized (Bossart et al. 2009; Pallister et al. 2009, 2011). The henipavirus infected ferret reveals both severe respiratory and neurological disease, along with generalized vasculitis following oral-nasal challenge with NiV with low doses (500 TCID<sub>50</sub>) within 6–10 days post-infection (Bossart et al. 2009; Pallister et al. 2009). Disease signs in NiV-infected ferrets are various combinations of severe depression, cough, serous nasal discharge, dyspnea, s.c edema of the head, cutaneous ecchymoses, and obtundation along with tremor and hind limb paresis depending on the challenge dose. Pathological findings in the ferret included vascular fibrinoid necrosis in multiple organs, necrotizing alveolitis, and syncytia of endothelium and alveolar epithelium. Histopathological lesions included severe focal necrotizing alveolitis, vasculitis, degeneration of glomerular tufts, and focal necrosis in a wide-range of other tissues. Significant amounts of viral antigen are present in blood vessel walls and endothelial syncytia are frequently present. Viral antigen was also present in the brain parenchyma including neurons and infectious NiV was isolated from multiple organs including the brain. In total, the NiV-mediated disease process observed in the ferret accurately reflects the disease manifestation observed in NiV-infected humans.

Ferrets infected by an oral-nasal challenge with doses of HeV ranging from 50 to 50,000 TCID<sub>50</sub> succumbed 6–9 days after exposure (Pallister et al. 2011). Clinical signs in HeV-infected ferrets are essentially identical to those reported for NiV-infected ferrets and included severe depression and generalized tremors. Histological examination showed systemic vasculitis, splenitis, and bronchiol-alveolitis with syncytial cell formation.

#### ***4.7 Nonhuman Primate Model***

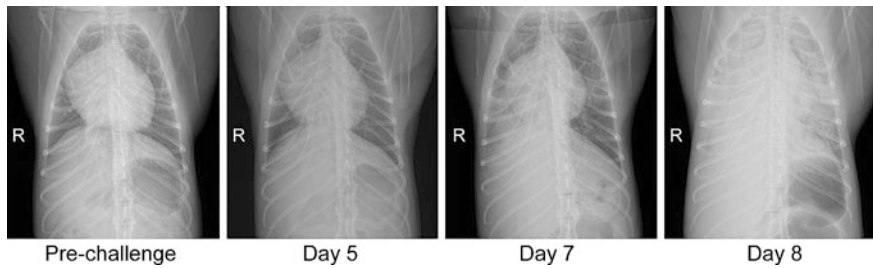
Nonhuman primate models of henipavirus infection have been developed using the African green monkey (AGM) which yields a consistent lethal infection and disease with low dose challenge;  $\sim 2 \times 10^4$  PFU (NiV) (Geisbert et al. 2010) or  $4 \times 10^5$  TCID<sub>50</sub> of HeV (Rockx et al. 2010). Virus challenge by intratracheal (i.t.) inoculation with either NiV or HeV of AGMs, results in a rapid spread of virus within 3–4 days and the establishment of infection in multiple organ systems. Both NiV- and HeV-infected monkeys developed a severe ARDS-like disease, associated with copious amounts of sanguinous fluid and froth. The lungs are





**Fig. 1** Henipavirus pathology in the African green monkey. **a** Severely enlarged lungs; multifocal areas of congestion and hemorrhage of NiV-infected animal; **b** localization of NiV by immunohistochemical stain within a lung blood vessel with endothelial syncytia (*arrow*) and scattered foci of immunopositive cells (*brown*) abundant in alveolar septae (original magnification, 40 $\times$ ); **c** right diaphragmatic lobe of lung of a NiV-infected animal by immunohistochemical stain showing abundance of polymerized fibrin (*asterisk*) in and around alveolar spaces (original magnification, 40 $\times$ ); **d** congestion of the brain of a HeV-infected animal (*black arrows*); **e** detection of HeV antigen in neuron cell body and axon (original magnification, 40 $\times$ ). Panels **b** and **c** from (Geisbert et al. 2010); panel **d** from (Rockx et al. 2010)

consistently enlarged with multifocal areas of congestion and hemorrhage (Fig. 1a) and immunohistochemical and histopathological examination revealed significant amounts of NiV antigen (Fig. 1b) and polymerized fibrin (Fig. 1c).



**Fig. 2** Radiological and gross pathological changes in lungs of HeV-infected African green monkeys. Radiological progression of respiratory disease in an animal euthanized on day 8 due after i.t. exposure due to severe respiratory distress. First evidence of congestion was observed at day 7 post-infection and infection rapidly progressed to diffuse interstitial infiltrates and pulmonary consolidation by day 8 post-infection. R, right side. Figure from (Rockx et al. 2010)

Evidence of endothelial syncytia are prominent in most of the tissues and vasculitis was systemic. Viral antigen was also present in endothelial and arterial smooth muscle cells in most examined tissues. Respiratory disease typically manifested within 7 days post-challenge with either NiV or HeV following i.t. inoculation by radiological examination, and progressed to severe congestion and infiltration in the lung fields (Fig. 2).

At the time of death in the AGM, virus could be found in virtually every organ system sampled. Immunohistochemical analysis revealed the presence of viral antigen, predominantly in endothelial cells and smooth muscle cells, along with associated pathology. In addition, and of importance to the similarity of disease seen in humans, most infected AGMs have shown evidence of henipavirus-induced neurologic disease, with severe congestion (Fig. 1d) and evidence of meningeal hemorrhaging and edema. In the CNS, viral antigen was detected in endothelial cells in brain along with infection of neurons (Fig. 1e) and typically widespread in the brainstem. As was shown in the hamster models for henipavirus infection challenge dose appears to have some influence on the disease course and pathology. In general, AGM exposed to lower doses of NiV ( $<10^5$  PFU) survive longer than animals exposed to higher doses of NiV ( $>10^5$  PFU) with animals that succumb earlier showing more respiratory signs of disease and animals surviving longer showing more neurologic signs of disease (Geisbert and Broder Unpublished).

The AGM HeV model has been used in two challenge and protection experiments: (1) an evaluation of ribavirin as a prophylactic and postexposure treatment (Rockx et al. 2010) and (2) an evaluation of the recombinant human monoclonal antibody m102.4 as a postexposure treatment (Bossart et al. 2011).

NiV infection of squirrel monkeys has also been examined (Marianneau et al. 2010); however, only some animals demonstrated limited similarities to NiV pathogenesis in humans and only half of the number of challenged animals exhibited any clinical signs of disease with most challenged animals remaining well, even after i.n. or i.v. delivery of doses as high as  $10^7$  PFU of NiV.

In contrast to the guinea pig, feline, hamster, and squirrel monkey models of henipavirus infection, both neurological disease and severe respiratory pathology along with generalized vasculitis all occur in AGMs infected with either NiV or HeV, and the AGM model provides an accurate reflection of what is observed in henipavirus-infected humans.

## 5 Routes of Experimental Exposure and Dose

Early studies to develop animal models evaluated a number of challenge routes including intradermal, s.c., i.n., oral, i.t., i.v., and i.p., and in some cases various combinations of these routes. As studies have progressed, most animal models now focus on either the presumed natural oronasal routes or explore oronasal versus i.p. or s.c. exposures in order to examine pathogenic outcomes and disease processes (Rockx et al. 2011).

In addition, there has also been a limited number of animal transmission or in-contact studies in horses, bats, pigs, cats, and hamsters (Westbury et al. 1996; Williamson et al. 1998; Middleton et al. 2002; Wong et al. 2003; de Wit et al. 2012). Horse–horse, bat–horse, bat–bat, and cat–horse transmission studies have nearly all been unsuccessful under the limited experimental conditions and attempts to date. Notably, even horse-to-horse transmission of HeV has not been convincingly demonstrated (Williamson et al. 1998); however, good evidence of cat–cat transmission of HeV has been shown between infected and in-contact cats within the same confines (Westbury et al. 1996). The conclusions from these studies indicate that HeV is not highly infectious, even between horses, and indeed HeV is rarely found in the bronchi or bronchioles of infected horses, suggesting that aerosol transmission to either humans or horses maybe less likely (Hooper et al. 1997a).

In regards to natural routes of virus transmission, the importance of pregnancy and fetal materials in disease spread was first hypothesized after the discovery that the index case of the 1994 HeV outbreak was a pregnant mare (Murray et al. 1995a, b) and vertical (in utero) transmission of HeV was later experimentally confirmed in guinea pigs and bats (Williamson et al. 2000). More recently, in utero transmission of NiV in cats has also been reported with evidence of a high level of virus replication in many tissues of a pregnant adult cat and in fetal tissues suggesting both vertical and horizontal transmission of this virus is possible (Mungall et al. 2007).

Guinea pigs and pigs are somewhat resistant to infection and disease caused by HeV and NiV, respectively, when the viruses are administered by the oronasal compared with the s.c. route (Williamson et al. 2001; Middleton et al. 2002). HeV has only been used to challenge pigs oronasally (Landrace pigs;  $6.6 \times 10^7$  PFU) or i.n. (Gottingen minipigs;  $2.0 \times 10^7$  PFU) (Li et al. 2010). In contrast, HeV and NiV appear to be equally infectious for cats following either parenteral (5,000 TCID<sub>50</sub> virus) or oronasal (50,000 TCID<sub>50</sub> virus) administration (Westbury et al. 1996; Hooper et al. 1997b; Middleton et al. 2002; Mungall et al. 2006;

McEachern et al. 2008). In general, higher doses in a number of animal species, particularly monkeys (Geisbert and Broder, unpublished) and hamsters (Rockx et al. 2011) has shown more rapid onset of fatal disease.

## 6 Epilogue

In this chapter, we have outlined what is known about the pathology and pathogenesis of human henipavirus infection and reviewed studies describing the development and use of animal models. Neither HeV or NiV productively infects or causes disease in typical small animal models, including mice or rabbits (reviewed in Bossart et al. (2007) and Bishop and Broder (2008)). Among other smaller animal models explored, the response to either HeV or NiV in guinea pigs was reported to be highly variable. Although a generalized vascular disease was observed with HeV in guinea pigs there was little or no pulmonary edema (Hooper et al. 1997b; Williamson et al. 2001). Infection of guinea pigs with high doses of NiV ( $10^7$  PFU) showed only transient clinical signs followed by recovery (Wong et al. 2003) and another study using a high dose of virus by intraperitoneal administration produced disease in less than half of challenged animals (Middleton et al. 2007). There have also been some potential limitations noted in two other well-characterized animal models, the cat and hamster (Westbury et al. 1996; Hooper et al. 1997b; Wong et al. 2003; Mungall et al. 2006, 2007), particularly no overt CNS pathogenesis or respiratory disease, respectively. Of the small animal models evaluated to date, only the recently described ferret models of HeV and NiV infection exhibited both severe respiratory and neurological disease and generalized vasculitis in which the underlying pathology closely resembled henipavirus-mediated disease seen in humans (Bossart et al. 2009). Not surprisingly, the animal model which appears to most faithfully reproduce human henipavirus infection is the AGM (Geisbert et al. 2010; Rockx et al. 2010; Bossart et al. 2011).

## References

- Anonymous (1999) Update: outbreak of Nipah virus—Malaysia and Singapore. *MMWR Morb Mortal Wkly Rep* 48:335–337
- Anonymous (2009) Hendra virus, human, equine—Australia (04): (Queensland) Fatal. *ProMed Mail Archive* Number: 20090903.3098
- Anonymous (2011a) Hendra virus, equine—Australia (21): (Queensland) Canine. *ProMed Mail Archive* Number: 20110802.2324
- Anonymous (2011b) Hendra virus, equine—Australia (28): (Queensland, New South Wales). *ProMed Mail Archive* Number: 20111013.3061
- Arankalle VA, Bandyopadhyay BT, Ramdasi AY, Jadi R, Patil DR, Rahman M, Majumdar M, Banerjee PS, Hati AK, Goswami RP, Neogi DK, Mishra AC (2011) Genomic characterization of Nipah virus, West Bengal, India. *Emerg Infect Dis* 17:907–909

- Berhane Y, Weingartl HM, Lopez J, Neufeld J, Czub S, Embury-Hyatt C, Goolia M, Copps J, Czub M (2008) Bacterial infections in pigs experimentally infected with Nipah virus. *Transbound Emerg Dis* 55:165–174
- Bishop KA, Broder CC (2008) Hendra and Nipah: lethal zoonotic paramyxoviruses. In: Scheld WM, Hammer SM, Hughes JM (eds) *Emerging infections*, vol 8. American Society for Microbiology, Washington, pp 155–187
- Bossart KN, Bingham J, Middleton D (2007) Targeted strategies for Henipavirus therapeutics. *Open Virol J* 1:14–25
- Bossart KN, Zhu Z, Middleton D, Klippel J, Cramer G, Bingham J, McEachern JA, Green D, Hancock TJ, Chan YP, Hickey AC, Dimitrov DS, Wang LF, Broder CC (2009) A neutralizing human monoclonal antibody protects against lethal disease in a new ferret model of acute nipah virus infection. *PLoS Pathog* 5:e1000642
- Bossart KN, Geisbert TW, Feldmann H, Zhu Z, Feldmann F, Geisbert JB, Yan L, Feng YR, Brining D, Scott D, Wang Y, Dimitrov AS, Callison J, Chan YP, Hickey AC, Dimitrov DS, Broder CC, Rockx B (2011) A neutralizing human monoclonal antibody protects african green monkeys from hendra virus challenge. *Sci Transl Med* 3: 105ra103
- Chadha MS, Comer JA, Lowe L, Rota PA, Rollin PE, Bellini WJ, Ksiazek TG, Mishra A (2006) Nipah virus-associated encephalitis outbreak, Siliguri, India. *Emerg Infect Dis* 12:235–240
- Chong HT, Tan CT (2003) Relapsed and late-onset Nipah encephalitis, a report of three cases. *Neurol J Southeast Asia* 8:109–112
- Chua KB (2003) Nipah virus outbreak in Malaysia. *J Clin Virol* 26:265–275
- Chua KB, Goh KJ, Wong KT, Kamarulzaman A, Tan PS, Ksiazek TG, Zaki SR, Paul G, Lam SK, Tan CT (1999) Fatal encephalitis due to Nipah virus among pig-farmers in Malaysia. *Lancet* 354:1257–1259
- Chua KB, Bellini WJ, Rota PA, Harcourt BH, Tamin A, Lam SK, Ksiazek TG, Rollin PE, Zaki SR, Shieh W, Goldsmith CS, Gubler DJ, Roehrig JT, Eaton B, Gould AR, Olson J, Field H, Daniels P, Ling AE, Peters CJ, Anderson LJ, Mahy BW (2000) Nipah virus: a recently emergent deadly paramyxovirus. *Science* 288:1432–1435
- Chua KB, Koh CL, Hooi PS, Wee KF, Khong JH, Chua BH, Chan YP, Lim ME, Lam SK (2002) Isolation of Nipah virus from Malaysian Island flying-foxes. *Microbes Infect* 4:145–151
- Daniels P, Ksiazek T, Eaton BT (2001) Laboratory diagnosis of Nipah and Hendra virus infections. *Microbes Infect* 3:289–295
- de Wit E, Bushmaker T, Scott D, Feldmann H, Munster V (2012) Nipah virus transmission in a hamster model. *PLoS Negl Trop Dis* 5:e1432
- Eaton BT, Broder CC, Middleton D, Wang LF (2006) Hendra and Nipah viruses: different and dangerous. *Nat Rev Microbiol* 4:23–35
- Field H, Young P, Yob JM, Mills J, Hall L, Mackenzie J (2001) The natural history of Hendra and Nipah viruses. *Microbes Infect* 3:307–314
- Freiberg AN, Worthy MN, Lee B, Holbrook MR (2010) Combined chloroquine and ribavirin treatment does not prevent death in a hamster model of Nipah and Hendra virus infection. *J Gen Virol* 91:765–772
- Geisbert TW, Daddario-DiCaprio KM, Hickey AC, Smith MA, Chan YP, Wang LF, Mattapallil JJ, Geisbert JB, Bossart KN, Broder CC (2010) Development of an acute and highly pathogenic nonhuman primate model of Nipah virus infection. *PLoS ONE* 5:e10690
- Georges-Courbot MC, Contamin H, Faure C, Loth P, Baize S, Leyssen P, Neyts J, Deubel V (2006) Poly(I)-poly(C12U) but not ribavirin prevents death in a hamster model of Nipah virus infection. *Antimicrob Agents Chemother* 50:1768–1772
- Goh KJ, Tan CT, Chew NK, Tan PS, Kamarulzaman A, Sarji SA, Wong KT, Abdullah BJ, Chua KB, Lam SK (2000) Clinical features of Nipah virus encephalitis among pig farmers in Malaysia. *N Engl J Med* 342:1229–1235
- Guillaume V, Contamin H, Loth P, Georges-Courbot MC, Lefevre A, Marianneau P, Chua KB, Lam SK, Buckland R, Deubel V, Wild TF (2004) Nipah virus: vaccination and passive protection studies in a hamster model. *J Virol* 78:834–840

- Guillaume V, Contamin H, Loth P, Grosjean I, Courbot MC, Deubel V, Buckland R, Wild TF (2006) Antibody prophylaxis and therapy against Nipah virus infection in hamsters. *J Virol* 80:1972–1978
- Guillaume V, Wong KT, Looi RY, Georges-Courbot MC, Barrot L, Buckland R, Wild TF, Horvat B (2009) Acute Hendra virus infection: analysis of the pathogenesis and passive antibody protection in the hamster model. *Virology* 387:459–465
- Gurley ES, Montgomery JM, Hossain MJ, Bell M, Azad AK, Islam MR, Molla MA, Carroll DS, Ksiazek TG, Rota PA, Lowe L, Comer JA, Rollin P, Czub M, Grolla A, Feldmann H, Luby SP, Woodward JL, Breiman RF (2007) Person-to-person transmission of Nipah virus in a Bangladeshi community. *Emerg Infect Dis* 13:1031–1037
- Halpin K, Young PL, Field HE, Mackenzie JS (2000) Isolation of Hendra virus from pteropid bats: a natural reservoir of Hendra virus. *J Gen Virol* 81:1927–1932
- Halpin K, Hyatt AD, Fogarty R, Middleton D, Bingham J, Epstein JH, Rahman SA, Hughes T, Smith C, Field HE, Daszak P (2011) Pteropid bats are confirmed as the reservoir hosts of henipaviruses: a comprehensive experimental study of virus transmission. *Am J Trop Med Hyg* 85:946–951
- Hanna JN, McBride WJ, Brookes DL, Shield J, Taylor CT, Smith IL, Craig SB, Smith GA (2006) Hendra virus infection in a veterinarian. *Med J Aust* 185:562–564
- Harit AK, Ichhpujani RL, Gupta S, Gill KS, Lal S, Ganguly NK, Agarwal SP (2006) Nipah/Hendra virus outbreak in Siliguri, West Bengal, India in 2001. *Indian J Med Res* 123:553–560
- Hayman DT, Suu-Ire R, Breed AC, McEachern JA, Wang L, Wood JL, Cunningham AA (2008) Evidence of henipavirus infection in West African fruit bats. *PLoS ONE* 3:e2739
- Homaira N, Rahman M, Hossain MJ, Epstein JH, Sultana R, Khan MS, Podder G, Nahar K, Ahmed B, Gurley ES, Daszak P, Lipkin WI, Rollin PE, Comer JA, Ksiazek TG, Luby SP (2010) Nipah virus outbreak with person-to-person transmission in a district of Bangladesh, 2007. *Epidemiol Infect* 138:1630–1636
- Hooper PT, Gould AR, Russell GM, Kattenbelt JA, Mitchell G (1996) The retrospective diagnosis of a second outbreak of equine morbillivirus infection. *Aust Vet J* 74:244–245
- Hooper PT, Ketterer PJ, Hyatt AD, Russell GM (1997a) Lesions of experimental equine morbillivirus pneumonia in horses. *Vet Pathol* 34:312–322
- Hooper PT, Westbury HA, Russell GM (1997b) The lesions of experimental equine morbillivirus disease in cats and guinea pigs. *Vet Pathol* 34:323–329
- Hooper P, Zaki S, Daniels P, Middleton D (2001) Comparative pathology of the diseases caused by Hendra and Nipah viruses. *Microbes Infect* 3:315–322
- Hsu VP, Hossain MJ, Parashar UD, Ali MM, Ksiazek TG, Kuzmin I, Niezgodna M, Rupprecht C, Bresee J, Breiman RF (2004) Nipah virus encephalitis reemergence, Bangladesh. *Emerg Infect Dis* 10:2082–2087
- Li Y, Wang J, Hickey AC, Zhang Y, Wu Y, Zhang H, Yuan J, Han Z, McEachern J, Broder CC, Wang LF, Shi Z (2008) Antibodies to Nipah or Nipah-like viruses in bats, China. *Emerg Infect Dis* 14:1974–1976
- Li M, Embury-Hyatt C, Weingartl HM (2010) Experimental inoculation study indicates swine as a potential host for Hendra virus. *Vet Res* 41:33
- Luby SP, Rahman M, Hossain MJ, Blum LS, Husain MM, Gurley E, Khan R, Ahmed BN, Rahman S, Nahar N, Kenah E, Comer JA, Ksiazek TG (2006) Foodborne transmission of Nipah virus, Bangladesh. *Emerg Infect Dis* 12:1888–1894
- Luby SP, Gurley ES, Hossain MJ (2009a) Transmission of human infection with Nipah virus. *Clin Infect Dis* 49:1743–1748
- Luby SP, Hossain MJ, Gurley ES, Ahmed BN, Banu S, Khan SU, Homaira N, Rota PA, Rollin PE, Comer JA, Kenah E, Ksiazek TG, Rahman M (2009b) Recurrent zoonotic transmission of Nipah virus into humans, Bangladesh, 2001–2007. *Emerg Infect Dis* 15:1229–1235
- Marianneau P, Guillaume V, Wong T, Badmanathan M, Looi RY, Murri S, Loth P, Tordo N, Wild F, Horvat B, Contamin H (2010) Experimental infection of squirrel monkeys with Nipah virus. *Emerg Infect Dis* 16:507–510

- Marsh GA, Haining J, Hancock TJ, Robinson R, Foord A, Barr JA, Riddell S, Heine HG, White JR, Crameri G, Field HE, Wang LF, Middleton D (2011) Experimental infection of horses with Hendra virus/Australia/Horse/2008/Redlands. *Emerg Infect Dis* 17:2232–2238
- McEachern JA, Bingham J, Crameri G, Green DJ, Hancock TJ, Middleton D, Feng YR, Broder CC, Wang LF, Bossart KN (2008) A recombinant subunit vaccine formulation protects against lethal Nipah virus challenge in cats. *Vaccine* 26:3842–3852
- Middleton DJ, Westbury HA, Morrissy CJ, van der Heide BM, Russell GM, Braun MA, Hyatt AD (2002) Experimental Nipah virus infection in pigs and cats. *J Comp Pathol* 126:124–136
- Middleton DJ, Morrissy CJ, van der Heide BM, Russell GM, Braun MA, Westbury HA, Halpin K, Daniels PW (2007) Experimental Nipah virus infection in pteropid bats (*Pteropus poliocephalus*). *J Comp Pathol* 136:266–272
- Mills JN, Alim AN, Bunning ML, Lee OB, Wagoner KD, Amman BR, Stockton PC, Ksiazek TG (2009) Nipah virus infection in dogs, Malaysia, 1999. *Emerg Infect Dis* 15:950–952
- Mohd Nor MN, Gan CH, Ong BL (2000) Nipah virus infection of pigs in peninsular Malaysia. *Rev Sci Tech* 19:160–165
- Mungall BA, Middleton D, Crameri G, Bingham J, Halpin K, Russell G, Green D, McEachern J, Pritchard LI, Eaton BT, Wang LF, Bossart KN, Broder CC (2006) Feline model of acute nipah virus infection and protection with a soluble glycoprotein-based subunit vaccine. *J Virol* 80:12293–12302
- Mungall BA, Middleton D, Crameri G, Halpin K, Bingham J, Eaton BT, Broder CC (2007) Vertical transmission and fetal replication of Nipah virus in an experimentally infected cat. *J Infect Dis* 196:812–816
- Murray K, Rogers R, Selvey L, Selleck P, Hyatt A, Gould A, Gleeson L, Hooper P, Westbury H (1995a) A novel morbillivirus pneumonia of horses and its transmission to humans. *Emerg Infect Dis* 1:31–33
- Murray K, Selleck P, Hooper P, Hyatt A, Gould A, Gleeson L, Westbury H, Hiley L, Selvey L, Rodwell B et al (1995b) A morbillivirus that caused fatal disease in horses and humans. *Science* 268:94–97
- O’Sullivan JD, Allworth AM, Paterson DL, Snow TM, Boots R, Gleeson LJ, Gould AR, Hyatt AD, Bradfield J (1997) Fatal encephalitis due to novel paramyxovirus transmitted from horses. *Lancet* 349:93–95
- Pallister J, Middleton D, Crameri G, Yamada M, Klein R, Hancock TJ, Foord A, Shiell B, Michalski W, Broder CC, Wang LF (2009) Chloroquine administration does not prevent Nipah virus infection and disease in ferrets. *J Virol* 83:11979–11982
- Pallister J, Middleton D, Wang LF, Klein R, Haining J, Robinson R, Yamada M, White J, Payne J, Feng YR, Chan YP, Broder CC (2011) A recombinant Hendra virus G glycoprotein-based subunit vaccine protects ferrets from lethal Hendra virus challenge. *Vaccine* 29:5623–5630
- Paton NI, Leo YS, Zaki SR, Auchus AP, Lee KE, Ling AE, Chew SK, Ang B, Rollin PE, Umapathi T, Sng I, Lee CC, Lim E, Ksiazek TG (1999) Outbreak of Nipah-virus infection among abattoir workers in Singapore. *Lancet* 354:1253–1256
- Playford EG, McCall B, Smith G, Slinko V, Allen G, Smith I, Moore F, Taylor C, Kung YH, Field H (2010) Human Hendra virus encephalitis associated with equine outbreak, Australia, 2008. *Emerg Infect Dis* 16:219–223
- Rahman SA, Hassan SS, Olival KJ, Mohamed M, Chang LY, Hassan L, Saad NM, Shohaimi SA, Mamat ZC, Naim MS, Epstein JH, Suri AS, Field HE, Daszak P (2010) Characterization of Nipah virus from naturally infected *Pteropus vampyrus* bats, Malaysia. *Emerg Infect Dis* 16:1990–1993
- Rahman MA, Hossain MJ, Sultana S, Homaira N, Khan SU, Rahman M, Gurley ES, Rollin PE, Lo MK, Comer JA, Lowe L, Rota PA, Ksiazek TG, Kenah E, Sharker Y, Luby SP (2011) Date palm sap linked to Nipah virus outbreak in Bangladesh, 2008. *Vector Borne Zoonotic Dis*
- Reynes JM, Counor D, Ong S, Faure C, Seng V, Molia S, Walston J, Georges-Courbot MC, Deubel V, Sarthou JL (2005) Nipah virus in Lyle’s flying foxes, Cambodia. *Emerg Infect Dis* 11:1042–1047

- Rockx B, Bossart KN, Feldmann F, Geisbert JB, Hickey AC, Brining D, Callison J, Safronetz D, Marzi A, Kercher L, Long D, Broder CC, Feldmann H, Geisbert TW (2010) A novel model of lethal Hendra virus infection in African green monkeys and the effectiveness of ribavirin treatment. *J Virol* 84:9831–9839
- Rockx B, Brining D, Kramer J, Callison J, Ebihara H, Mansfield K, Feldmann H (2011) Clinical outcome of henipavirus infection in hamsters is determined by the route and dose of infection. *J Virol* 85:7658–7671
- Rogers RJ, Douglas IC, Baldock FC, Glanville RJ, Seppanen KT, Gleeson LJ, Selleck PN, Dunn KJ (1996) Investigation of a second focus of equine morbillivirus infection in coastal Queensland. *Aust Vet J* 74:243–244
- Selvey LA, Wells RM, McCormack JG, Ansford AJ, Murray K, Rogers RJ, Lavercombe PS, Selleck P, Sheridan JW (1995) Infection of humans and horses by a newly described morbillivirus. *Med J Aust* 162:642–645
- Smith I, Broos A, de Jong C, Zeddemman A, Smith C, Smith G, Moore F, Barr J, Cramer G, Marsh G, Tachedjian M, Yu M, Kung YH, Wang LF, Field H (2011) Identifying Hendra virus diversity in pteropid bats. *PLoS ONE* 6:e25275
- Sohayati AR, Hassan L, Sharifah SH, Lazarus K, Zaini CM, Epstein JH, Shamsyul Naim N, Field HE, Arshad SS, Abdul Aziz J, Daszak P (2011) Evidence for Nipah virus recrudescence and serological patterns of captive *Pteropus vampyrus*. *Epidemiol Infect* 139:1570–1579
- Tan CT, Wong KT (2003) Nipah encephalitis outbreak in Malaysia. *Ann Acad Med Singapore* 32:112–117
- Tan CT, Goh KJ, Wong KT, Sarji SA, Chua KB, Chew NK, Murugasu P, Loh YL, Chong HT, Tan KS, Thayaparan T, Kumar S, Jusoh MR (2002) Relapsed and late-onset Nipah encephalitis. *Ann Neurol* 51:703–708
- Torres-Velez FJ, Shieh WJ, Rollin PE, Morken T, Brown C, Ksiazek TG, Zaki SR (2008) Histopathologic and immunohistochemical characterization of Nipah virus infection in the guinea pig. *Vet Pathol* 45:576–585
- Weingartl H, Czub S, Copps J, Berhane Y, Middleton D, Marszal P, Gren J, Smith G, Ganske S, Manning L, Czub M (2005) Invasion of the central nervous system in a porcine host by Nipah virus. *J Virol* 79:7528–7534
- Weingartl HM, Berhane Y, Caswell JL, Loosmore S, Audonnet JC, Roth JA, Czub M (2006) Recombinant Nipah virus vaccines protect pigs against challenge. *J Virol* 80:7929–7938
- Westbury HA, Hooper PT, Selleck PW, Murray PK (1995) Equine morbillivirus pneumonia: susceptibility of laboratory animals to the virus. *Aust Vet J* 72:278–279
- Westbury HA, Hooper PT, Brouwer SL, Selleck PW (1996) Susceptibility of cats to equine morbillivirus. *Aust Vet J* 74:132–134
- Williamson MM, Hooper PT, Selleck PW, Gleeson LJ, Daniels PW, Westbury HA, Murray PK (1998) Transmission studies of Hendra virus (equine morbillivirus) in fruit bats, horses and cats. *Aust Vet J* 76:813–818
- Williamson MM, Hooper PT, Selleck PW, Westbury HA, Slocombe RF (2000) Experimental hendra virus infection in pregnant guinea-pigs and fruit bats (*Pteropus poliocephalus*). *J Comp Pathol* 122:201–207
- Williamson MM, Hooper PT, Selleck PW, Westbury HA, Slocombe RF (2001) A guinea-pig model of Hendra virus encephalitis. *J Comp Pathol* 124:273–279
- Wong KT, Ong KC (2011) Pathology of acute henipavirus infection in humans and animals. *Patholog Res Int* 2011:567248
- Wong SC, Ooi MH, Wong MN, Tio PH, Solomon T, Cardoso MJ (2001) Late presentation of Nipah virus encephalitis and kinetics of the humoral immune response. *J Neurol Neurosurg Psychiatry* 71:552–554
- Wong KT, Shieh WJ, Kumar S, Norain K, Abdullah W, Guarner J, Goldsmith CS, Chua KB, Lam SK, Tan CT, Goh KJ, Chong HT, Jusoh R, Rollin PE, Ksiazek TG, Zaki SR (2002) Nipah virus infection: pathology and pathogenesis of an emerging paramyxoviral zoonosis. *Am J Pathol* 161:2153–2167



- Wong KT, Grosjean I, Brisson C, Blanquier B, Fevre-Montange M, Bernard A, Loth P, Georges-Courbot MC, Chevallier M, Akaoka H, Marianneau P, Lam SK, Wild TF, Deubel V (2003) A golden hamster model for human acute Nipah virus infection. *Am J Pathol* 163:2127–2137
- Wong KT, Robertson T, Ong BB, Chong JW, Yaiw KC, Wang LF, Ansford AJ, Tannenberg A (2009) Human Hendra virus infection causes acute and relapsing encephalitis. *Neuropathol Appl Neurobiol* 35:296–305
- Yob JM, Field H, Rashdi AM, Morrissy C, van der Heide B, Rota P, bin Adzhar A, White J, Daniels P, Jamaluddin A, Ksiazek T (2001) Nipah virus infection in bats (order Chiroptera) in peninsular Malaysia. *Emerg Infect Dis* 7: 439–441
- Young PL, Halpin K, Selleck PW, Field H, Gravel JL, Kelly MA, Mackenzie JS (1996) Serologic evidence for the presence in Pteropus bats of a paramyxovirus related to equine morbillivirus. *Emerg Infect Dis* 2:239–240