

Transendocardial CD34⁺ Cell Transplantation in Noncompaction Cardiomyopathy: First-in-Man Case Study

Cell Transplantation
2018, Vol. 27(7) 1027–1030
© The Author(s) 2018
Article reuse guidelines:
sagepub.com/journals-permissions
DOI: 10.1177/0963689718779349
journals.sagepub.com/home/ccl


Andraz Cerar¹, Gregor Zemljic¹, Sabina Frljak¹, Martina Jaklic¹,
Gregor Poglajen¹, Matjaz Sever², Marko Cukjati³, and Bojan Vrtovec¹

Abstract

Noncompaction cardiomyopathy is a rare congenital heart disorder characterized by an arrest of the myocardial compaction process. This results in the altered formation of coronary microvessels with a resulting decrease in myocardial perfusion. Transendocardial CD34⁺ cell transplantation has been shown to increase myocardial perfusion and function in patients with non-ischemic heart failure. In our first-in-man case study, we investigated the feasibility, safety and clinical effect of transendocardial CD34⁺ cell therapy in a patient with noncompaction cardiomyopathy.

Keywords

Noncompaction cardiomyopathy, myocardial perfusion, CD34⁺ stem cells, transendocardial transplantation

Introduction

Noncompaction cardiomyopathy (NCC) is a rare congenital heart disease that results in an arrest of the myocardial compaction process in the embryonic period. The myocardium is formed into two distinct layers – a compacted and noncompacted layer, the latter characterized by prominent myocardial trabeculations and deep intertrabecular recesses¹. The compaction process is also responsible for the formation of coronary microvessels, its arrest resulting in a decrease of myocardial perfusion².

Despite prominent hypertrabeculation of the left ventricle, where morphological criteria for NCC are met, the left ventricle ejection fraction (LVEF) is often normal and patients are asymptomatic for longer periods of time. However, symptoms of heart failure can occur at any age, and the patients can decline rapidly. NCC is associated with supra- and ventricular arrhythmias or even sudden cardiac death. Due to blood stasis in deep intertrabecular recesses, thromboembolic events are possible, especially in patients with reduced LVEF^{1,3}. Outcomes are poor in many reports, and often advanced heart failure treatment is required³.

So far, no causal treatment of NCC has been found. Therapy for NCC is directed mainly toward the symptomatic therapy of myocardial dysfunction or arrhythmias or both. In case of systolic or diastolic dysfunction, patients with NCC should be managed on the basis of existing guidelines⁴. Prevention of thromboembolic complications, especially in

patients with reduced ejection fraction, is mandatory⁵. As primary or secondary prevention of sudden cardiac death, implantation of a cardioverter defibrillator is recommended in conjunction with anti-arrhythmic therapy⁴. Cardiac resynchronization therapy has shown to be effective in some patients with left bundle branch block⁶.

Unfortunately, no relevant studies have been published to show any benefit of cardioprotective therapy. Patients with NCC often deteriorate to end-stage heart failure, needing inotropic support and/or heart transplantation. Should the deterioration be rapid, implantation of left ventricular assist devices (LVAD) can be an only option as a bridge to transplant, however, few case reports describe LVAD implantation and management is more challenging⁷.

¹ Advanced Heart Failure and Transplantation Center, Department of Cardiology, UMC Ljubljana, Ljubljana, Slovenia

² Department of Hematology, UMC Ljubljana, Ljubljana, Slovenia

³ National Blood Transfusion Institute, Ljubljana, Slovenia

Submitted: December 16, 2017. Revised: April 18, 2018. Accepted: April 18, 2018.

Corresponding Author:

Bojan Vrtovec, Advanced Heart Failure and Transplantation Center, Department of Cardiology, University Medical Center Ljubljana, Zaloska 7, SI-1000 Ljubljana, Slovenia.

Email: bvrtovec@stanford.edu



Creative Commons Non Commercial CC BY-NC: This article is distributed under the terms of the Creative Commons Attribution-NonCommercial 4.0 License (<http://www.creativecommons.org/licenses/by-nc/4.0/>) which permits non-commercial use, reproduction and distribution of the work without further permission provided the original work is attributed as specified on the SAGE and Open Access pages (<https://us.sagepub.com/en-us/nam/open-access-at-sage>).

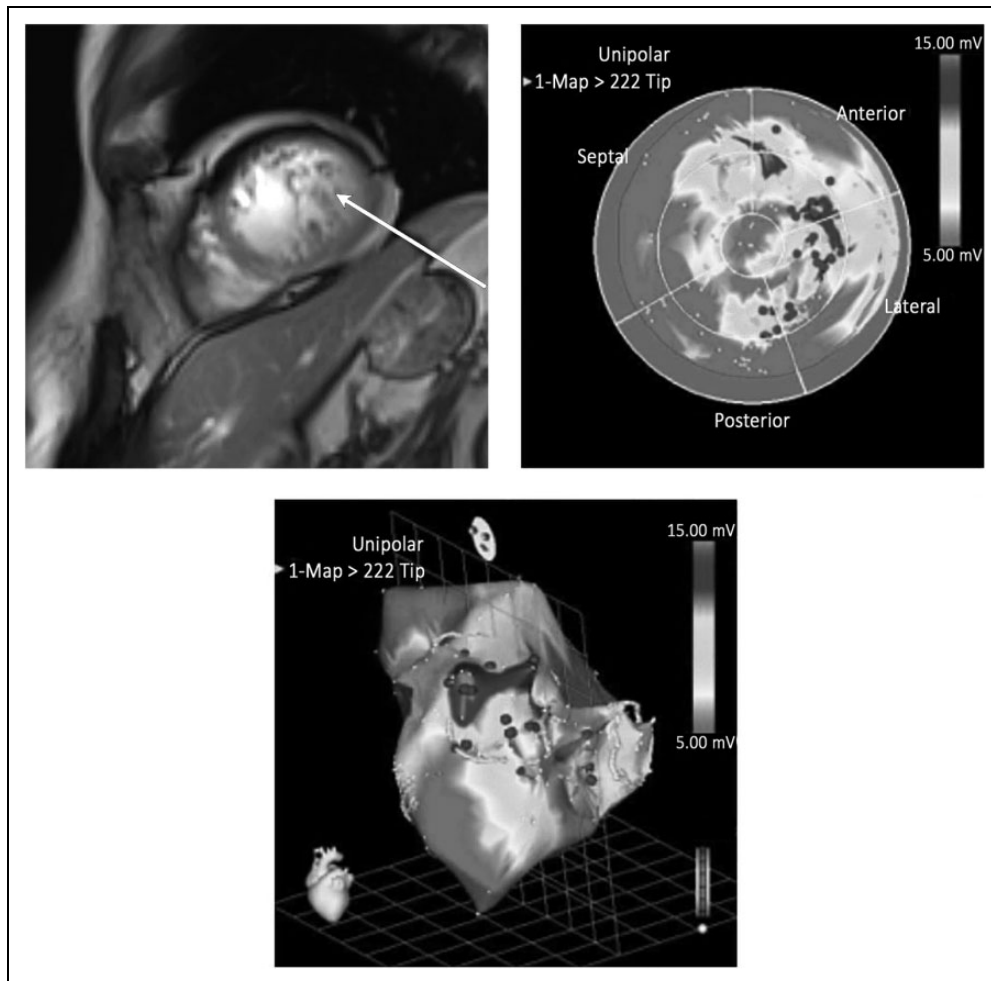


Fig. 1. In trabeculated areas, confirmed by MRI (left panel, trabeculations marked with an arrow), transendocardial CD34⁺ cell injection was performed (middle panel, 3D reconstruction below). MRI: magnetic resonance imaging.

Data from recent studies suggest that intramyocardial CD34⁺ stem cell injection improves perfusion in patients with non-ischemic cardiomyopathy due to the incorporation of stem cells into the developing vasculature and secretion of angiogenetic cytokines adjacent to the stem cell injection site^{8,9}. Since a perfusion defect could represent the key underlying process of disease progression in NCC, CD34⁺ cell therapy could potentially improve perfusion and halt the progression of disease in this patient population. Based on this hypothesis, we performed a first-in-man case study investigating the feasibility and safety of transendocardial CD34⁺ cell transplantation in NCC.

Case Report

We would like to present a 28-year old female with diagnosed NCC. She has been followed in our outpatient clinic since 2006 on optimal heart failure medical therapy with carvedilol 25 mg bid, enalapril 10 mg bid and spironolactone 25 mg qid. Echocardiography showed a moderately enlarged

left ventricle with decreased systolic function (LVEF 35%). Coronary artery disease has been ruled out. Cardiac magnetic resonance imaging (cMRI) confirmed trabeculations in the lateral, apical and inferior segments of the left ventricle, which met the diagnostic criteria for NCC (measured up to 3.5:1 in diastole in the apicolateral and partly anterior area). Despite long-term optimal medical therapy, she remained symptomatic (New York Heart Association (NYHA) class II/III). Extensive genetic testing has unfortunately not been performed yet and she had no family history of heart disease.

Due to persistent heart failure symptoms, after obtaining informed consent from the patient and approval of the National Medical Ethics Committee (number 425-2007/08), we enrolled the patient using a protocol which has been shown to be safe and effective for patients with non-ischemic dilated cardiomyopathy⁸. Stimulation of bone marrow has been performed with granulocyte colony-stimulating factor (G-CSF) in a dose of 960 µg daily for 5 consecutive days. On day 5 venous peripheral blood apheresis and immunoselection were used to isolate CD34⁺ cells.

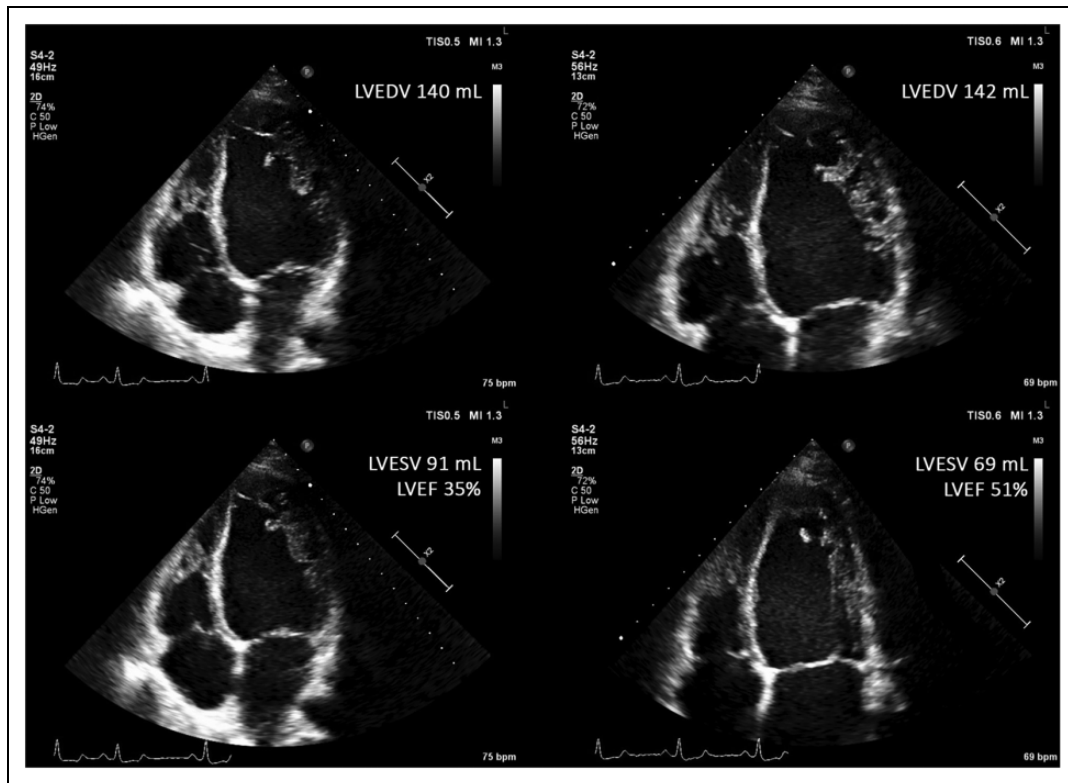


Fig. 2. Echocardiography still images of our patient before (left hand side) and after (right hand side) CD34⁺ cell injection, showing improvement of LVEF from 35 to 51%.

LVEDV: end-diastolic volume; LVEF: left ventricular ejection fraction; LVESV: end-systolic volume.

Electroanatomical mapping was performed using the Biosense NOGA system (Biosense-Webster, Diamond Bar, CA, USA) to generate colour-coded unipolar voltage and linear shortening maps and their corresponding ‘bull’s eye’ maps, consisting of at least 150 sampling points. In accordance with previous studies in non-ischemic dilated cardiomyopathy⁸, target segments were defined as areas with average unipolar voltage ≥ 8.27 mV and average linear shortening $< 6\%$. The scarred myocardium was defined as area with unipolar voltage < 8.27 mV and linear shortening $< 6\%$ and normal myocardium was defined as area with unipolar voltage ≥ 8.27 mV and linear shortening $\geq 6\%$. Transendocardial delivery of cell suspension to targeted segments that also displayed evidence of myocardial trabeculations on cMRI was performed with MyoStar[®] (Biosense-Webster) injection catheter. The patient received 20 injections of stem cell suspension (0.3 ml each, altogether 54×10^6 CD34⁺ cells) into the inferior and lateral wall of the left ventricle (Fig. 1). The procedure was uneventful, and the patient was discharged home 24 hours thereafter.

During the 1-year follow up we found a significant improvement in heart failure symptoms (from NYHA II/II to NYHA I class); echocardiography has shown an improvement of LVEF (from 35% to 51%, Fig. 2), with no change in left ventricular size (140 mL during the entire follow up). N-terminal prohormone of brain natriuretic peptide

(NT-proBNP) levels decreased from 379 to 119 ng/L, and the 6-minute walk test distance increased from 490 to 610 metres. The cMRI has been repeated at 15 months after stem cell injection, confirming no difference in the anatomical substrate (trabeculated areas) compared with baseline cMRI.

Discussion

Noncompaction cardiomyopathy is a congenital disease that occurs due to an arrest of myocardial compaction process in embryonic period, which is also responsible for the formation of coronary microvessels. An arrest of myocardial compaction process leads to the inappropriate formation of coronary microvessels. A decreased myocardial perfusion in noncompacted areas has been shown in previous case reports and small studies, even though epicardial coronary arteries appear normal^{2,10}. It is possible that perfusion deficit could, under exertion, lead to subendocardial ischemia, although no clear evidence of it has been shown yet. It is thought that decreased myocardial perfusion and possible ischemia are the main culprits for left ventricular systolic dysfunction, leading to heart failure symptoms. Despite optimal medical treatment, worsening of myocardial function, leading to advanced heart failure is often observed^{1,3}.

The data from previous studies suggest improvement of perfusion in areas adjacent to intramyocardial CD34⁺ stem

cell injection in patients with non-ischemic cardiomyopathy. The stem cells incorporate into the developing vasculature and secrete angiogenic cytokines^{8,9}. Based on this hypothesis, we have performed a first-in-man case study, where we have demonstrated that transendocardial CD34⁺ cell therapy in NCC is feasible and safe, and may be associated with improvements in heart failure symptoms and LVEF. Although the underlying mechanisms for these findings are not clearly defined, they may be related to new coronary microvessel formation due to proangiogenic effects of CD34⁺ cells⁹, thus leading to improved perfusion of hypertrabeculated areas of the left ventricle myocardium. Better perfusion could possibly lead to improvement of systolic function of the left ventricle and improvement of heart failure symptoms.

Declaration of Conflicting Interests

The authors declared no potential conflicts of interest with respect to the research, authorship, and/or publication of this article.

Funding

The authors received no financial support for the research, authorship, and/or publication of this article.

References

1. Towbin JA, Lorts A, Jefferies JL. Left ventricular non-compaction cardiomyopathy. *Lancet*. 2015;386(9995): 813–825.
2. Jenni R, Wyss CA, Oechslin EN, Kaufmann PA. Isolated ventricular noncompaction is associated with coronary microcirculatory dysfunction. *J Am Coll Cardiol*. 2002;39(3):450–454.
3. da Rosa LV, Cury Salemi VM, Alexandre LM, Mady C. Noncompaction cardiomyopathy – a current view. *Arq Bras Cardiol*. 2011;97(1):13–19.
4. Ponikowski P, Voors AA, Anker SD, Bueno H, Cleland JGF, Coats AJS, Falk V, González- Juanatey JR, Harjola VP, Janikowska EA, Jessup M, Linde C, Nihoyannopoulos P, Parissis JT, Pieske B, Riley JP, Rosano GMC, Ruilope LM, Ruschitzka F, Rutten FH, van der Meer P. 2016 ESC Guidelines for the diagnosis and treatment of acute and chronic heart failure. The Task Force for the Diagnosis and Treatment of Acute and Chronic Heart Failure of the European Society of Cardiology. *Eur Heart J*. 2016;37(27):2129–2200.
5. Pitta S, Thatai D, Afonso L. Thromboembolic complications of left ventricular noncompaction: case report and brief review of the literature. *J Clin Ultrasound*. 2007;35(8): 465–468.
6. Kobza R, Steffel J, Erne P, Schoenenberger AW, Hürlimann D, Lüscher TF, Jenni R, Duru F. Implantable cardioverter- defibrillator and cardiac resynchronization therapy in patients with left ventricular noncompaction. *Heart Rhythm*. 2010;7(11): 1545–1549.
7. Cerar A, Ksela J, Poglajen G, Vrtovec B, Knezevic I. LVAD as a bridge to heart transplantation in a patient with left ventricular noncompaction cardiomyopathy and advanced heart failure. *Heart Surg Forum*. 2016;19(3):128–131.
8. Vrtovec B, Poglajen G, Lezaic L, Sever M, Socan A, Domanovic D, Cernelc P, Torre-Amione G, Haddad F, Wu JC. Comparison of transendocardial and intracoronary CD34⁺ cell transplantation in patients with nonischemic dilated cardiomyopathy. *Circulation*. 2013;128(Suppl. 1): 42–49.
9. Lezaic L, Socan A, Poglajen G, Peitl PK, Sever M, Cukjati M, Cernelc P, Wu JC, Haddad F, Vrtovec B. Intracoronary transplantation of CD34⁺ cells is associated with improved myocardial perfusion in patients with nonischemic dilated cardiomyopathy. *J Card Fail*. 2015;21(2):145–152.
10. Gao XJ, Li Y, Kang LM, Zhang J, Lu MJ, Wan JY, Luo XL, He ZX, Zhao SH, Yang MF, Yang YJ. Abnormalities of myocardial perfusion and glucose metabolism in patients with isolated left ventricular non-compaction. *J Nucl Cardiol*. 2014;21(3): 633–642.