

## Concise report

# Treatment of resistant Raynaud's phenomenon with single-port thoracoscopic sympathectomy: a novel minimally invasive endoscopic technique

Anniek M. van Roon <sup>1</sup>, Michiel Kuijpers<sup>2</sup>, Saskia C. van de Zande<sup>1</sup>, Amaal Eman Abdule<sup>1</sup>, Arie M. van Roon <sup>1</sup>, Reinhard Bos<sup>3</sup>, Wobbe Bouma<sup>2</sup>, Theo J. Klinkenberg<sup>2</sup>, Hendrika Bootsma<sup>4</sup>, Mike J. L. DeJongste<sup>5</sup>, Massimo A. Mariani<sup>2</sup>, Andries J. Smit<sup>1</sup> and Douwe J. Mulder<sup>1</sup>

## Abstract

**Objective.** To assess the minimally invasive single-port thoracoscopic sympathectomy feasibility and efficacy in patients with treatment-resistant RP.

**Methods.** Single-port thoracoscopic sympathectomy was performed unilaterally on the left side in eight patients with RP (six males, two females, with a median age of 45.2 years). Five patients had primary and three had secondary RP. Perfusion effects in the hands were assessed at baseline and after 1 month by using a cooling and recovery procedure, and by using laser speckle contrast analysis. Number and duration of RP attacks were reported over a 2-week period.

**Results.** Patient satisfaction was 100% after surgery. After surgery, a unilateral improvement in perfusion was observed in the left hand compared with the right hand, with cooling and recovery ( $P = 0.008$ ) and with laser speckle contrast analysis ( $P = 0.023$ ). In addition, the number and duration of the attacks in the left hand decreased compared with the right hand (both  $P = 0.028$ ). No serious adverse events occurred in a follow-up period of at least 10 months.

**Conclusion.** Single-port thoracoscopic sympathectomy is feasible and can be effective in improving hand perfusion in patients with RP. However, long-term efficacy needs to be established.

**Clinical trial registration number.** NCT02680509.

**Key words:** Raynaud's phenomenon, sympathectomy, blood perfusion, laser speckle contrast analysis

### Rheumatology key messages

- Single-port thoracoscopic sympathectomy is a novel and true minimally invasive technique compared to conventional sympathectomy
- This procedure is feasible and effective in improving hand perfusion in patients with Raynaud's phenomenon
- This procedure is a promising treatment option for patients with Raynaud's phenomenon

## Introduction

RP is a vasospastic disorder, characterized by discolouration of the extremities provoked by cold or emotional

stress [1]. RP may have a tremendous impact on quality of life [2]. However, treatment options for RP are limited. Conventional medical treatment mainly consists of vasodilatory drugs, which are not effective in all patients and may induce undesired side effects.

In selected cases, a surgical intervention by means of sympathectomy can be considered. During this procedure, the sympathetic nerve traversing the thoracic cavity is dissected, which lowers sympathetic tonus and subsequently induces vasodilatation. Different approaches and techniques for this procedure have been studied and applied over the years, and although the surgical technique has improved over time, considerable surgical risks remain [3–5]. In our centre, a novel single-port thoracoscopic sympathectomy (SPTS) has been developed

<sup>1</sup>Department of Internal Medicine, Division of Vascular Medicine,

<sup>2</sup>Department of Cardiothoracic Surgery, University of Groningen, University Medical Center Groningen, Groningen, <sup>3</sup>Department of Rheumatology, Medical Center Leeuwarden, Leeuwarden,

<sup>4</sup>Department of Rheumatology and Clinical Immunology, University of Groningen, University Medical Center Groningen and <sup>5</sup>Department of Cardiology, Thoraxcenter, University Medical Center Groningen and University of Groningen, Groningen, The Netherlands

Submitted 1 May 2019; accepted 24 July 2019

Correspondence to: Anniek Maaik van Roon, University Medical Center Groningen, Huispostcode AA41, Hanzeplein 1, Postbus 30 001, Groningen, The Netherlands. E-mail: a.m.van.roon01@umcg.nl

in order to minimize surgical impact [6]. SPTS, initially developed for patients with hyperhidrosis, significantly limits surgical burden and further minimalizes risks when compared with conventional multiple-port sympathectomy. Furthermore, SPTS involves transection of the nerve, instead of a surgical removal of a part of the nerve itself. Therefore, SPTS might be a promising novel treatment option in patients with treatment-resistant RP.

In this study, we sought to assess the feasibility of SPTS in patients with RP resistant to all other conventional therapies. In addition, we analysed the effects of the SPTS on hand perfusion, with a cooling and recovery procedure and laser speckle contrast analysis (LASCA), and with questionnaires. Patients served as their own controls, as they received a unilateral left-sided SPTS.

## Methods

### Patients

Patients were recruited at, or especially for this study referred to, the outpatient clinic of the vascular medicine department of the University Medical Center Groningen. The study was conducted in accordance with the ethical standards of the Declaration of Helsinki. The study was approved by the local ethics committee (Groningen, The Netherlands, approval no. 2015.044), and all patients gave written informed consent. The study was registered at <https://www.clinicaltrials.gov/> (NCT02680509). RP patients were eligible when they were 18–65 years of age, and had unsatisfactory effects of prostacyclin-analogue infusion or relative contra-indications for prostacyclin treatment. Patients were excluded when they were at a higher risk of complication following unilateral lung deflation and re-insufflation (e.g. underlying pulmonary disease or a history of smoking of over 20 pack-years), signs/symptoms of peripheral artery disease, severe concomitant diseases, previous intra-thoracic pleural drainage, previous thoracic surgery, pregnancy, or unsuitable anatomy due to severe physical malformations. Patients were classified as primary RP when nailfold capillaries were normal and serology was negative. SSc was classified according to the ACR/EULAR criteria, and mixed connective tissue disease (MCTD) according to the criteria proposed by Kasuwaka *et al.* [7, 8].

### Surgical procedure

We chose to perform the procedure in every patient left-sided, and so makes the procedure independent of most affected side. For the SPTS we adopted a semi-Fowler's position, as published previously, reducing duration of surgery and improving patient safety [6]. Patients were seated at a 45° angle above the horizontal plane, to help fold the collapsed lung in a dorso-caudal direction, which creates a complete view of the surgical field.

General anaesthesia was administered and patients were intubated with a single lumen endotracheal tube. The procedure was performed during apnoea. Following local infiltration with bupivacaine, a 7 mm incision was made in the left anterior axillary line. After deflation of

the lung, a 5 mm trocar was inserted through the third intercostal space, just posterior to the major pectoral muscle. A 5 mm scope (Karl Storz, Tuttlingen, Germany) and cautery hook were then introduced. The first and second rib were identified, as well as the sympathetic chain running along the 'neck' of the ribs. The part of the sympathetic chain overlying the rib was transected with diathermy at high costal level, sparing the sympathetic ganglia and thus performing an R3-sympathectomy (Fig. 1A–C).

The transection was extended 2 cm laterally over the rib to transect any accessory nerve fibres. The surgical procedure was completed by insertion of an 8 mm French thoracic drain through the same access port, re-insufflation and recruitment of the collapsed lung under direct vision and removal of the drain under positive end expiratory pressure. A thoroughly placed subcutaneous string suture ensured airtight incision sealing. The skin was sutured intracutaneously.

### Vascular measurements

All vascular measurements were performed 1 or 2 days prior to the surgery (baseline) and 1 month after, in a temperature-controlled room by one vascular technician.

The cooling and recovery procedure was performed on both hands, as described previously [9]. In short, photoelectric plethysmography sensors were placed on all fingertips to assess blood flow. Both hands were submerged in water up till the radio carpal joint. Every 4 min, the water was cooled by 3°C, from 33°C to 6°C, or until the patient could not tolerate the pain any more. After cooling, the blood flow was assessed every minute during a 10-min recovery period.

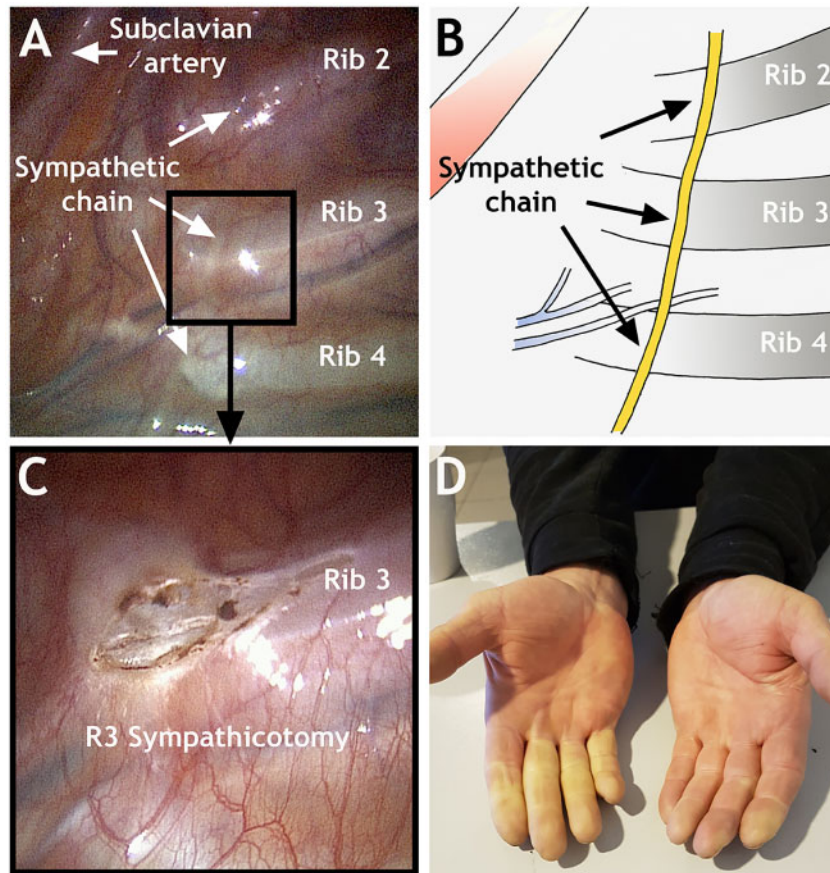
LASCA was performed to measure peripheral blood perfusion, at room temperature (23°C), on both hands using a PeriCam PSI System (PeriMed, Jarfalla, Sweden), and data acquisition and analysis were performed making use of PIMSoft (PeriMed). Perfusion was processed as numerical values in perfusion units and colour-coded images. A total of 1 min was recorded per hand, of which a stable period of 10 s was assessed. Two regions of interest were selected: ROI1 entailed the index, middle and ring finger distal from the DIP joint, and ROI2 the dorsum of the hand. The perfusion gradient was calculated by subtracting ROI2 from ROI1, as described previously [10].

### Patient-reported outcomes

The number and duration of RP attacks were assessed for each hand separately in a Raynaud diary over a period of 14 days, in the 2 weeks immediately prior to the surgery and 2 weeks prior to the visit 1 month post-operatively [11].

### Statistical methods

Statistical analysis was performed using SPSS version 23 (released 2013; IBM Corp., Armonk, NY, USA). Differences in questionnaire scores before and after surgery were compared with a Wilcoxon signed-rank test.

**Fig. 1** Single-port thoracoscopic sympathectomy of the third rib

**(A, B)** Intra-operative view of the sympathetic chain running down the dorsal thoracic wall, lateral of the costo-vertebral junction. In the left upper corner, the subclavian artery can be seen. **(C)** Detail of the third rib after R3 sympathectomy. **(D)** Left and right difference of the hands of a patient during a Raynaud's attack, 1 month after left-sided R3 sympathectomy.

Differences in vascular measurements, and RP attack frequency and duration, between baseline and 1 month post-operatively of each separate hand were calculated and are referred to as delta. Differences between the deltas of left and right were tested with the Wilcoxon signed rank test. Data are shown as median (IQR) or number (%). *P*-values <0.05 were considered statistically significant.

## Results

### Patients

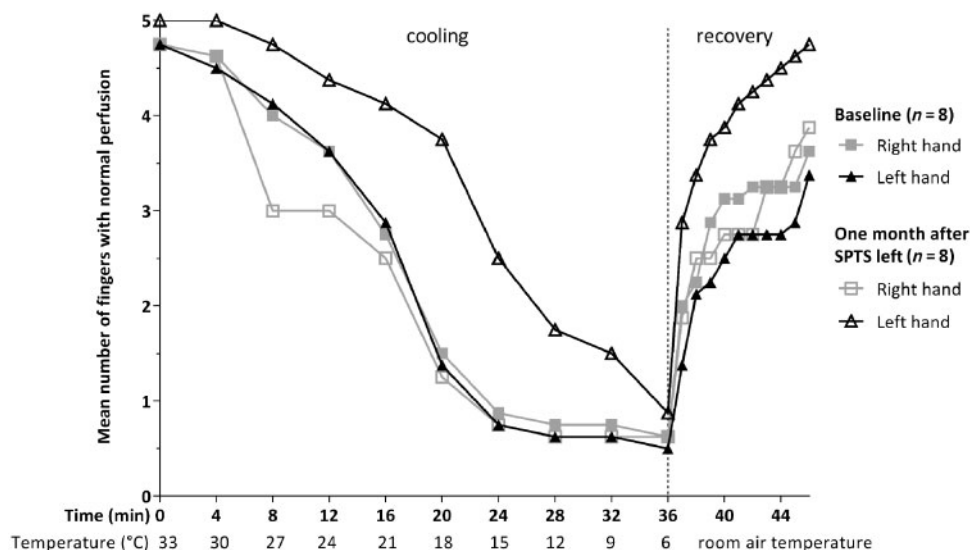
Eight patients were included in the study, six males and two females, with a median (IQR) age of 45.2 (30.2–55.3) years, body mass index of 23.9 (23.4–26.8) kg/m<sup>2</sup> and RP duration of 7.0 (2.5–14.3) years. Five patients suffered from primary RP, and three patients had RP secondary to CTD [MCTD (*n*=2) and limited cutaneous SSc (*n*=1)]. Of these patients, all had unsatisfactory effects of calcium channel blockers, and three experienced side effects as well. Seven patients had unsatisfactory effects and/or

severe side effects of iloprost or prostacyclin infusions. One patient reported an unsatisfactory effect of alpha-blockers. For all patients the right hand was dominant. Only the patient with SSc had a history of digital ulceration, with an (almost healed) ulcer at baseline visit, which was healed 1 month post-operatively. None of the patients had (a history of) critical ischaemia. Patients' complaints were symmetrical, which was confirmed by comparable left and right baseline values of the vascular measurements and duration and number of attacks (Supplementary Table S1, available at *Rheumatology* online).

### Surgery, safety and adverse events

The mean intubation time was ~21 min, during which the mean time of the procedure itself was about 8 min. No complications occurred during surgery. After surgery no serious adverse events occurred. The day following the procedure, all patients were discharged from hospital. After discharge, one patient experienced a subjective

Fig. 2 Cooling and recovery procedure



Mean number of fingers per hand with normal perfusion during the cooling and recovery procedure pre-operatively (baseline) and 1 month post-operatively after left-sided single-port thoracoscopic sympathectomy (SPTS).

swelling of the left hand (hyperaemia), which resolved spontaneously within 1 week. One patient reported a dry skin patch at the fingertips of the left hand 3 months after surgery (during the winter season), which also resolved spontaneously, within 5 months. Two patients reported a mild increase in sweating in the months following surgery [dorsal side of the trunk region ( $n=2$ ), chest ( $n=1$ ) and axillary ( $n=1$ )].

#### Vascular measurements

Figure 2 shows the mean number of fingers of one hand, with perfusion during the cooling and recovery procedure. The mean ischaemic time of five fingers decreased in the left hand compared with the right hand [left delta  $-10.4$  ( $-19.9$  to  $-3.85$ ) min vs right  $-0.10$  ( $-4.0$  to  $9.4$ ) min,  $P = 0.012$ ; Supplementary Table S1, available at *Rheumatology* online]. The mean temperature at which five fingers lost perfusion decreased in the left hand compared with the right hand [left delta  $-7.7^{\circ}\text{C}$  ( $-9.0$  to  $-1.8^{\circ}\text{C}$ ) vs right  $0.7^{\circ}\text{C}$  ( $-1.9$  to  $6.5^{\circ}\text{C}$ ),  $P = 0.018$ ; Supplementary Table S1, available at *Rheumatology* online]. LASCA showed that the perfusion gradient increased in the left hand compared with the right hand [left delta  $14.0$  ( $0.9$  to  $23.7$ ) vs right  $-15.5$  ( $-30.9$  to  $11.9$ ),  $P = 0.025$ ; Supplementary Table S1, available at *Rheumatology* online].

#### Patient-reported outcomes

Patient satisfaction was 100% after surgery. Figure 1D shows how remarkable the results of surgery can be 1 month after SPTS of the left hand. The total number and duration of attacks of the left hand over a period of 14 days was reduced compared with the right hand [number of attacks: delta left  $-11$  ( $-23$  to  $-5$ ) vs right

$-3$  ( $-7$  to  $6$ ),  $P = 0.028$ ; duration: delta left  $-3.0$  ( $-18$  to  $-1.4$ ) h vs right  $-0.9$  ( $-5.0$  to  $-0.1$ ) h,  $P = 0.028$ ; Supplementary Table S1, available at *Rheumatology* online]. Six patients did not experience any attacks in the left hand after surgery, and in the two patients who did, both frequency and duration of attacks were reduced compared with attacks in the right hand.

#### Discussion

In this study we have shown that the described novel SPTS procedure is feasible and effective in improving hand perfusion in patients with treatment-resistant RP, although the outcomes are first observations at an early stage, and longer follow-up in larger patient cohorts is needed. The most striking result of the present study was the significant improvement of left hand perfusion in all patients, during a cooling and recovery procedure, 1 month after SPTS. In addition, perfusion of the left fingertips at room temperature also increased, as assessed with LASCA. Finally, patients were very satisfied with the result and reported fewer and shorter RP attacks of the left hand.

Current treatment options (i.e. intravenous prostacycline) are expensive, very time-consuming, and can be a great burden for patients. Therefore, SPTS, with very limited side effects, is an attractive and promising treatment option. With regards to conventional surgical intervention, Coveliers *et al.* found that 89% of the primary and secondary RP patients had beneficial short-term effects following conventional sympathectomy [12]. Moreover, 59% of the primary RP patients and 89% of the secondary RP patients reported beneficial long-term effects ( $>18$  months). Given the minimal invasive character of



our SPTS, and comparable short-term results to those reported by Coveliers *et al.* [14], our method may offer a favourable and safe therapeutic alternative to sympathectomy.

The main limitation of this study is the short follow-up and relatively small sample size. Despite this limitation, we were able to demonstrate clear differences between the intervention side and control side. As there is no standardized validated method to assess perfusion in RP, we used the cooling and recovery procedure and LASCA, which were performed by the same technician using the same protocol before and after surgery. This ensured that changes over time would not be influenced by interobserver and technical differences. Perfusion measurements, especially of extremities, are always limited by environmental influences such as the weather and room temperature (although performed in a temperature-controlled room). However, because we compared left with right, the influence of this was kept to a minimal.

In the current study no patients with advanced CTDs participated. However, patients with advanced disease may experience severe RP symptoms with even critical digital ischaemia. The results of Coveliers *et al.* suggest that these patients can benefit most from this procedure, as sympathectomy maximizes tissue preservation [14]. Furthermore, the characteristics (i.e. age, disease duration and gender) of the primary RP patients were not typical for the disease. This is due to the fact that we included patients with severe complaints, and this might influence the generalizability of our results to the typical patient with primary RP. However, at this stage the SPTS is not recommended for typical primary RP patients, and the procedure is for now an option for patients whose complaints limit daily activity and are resistant to conventional treatment. Therefore, future studies should also include patients with more extensive CTDs as well as less severe primary RP.

In conclusion, 1 month after unilateral SPTS, the number of RP attacks was reduced and perfusion of the treated hand increased. Given the reported beneficial effects as well as the limited adverse events, SPTS appears to be a promising treatment option for patients who do not respond well to conventional vasodilatory drug treatment. Follow-up studies are on-going to investigate the long-term effects of SPTS and to optimize treatment strategies for different subgroups of RP patients.

**Funding:** No specific funding was received from any funding bodies in the public, commercial or not-for-profit sectors to carry out the work described in this manuscript.

**Disclosure statement:** The authors have declared no conflicts of interest.

## Supplementary data

Supplementary data are available at *Rheumatology* online.

## References

- Herrick AL. The pathogenesis, diagnosis and treatment of Raynaud phenomenon. *Nat Rev Rheumatol* 2012;8:469–79.
- De Angelis R, Salaffi F, Grassi W. Health-related quality of life in primary Raynaud phenomenon. *J Clin Rheumatol* 2008;14:206–10.
- Murphy MO, Ghosh J, Khwaja N *et al.* Upper dorsal endoscopic thoracic sympathectomy: a comparison of one- and two-port ablation techniques. *Eur J Cardiothorac Surg* 2006;30:223–7.
- Matsumoto Y, Ueyama T, Endo M *et al.* Endoscopic thoracic sympathectomy for Raynaud's phenomenon. *J Vasc Surg* 2002;36:57–61.
- Sayers RD, Jenner RE, Barrie WW. Transthoracic endoscopic sympathectomy for hyperhidrosis and Raynaud's phenomenon. *Eur J Vasc Surg* 1994;8:627–31.
- Kuijpers M, Klinkenberg TJ, Bouma W, DeJongste MJ, Mariani MA. Single-port one-stage bilateral thoracoscopic sympathectomy for severe hyperhidrosis: prospective analysis of a standardized approach. *J Cardiothorac Surg* 2013;8:216.
- van den Hoogen F, Khanna D, Fransen J *et al.* 2013 classification criteria for systemic sclerosis: an American College of Rheumatology/European League against Rheumatism collaborative initiative. *Arthritis Rheum* 2013;65:2737–47.
- Kasuwaka R, Tojo T, Miyawaki S. Preliminary diagnostic criteria for classification of mixed connective tissue disease. In: Kasukawa R, Sharp GC, eds. *Mixed connective tissue disease and antinuclear antibodies*. Amsterdam: Elsevier, 1987: 41–7.
- van Roon AM, Smit AJ, van Roon AM, Bootsma H, Mulder DJ. Digital ischaemia during cooling is independently related to nailfold capillaroscopic pattern in patients with Raynaud's phenomenon. *Rheumatology (Oxford)* 2016;55:1083–90.
- Meijs J, Voskuyl AE, Bloemsaat-Minekus JP, Vonk MC. Blood flow in the hands of a predefined homogeneous systemic sclerosis population: the presence of digital ulcers and the improvement with bosentan. *Rheumatology (Oxford)* 2015;54:262–9.
- Merkel PA, Herlyn K, Martin RW *et al.* Measuring disease activity and functional status in patients with scleroderma and Raynaud's phenomenon. *Arthritis Rheum* 2002;46:2410–20.
- Coveliers HM, Hoexum F, Nederhoed JH, Wisselink W, Rauwerda JA. Thoracic sympathectomy for digital ischaemia: a summary of evidence. *J Vasc Surg* 2011;54:273–7.