

Infant with stridor due to vallecular cyst - Anaesthetic management

Sir,

A congenital vallecular cyst is a rare mucous retention cyst arising from the epiglottis or the base of the tongue^[1,2] with an incidence of 5.3 cases/10,000 live births.^[3] It causes dynamic airway obstruction leading to stridor precipitated by feeding, crying, and induction of anaesthesia.^[4] Different techniques have been described in the literature for securing the airway in patients with a vallecular cyst.^[5] We hereby present the management of a 3-month-old child with a vallecular cyst for surgical cyst excision.

A 2.8 kg male baby, presented with noisy breathing, feeding difficulty, and failure to gain weight. The child had respiratory distress with chest retractions and peripheral oxygen saturation (SpO₂) of 98% on room air. He was diagnosed with vallecular cysts by neck X-ray of the soft tissue [anteroposterior and lateral view Figure 1] and confirmed by flexible nasopharyngolaryngoscopy which is the gold standard test for diagnosis. The laboratory blood investigations were normal.

The child was optimised before surgery for gross malnutrition by starting on nasogastric feeds for 2 weeks (the child gained 100 g/week), and nebulisation was started. Informed written consent was obtained

from the parents and they were explained about the difficulty in securing the airway and the possibility of emergency tracheostomy and post-operative ventilation.

The child fasted for 4 h. Before shifting the child to the operation theatre, a difficult airway cart, emergency tracheostomy team, and emergency drugs were kept ready.

Two drops of 1% lignocaine were instilled intranasally, and 1 mL of 1% lignocaine was squirted over the tongue. The child was connected to standard American Society of Anesthesiologists (ASA) monitors. He was induced smoothly with 100% oxygen and step-up sevoflurane induction, and intravenous cannula 24 G was secured. Once respiration was adequate, intravenous (i.v) fentanyl 3 µg was given. An indigenous nasopharyngeal airway was secured through one nostril, subsequently anaesthesia was maintained through this route.

Plan A was nasal fiberoptic bronchoscopic-guided intubation.^[6] The glottis was partially occluded during respiration due to the rapid movement of the cyst during respiration; therefore, manoeuvring the scope through the glottis was difficult.

Plan B was intubation with a video laryngoscope (C-MAC) with a paediatric blade. This also failed to identify the glottic opening because of the heavy nature of the blade and the mass obscuring the glottic view [Figure 2].

A final attempt using conventional Miller blade size 1 by paraglossal approach was attempted. We could

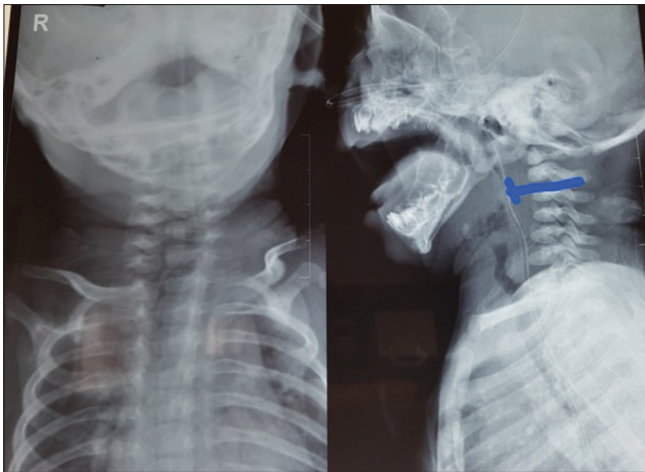


Figure 1: X-ray of neck AP and lateral view showing obscuring of air shadow

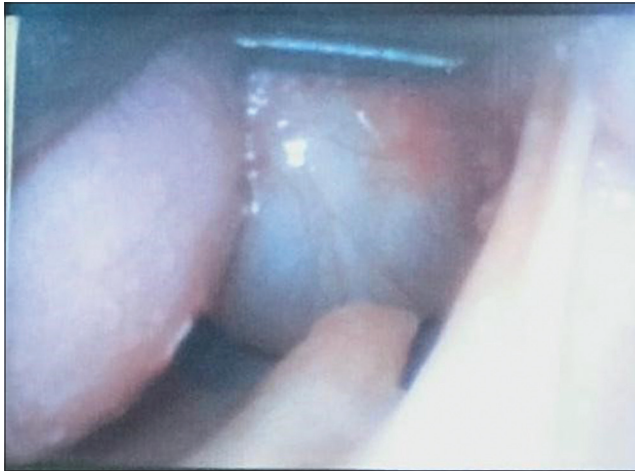

Figure 2: Videolaryngoscopic view showing the large cyst

not visualise the epiglottis because of the mass, but we could visualise a small area presumed to be the glottic opening through which bubbles were coming during the respiratory efforts of the child. We successfully intubated through this area, and a size 3.0-mm ID, uncuffed polyvinyl chloride (PVC) endotracheal tube was fixed to the left side of the angle of the mouth. Throughout this procedure, the patient was anaesthetised with oxygen and sevoflurane through the nasal airway on spontaneous ventilation. After confirming the tube position, inj. atracurium 0.5 mg i.v and inj. dexamethasone 1 mg i.v were given to prevent airway oedema. The anaesthesia was then maintained using oxygen, nitrous oxide mixture (50:50), and sevoflurane with controlled ventilation. The surgery was completed without any complications, and the cyst was removed in toto. The nasogastric (NG) tube was reintroduced for feeding. The child was electively ventilated for 48 h in anticipation of laryngomalacia,

fresh wound and airway oedema postoperatively and extubated successfully after 48 h. Immediate follow-up showed a baby with a normal cry, no respiratory distress, or feeding difficulty. The child was discharged home after 2 weeks and advised for follow-up after 1 month.

The anaesthetic concerns are difficult airway due to distorted anatomy, difficulty in maintaining the depth of anaesthesia, risk of rupture of cysts during intubation leading to aspiration and hypoxia and postoperative laryngomalacia.

To conclude, there is no single airway approach that solves every difficult airway. Every difficult airway should be approached individually and management depends on preparedness and awareness among anaesthetists. In our case, we devised our anaesthetic plan carefully before opting for tracheostomy.

Declaration of patient consent

The authors certify that they have obtained all appropriate patient consent forms. In the form, the patients' parents have given their consent for the patients' images and other clinical information to be reported in the journal. The patient's parents understand that the patients' names and initials will not be published and due efforts will be made to conceal their identity, but anonymity cannot be guaranteed.

Acknowledgement

We would like to thank Dr.Mary kurien, Professor and Head, Department of ENT and Dr.Rajeshwari, Associate Professor, Department of ENT, PIMS, Pondicherry.

Financial support and sponsorship

Nil.

Conflicts of interest

There are no conflicts of interest.

**Mohankumar Archana, Sivakumar Segaran,
Mamie Zachariah, Sagiev Koshy George**

Department of Anaesthesia, Pondicherry Institute of Medical Sciences, Pondicherry, India

Address for correspondence:

Dr. Mohankumar Archana,
Department of Anaesthesia, Pondicherry Institute of Medical Sciences, Pondicherry, India.
E-mail: archm.07@gmail.com

Submitted: 10-Dec-2020

Revised: 14-Jan-2021

Accepted: 11-Feb-2021

Published: 15-Apr-2021

REFERENCES

1. Prowse S, Knight L. Congenital cysts of the infant larynx. *Int J Pediatr Otorhinolaryngol* 2012;76:708-11.
2. Chen EY, Lim J, Boss EF, Inglis Jr AF, Ou H, Sie KC, *et al.* Transoral approach for direct and complete excision of vallecular cysts in children. *Int J Pediatr Otorhinolaryngol* 2011;75:1147-51.
3. Tsai YT, Lee LA, Fang TJ, Li HY. Treatment of vallecular cysts in infants with and without coexisting laryngomalacia using endoscopic laser marsupialization: Fifteen-year experience at a single-center. *Int J Pediatr Otorhinolaryngol* 2013;77:424-8.
4. Mahajan V, Mathew JL, Singh M, Gupta R, Das A. Vallecular cyst-revisited. *Indian J Pediatr* 2008;75:1081-2.
5. Walshe CM, Jonas N, Rohan D. Vallecular cyst causing a difficult intubation. *Br J Anaesth* 2009;102:565.
6. Kumar A, Bhadani UK, Bharti B, Kumar N. Airway management of a near obstructive vallecular cyst in an infant. *Indian J Anaesth* 2020;64:721-2.

This is an open access journal, and articles are distributed under the terms of the Creative Commons Attribution-NonCommercial-ShareAlike 4.0 License, which allows others to remix, tweak, and build upon the work non-commercially, as long as appropriate credit is given and the new creations are licensed under the identical terms.

Access this article online	
Quick response code	Website: www.ijaweb.org
	DOI: 10.4103/ija.IJA_1394_20

How to cite this article: Archana M, Segaran S, Zachariah M, George SK. Infant with stridor due to vallecular cyst- Anaesthetic management. *Indian J Anaesth* 2021;65:340-2.

© 2021 Indian Journal of Anaesthesia | Published by Wolters Kluwer - Medknow