

Recurrent hemarthrosis of the knee following total knee arthroplasty treated with geniculate artery embolization

Moses Azubuiké, BS; Poyan Afiei, MD; and Ryan Mikus, MD

Hemarthrosis after total knee arthroplasty (TKA) is an uncommon condition. Ohdera et al. (1) reported a frequency of 1.6%, while others have reported a much lower frequency of 0.3 - 1% (2-4). We present a unique case of recurrent hemarthrosis in a 93-year-old female two years after an uneventful total knee arthroplasty and describe how we successfully treated it with selective angiographic embolization of the geniculate arteries.

Case report

A 93-year-old female underwent an uneventful left TKA in 2011. There was no reported complication following the procedure, and the patient successfully underwent physical rehabilitation and was back to baseline. The patient had a past medical history of longstanding thrombocytosis and transient ischemic attack (TIA), for which she was treated with Plavix 75mg daily. In December 2013, two years after the TKA, she presented with left-knee hemarthrosis following a mechanical fall. The effusion was initially treated with arthrocentesis and conservative management.

Afterward, the patient had four more recurrent episodes of severe left-knee pain and hemarthrosis. She presented in April 2014 for excruciating left-knee pain that failed to resolve with conservative treatment. Arthrocentesis was performed, and 40 milliliters of bloody fluid was aspirated. Cultures on samples were negative for an infectious process. A nuclear medicine bone scan showed no evidence

of gallium uptake to suggest infection or hardware loosening. Serum hematologic and biochemical profiles revealed an elevated platelet count at 896 X 10³/uL (normal range, 166 -358 X 10³/uL) and low mean corpuscular volume (MCV) at 57 FL (normal, 80.6 -95.5 FL). Hemoglobin electrophoresis showed a hemoglobin A₂ of 4.8% (normal, 1.3 -3.3%). These findings (in addition to smear results) were consistent with beta thalassemia trait. All other pertinent lab values were within normal limits. Coagulation studies were also within normal limits. Hydroxyurea 500 mg daily was initiated to decrease thrombocytosis, as correlation with recurrent hemarthrosis was uncertain at the time. The patient's platelet count decreased to normal levels at 321 X 10³/uL in June 2014 (almost three years after the TKA); however, she continued to complain of recurrent left-knee pain and swelling.

CT angiography of the left lower extremity was subsequently performed and showed a moderate left suprapatellar joint effusion. There was no significant atherosclerosis. Three-vessel runoff was present in the left leg.

The decision was then made to proceed with diagnostic arteriography of the left lower extremity, with possible geniculate artery embolization. Using ultrasound guidance, left common femoral artery access was obtained with a micropuncture needle, followed by subsequent placement of a 6 French vascular sheath. A 5 French Berenstein catheter (AngioDynamics, Latham, NY) and 0.035" Bentson guidewire (Cook Medical, Bloomington, IN) were used for catheterization of the left popliteal artery. Diagnostic arteriography showed synovial hypervascularity of the left lateral knee (Fig. 1).

Citation: Azubuiké M, Afiei P, Mikus R. Recurrent hemarthrosis of the knee following total knee arthroplasty treated with geniculate artery embolization. *Radiology Case Reports*. (Online) 2015;10(2);1105

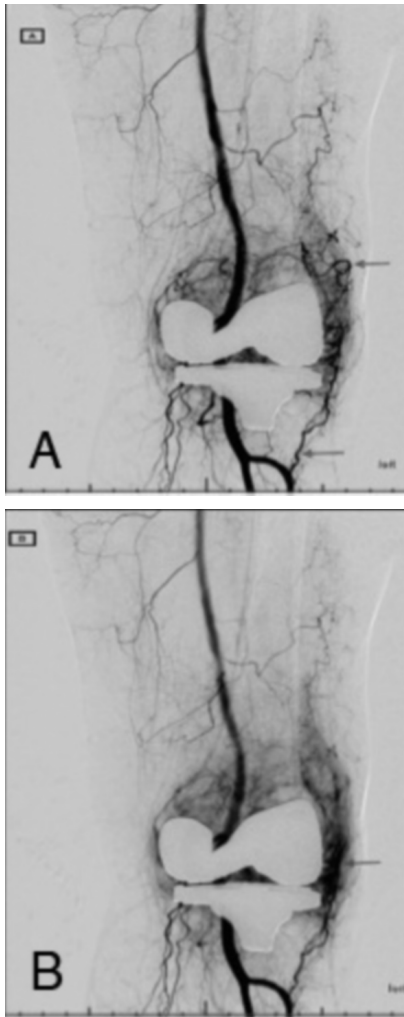
Copyright: © 2015 The Authors. This is an open-access article distributed under the terms of the Creative Commons Attribution-NonCommercial-NoDerivs 2.5 License, which permits reproduction and distribution, provided the original work is properly cited. Commercial use and derivative works are not permitted.

Mr. Azubuiké is a third-year medical student, Dr. Afiei is the Chief of Interventional Radiology, and Dr. Mikus is an Interventional Radiology Fellow, all in the Department of Radiology, University of Texas Medical branch, Galveston TX. Contact Mr. Azubuiké at mazubuik@utmb.edu.

Competing Interests: The authors have declared that no competing interests exist.

DOI: 10.2484/rcr.v10i2.1105

Recurrent hemarthrosis of the knee treated with embolization



Since there was significant vascularity of the left lateral synovium, the decision was made to proceed with geniculate artery embolization. Selective catheterization of the left superior lateral and inferior lateral geniculate arteries was achieved with a 2.5 French Rengade microcatheter (Boston Scientific, Marlborough, MA) and .014" Transend microwire (Boston Scientific, Marlborough, MA). Embolization was performed using 300-500- μ m-sized Embosphere Microspheres (Biosphere Medical Systems Inc., South Jordan, UT) (Figs. 2 and 3). Postembolization

Fig. 1. A) Digital subtraction angiography (DSA) of the left popliteal artery shows significant vascularity of the left lateral knee via the left superior lateral geniculate and left inferior lateral geniculate arteries (upper and lower arrows, respectively). (B) Arterial delayed-phase image shows significant staining of the left lateral synovium.

arteriography showed significant decrease in the vascular supply to the left lateral knee, with no significant synovial staining (Fig. 4).

After completion of the embolization, all catheters were removed. An angioseal device was deployed for successful closure of the left common femoral arteriotomy. The patient tolerated the procedure well, with no immediate post-procedural complication. She was discharged home after 2 hours of observation.

The patient was seen one month after the procedure for clinical followup. She reported significant improvement of her symptoms, with only mild left-knee pain and no recurrent episode of large left-knee swelling. She also stated that there was significant improvement in her mobility and quality of life. On physical exam, her left knee was non-

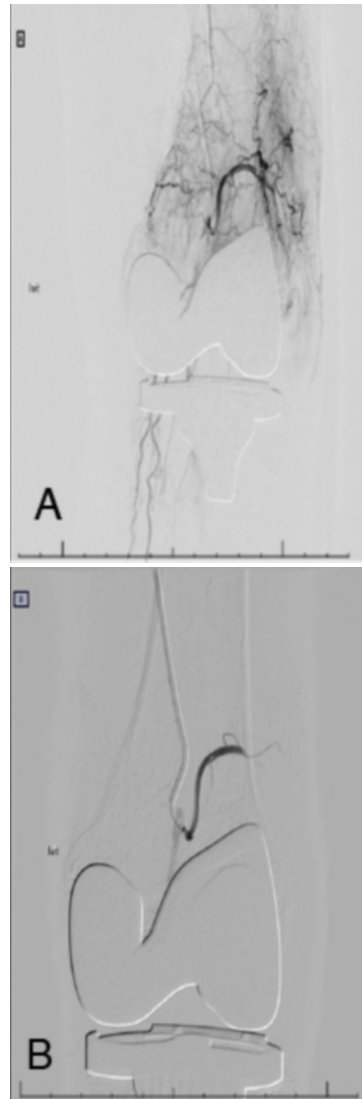


Fig. 2. (A) DSA of the left superior lateral geniculate artery before embolization. (B) Postembolization angiography shows devascularization of the synovium.

giosarcoma of bone (13), metal particle in synovial fluid (14), and arteriovenous fistula (15). Our case is another report attributing recurrent hemarthrosis following TKA to hypervascularity of the geniculate arteries. The potential contribution of longstanding thrombocytosis and beta thalassemia trait in this case is unclear.

First-line treatment for hemarthrosis is conservative treatment with arthrocentesis, rest, ice, and elevation (4). Arthroscopic synovectomy has been recommended when conservative measures fail (3-4). However, recurrent hemarthrosis after arthroscopic synovectomy has been reported (6).

Contrast-enhanced magnetic resonance imaging (MRI) or computed tomography (CT) is of value to identify possible causes for hemarthrosis, including neoplasms and iatro-

tender to palpation, with appropriate flexion, extension, and bilateral internal rotation. No skin sloughing was identified.

Discussion

Spontaneous hemarthrosis of the joint is rather common and seen frequently in people with history of a bleeding disorder like hemophilia (5); however, recurrent spontaneous hemarthrosis of the knee following TKA is uncommon (1-4). Interestingly, reported etiologies of late recurrent hemarthrosis in patients without an underlying bleeding disorder are very diverse: pseudoaneurysm (6-7), prolonged anticoagulant therapy (8), hypertrophy of geniculate arteries (9-10 and 16-17), intra-articular fasciitis (11), meniscal ganglion cyst (12), epithelioid an-

Recurrent hemarthrosis of the knee treated with embolization

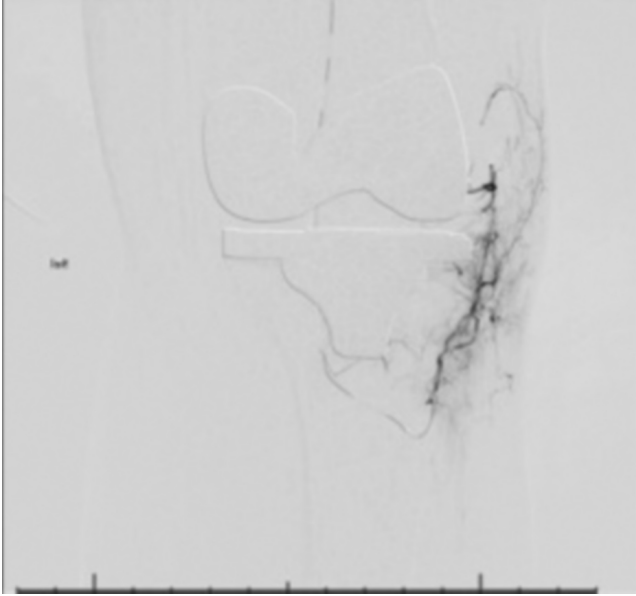


Fig. 3. DSA of the left inferior lateral geniculate artery before embolization.

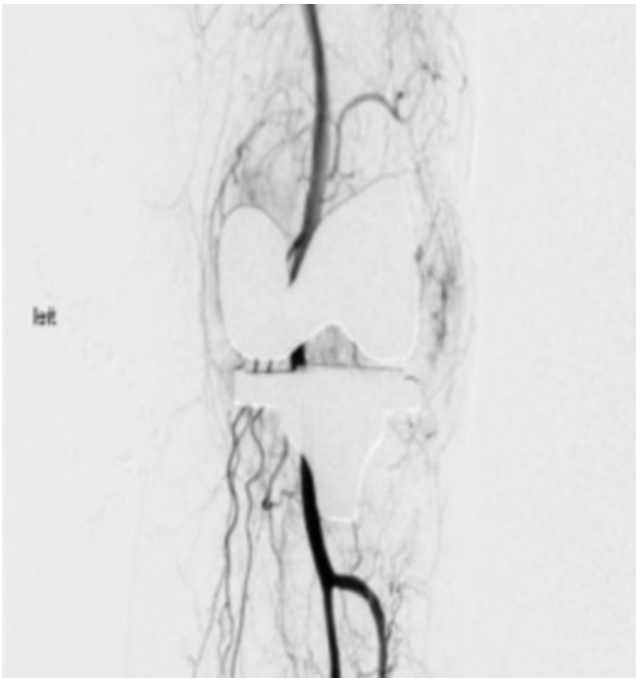

Fig. 4. Final DSA of the left popliteal artery shows dramatic reduction in left lateral synovial vascularity, with significantly decreased flow in the left superior lateral geniculate artery. The left inferior lateral geniculate artery is no longer visualized.

genic vascular injury. Synovial thickening and/or synovial hypervascularity may also be seen with such examinations, although artifacts from the knee prosthesis can limit these

observations. Our case did not show any findings to account for knee hemarthrosis on the pre-operative CT exam.

To our knowledge, the use of transcatheter arterial embolization to successfully treat recurrent hemarthrosis due to geniculate artery hypervascularity is rare and has been reported in four papers (8-10, 16-17). Diagnostic angiography should be performed before embolization to identify areas of hypervascular synovium. Bagla et al. (16) reported a complication of skin sloughing in two patients who had undergone embolization with spherical particles smaller than 300 μm . This was not observed in our patient, who was treated with embolic particles ranging from 300 to 500 μm .

Although long-term followup results are not yet available for our patient, the short-term clinical success we achieved is promising. In conclusion, transcatheter embolization is a safe treatment option for recurrent hemarthrosis for patients who have failed conservative therapy and demonstrate synovial hypervascularity on angiography.

References

1. Ohdera T, Tokunaga M, Hiroshima S, Yoshimoto E, Matsuda S. Recurrent hemarthrosis after knee joint arthroplasty: etiology and treatment. *J Arthroplasty*. 2004;19(2):157-61. [[PubMed](#)]
2. Oishi CS, Elliott ML, Colwell CW. Recurrent hemarthrosis following a total knee arthroplasty. *J Arthroplasty*. 1995;10 Suppl:S56-8. [[PubMed](#)]
3. Worland RL, Jessup DE. Recurrent hemarthrosis after total knee arthroplasty. *J Arthroplasty*. 1996;11(8):977-8. [[PubMed](#)]
4. Kindsfater K, Scott R. Recurrent hemarthrosis after total knee arthroplasty. *J Arthroplasty*. 1995;10 Suppl:S52-5. [[PubMed](#)]
5. Park JJ, Slover JD, Stuchin SA. Recurrent hemarthrosis in a hemophilic patient after revision total knee arthroplasty. *Orthopedics*. 2010;33(10):771. [[PubMed](#)]
6. Becher C, Burger UL, Allenberg JR, Kaufmann GW, Thermann H. Delayed diagnosis of a pseudoaneurysm with recurrent hemarthrosis of the knee joint. *Knee Surg Sports Traumatol Arthrosc*. 2008;16(6):561-4. [[PubMed](#)]
7. Mertens JB, Daenen GJ, Mertens AI. Recurrent hemarthrosis of the knee caused by pseudoaneurysm of a composed femoropopliteal bypass graft. *Ann Vasc Surg*. 2004;18(5):608-11. [[PubMed](#)]
8. Katsimihis M, Robinson D, Thornton M, Langkamer VG. Therapeutic embolization of the genicular arteries for recurrent hemarthrosis after total knee arthroplasty. *J Arthroplasty*. 2001;16(7):935-7. [[PubMed](#)]
9. Pritsch T, Pritsch M, Halperin N. Therapeutic embolization for late hemarthrosis after total knee arthroplasty. A case report. *J Bone Joint Surg Am*. 2003;85-A(9):1802-4. [[PubMed](#)]
10. Pham TT, Bouloudian S, Moreau PE, et al. Recurrent hemarthrosis following total knee arthroplasty. Report

Recurrent hemarthrosis of the knee treated with embolization

- of a case treated with arterial embolization. *Joint Bone Spine*. 2003;70(1):58-60. [[PubMed](#)]
11. Matsuzaki T, Akisue T, Kishimoto K, et al. Intra-articular nodular fasciitis of the knee: a rare cause of recurrent hemarthrosis. *Rheumatol Int*. 2012;32(6):1691-4. [[PubMed](#)]
 12. Ogawa H, Itokazu M, Ito Y, Fukuta M, Simizu K. An unusual meniscal ganglion cyst that triggered recurrent hemarthrosis of the knee. *Arthroscopy*. 2006;22(4):455.e1-4. [[PubMed](#)]
 13. Drexler M, Dolkart O, Amar E, Pritsch T, Dekel S. Late recurrent hemarthrosis following knee arthroplasty associated with epithelioid angiosarcoma of bone. *Knee*. 2010;17(5):365-7. [[PubMed](#)]
 14. Kitridou RC, Schumacher HR, Sbarbaro JL, Hollander JL. Recurrent hemarthrosis after prosthetic knee arthroplasty: identification of metal particles in the synovial fluid. *Arthritis Rheum*. 1969;12(5):520-8. [[PubMed](#)]
 15. Kalsi PS, Carrington RJ, Skinner JS. Therapeutic embolization for the treatment of recurrent hemarthrosis after total knee arthroplasty due to an arteriovenous fistula. *J Arthroplasty*. 2007;22(8):1223-5. [[PubMed](#)]
 16. Bagla S, Rholl KS, Van breda A, Sterling KM, Van breda A. Geniculate artery embolization in the management of spontaneous recurrent hemarthrosis of the knee: case series. *J Vasc Interv Radiol*. 2013;24(3):439-42. [[PubMed](#)]
 17. Yamagami T, Yoshimatsu R, Miura H, Arai Y, et al. Selective arterial embolization with gelatin particles for refractory knee hemarthrosis. *Diagn Interv Radiol*. 2013;19:423-26. [[PubMed](#)]