

Received: 2011.08.11
Accepted: 2011.08.25
Published: 2012.05.01

A review of subclavian steal syndrome with clinical correlation

Stephen Osiro¹, Anna Zurada², Jerzy Gielecki², Mohammadali M. Shoja³,
R. Shane Tubbs⁴, Marios Loukas^{1,2}

¹ Department of Anatomical Sciences, School of Medicine, St. George's University, Grenada, West Indies

² Department of Anatomy, Medical School Varmia and Mazuria, Olsztyn, Poland

³ Division of Neurosurgery, University of Alabama, Birmingham, AL. U.S.A.

⁴ Pediatric Neurosurgery, Children's Hospital, Birmingham, AL. U.S.A.

Source of support: Self financing

RA

Summary

Subclavian 'steal' phenomenon is a function of the proximal subclavian artery (SA) steno-occlusive disease, with subsequent retrograde blood flow in the ipsilateral vertebral artery (VA). The symptoms from the compromised vertebrobasilar and brachial blood flows constitute the subclavian steal syndrome (SSS), and include paroxysmal vertigo, drop attacks and/or arm claudication. Once thought to be rare, the emergence of new imaging techniques has drastically improved its diagnosis and prevalence. The syndrome, however, remains characteristically asymptomatic and solely poses no serious danger to the brain. Recent studies have shown a linear correlation between increasing arm blood pressure difference with the occurrence of symptoms. Atherosclerosis of the SA remains the most common cause. Doppler ultrasound is a useful screening tool, but the diagnosis must be confirmed by CT or MR angiography. Conservative treatment is the initial best therapy for this syndrome, with surgery reserved for refractory symptomatic cases. Percutaneous angioplasty and stenting, rather than bypass grafts of the subclavian artery, is the widely favored surgical approach. Nevertheless, large, prospective, randomized, controlled trials are needed to compare the long-term patency rates between the endovascular and open surgical techniques.

key words: subclavian steal syndrome • subclavian artery stenosis • retrograde blood flow

Full-text PDF: <http://www.medscimonit.com/fulltxt.php?ICID=882721>

Word count: 2985

Tables: –

Figures: 5

References: 52

Author's address: Marios Loukas, Department of Anatomical Sciences, St. George's University, School of Medicine, Grenada, West Indies, e-mail: mloukas@sgu.edu

HISTORICAL BACKGROUND

Subclavian steal phenomenon occurs when a subclavian artery stenosis proximal to the vertebral origin causes retrograde flow in the ipsilateral vertebral artery. Contorni [1] was the first to recognize and describe this retrograde flow in 1960 using angiography in a patient who had an absent radial pulse. A year later, Reivich [2] associated this phenomenon with transient ischemic attack (TIA) and hence became the first scientist to correlate it with neurological symptoms. The term “subclavian steal”, however, was coined by Fisher [3] in 1961. This was after he reviewed Reivich’s article and observed that the anomaly caused the ipsilateral subclavian artery to receive retrograde flow from the contralateral circulation at the expense of the vertebro-basilar circulation [3].

Subclavian steal syndrome (SSS) has since been defined as a group of symptoms that arise from this reversed blood flow in the ipsilateral vertebral artery. It is often a differential diagnosis in any patient who presents with a pulse deficit or a systolic blood pressure difference of greater than 20 mmHg between the arms [4]. The subclavian steal, in the absence of other anatomical anomalies, is usually asymptomatic and often an incidental finding. Rarely, however, some patients may provoke the syndrome with exercise and present with transient ipsilateral arm claudication, ataxia and/or angina. The latter is prominent in those undergoing coronary artery bypass graft (CABG) surgery with the left internal mammary artery (LIMA) as the graft [5].

Angiography was the initial test used to screen for subclavian steal, with only high probability patients being investigated [6]. This selection bias in testing gave the false impression that SSS was not only rare, but also symptomatic [7]. However, with the emergence of noninvasive techniques such as ultrasound in 1970 and magnetic resonance angiography (MRA) in 1992, a greater number of asymptomatic patients have been identified, reflecting the more benign nature of the condition [8,9]. The prevalence and natural history of SSS has, nevertheless, only recently been reported [10].

In this review, we aim to present the epidemiology, etiology, pathophysiology and common variants of the subclavian steal syndrome. We also present the current recommendations on the best approach to diagnosis and treatment of this syndrome based on recent findings.

ANATOMY AND PATHOPHYSIOLOGY

Subclavian steal phenomenon often involves high-grade stenosis and/or occlusion of the subclavian artery, leading to a decrease in the SA pressure distal to the lesion (Figure 1). If the stenosis is severe and the affected arm is exerted, this pressure drop can cause the blood flow in the ipsilateral vertebral artery to reverse, stealing the blood from the unaffected SA via the contralateral vertebral artery in order to ensure adequate blood supply to the involved arm. Vigorous exercise of the arm and a sudden sharp turning of the head in the direction of the affected side have so far been shown to provoke the symptoms [11,12].

The pathophysiologic mechanism behind the subclavian steal via the vertebral artery is similar to the one involving coronary

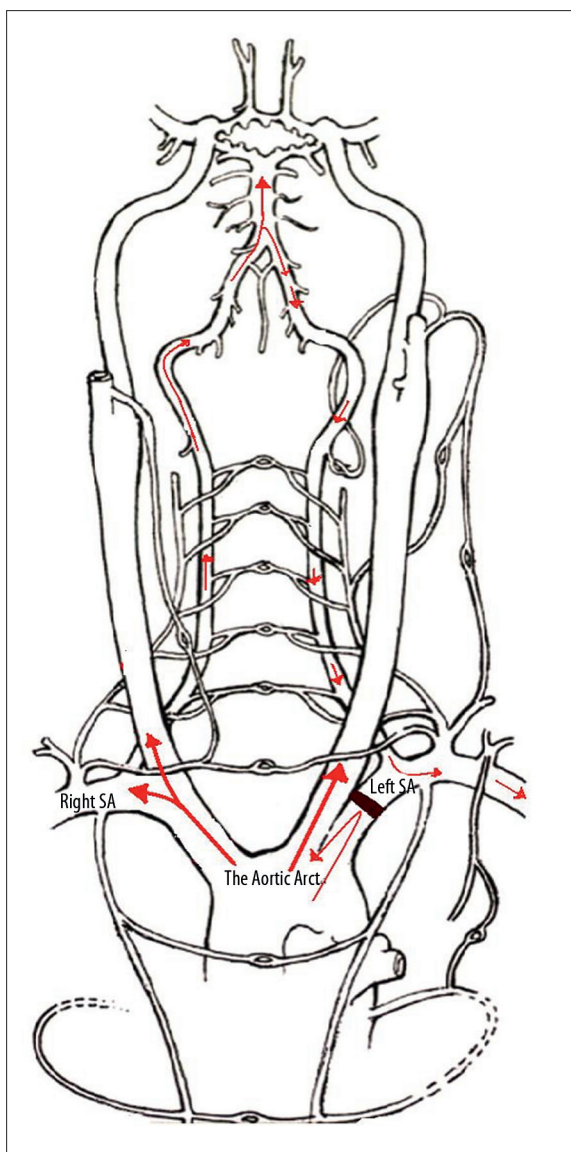


Figure 1. Schematic drawing showing a left-sided subclavian steal syndrome. Note that the lesion occurs just proximal to the origin of the left vertebral artery. SA – Subclavian Artery. (Redrawn and modified with permission from Grant et al., 2006).

arteries, except that different vessels are involved. The coronary subclavian steal syndrome (CSSS) has been defined as the reversal of flow in a previously constructed internal mammary artery (most often left internal mammary artery) and left coronary artery bypass graft, leading to myocardial ischemia [4] (Figure 2). The proximal subclavian artery stenosis in this scenario causes reversed flow in the ipsilateral IMA coronary artery graft. The potential red flags for CSSS include refractory unstable angina in a patient with a history of CABG [13] and/or impaired weaning of such patients after cardiopulmonary bypass [14]. More recently, cardiac arrest from ventricular fibrillation has been reported [15].

PREVALENCE

Most literatures report the prevalence of subclavian steal syndrome as between 0.6% to 6.4% [4,16]. The Joint Study of

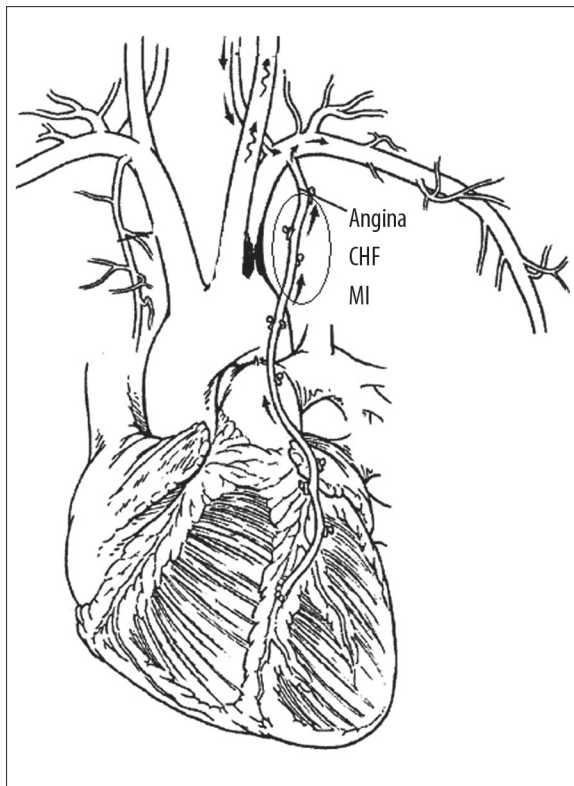


Figure 2. Schematic diagram showing the retrograde from the left coronary artery through the mammary artery bypass grafts in a patient with left subclavian artery stenosis. (Reproduced and modified with permission from Takach et al., 2006).

Extracranial Arterial Occlusion by Fields et al. yielded 2.5% incidence (168/6534), with only 5.3% of these patients experiencing neurological symptoms [17]. The most recent large-scale prevalence study by Labropoulos et al. [10] corroborates these previous findings, with 5.4% of SSS cases found after a series of 7881 ultrasound exams of the extracranial neck vessels.

The acquired subclavian steal phenomenon is mostly left-sided [4,18] with Labropoulos et al. [10] reporting 82.3% of their cases. Most authors estimate the ratio between the left- and right-side subclavian steal to be 4:1. The proposed explanation is that the acute angle of origin of the left subclavian artery increases flow turbulence and accelerates atherosclerosis at the subclavian-aortic junction [19]. The left subclavian artery is also the most commonly affected artery in Takayasu arteritis (85% of cases), a rare cause of the subclavian steal syndrome [20,21].

Males are affected by the atherosclerotic subclavian steal phenomenon more than females by a ratio of about 2:1. Patients above the age of 50 are also more likely to present with subclavian steal syndrome, most likely due to increased atherosclerosis in this age group. The steal from Takayasu's disease, however, presents far earlier (30 years in 90% of cases) and more commonly in the female gender [17]. A study by Watts and his colleagues [20] reported that in the Far East, Takayasu's arteritis was the cause in 36% (9/25) of patients requiring surgery to correct the

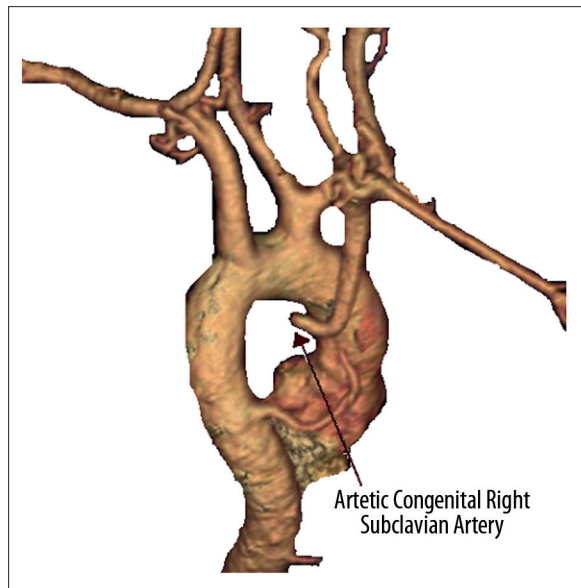


Figure 3. Posterior magnetic resonance angiographic (MRA) view of the aortic arch showing the atresia of the right proximal subclavian artery (RSA). An enlarged intercostal artery is seen emerging from the right side of the descending aorta. (Reproduced and modified with permission from Dainton et al, 2010).

subclavian steal syndrome, with the remaining cases stemming from atherosclerosis.

ETIOLOGY

Atherosclerotic vascular disease is the most common cause of both the subclavian steal phenomenon as well as the syndrome [17,18]. The risk factors for SSS are thus similar to those of atherosclerotic diseases and include smoking, hyperlipidemia, hypertension, diabetes mellitus, Family History and age. Other rare causes of subclavian steal include aortic dissection, Takayasu's arteritis [17,22], external compression on the subclavian artery and anatomical anomalies such as an isolated innominate artery [23].

Rare cases of congenital subclavian steal have also been described, with one review by Luetmer and Miller [24] reporting approximately 40 cases. An anomalous right-sided aortic arch may result in a congenital left-sided steal by way of an isolation of the left subclavian artery from the aorta [25]. In such circumstances, the left subclavian artery is connected to the left pulmonary artery via patent ductus arteriosus. The congenital pulmonary steal occurs in such a scenario when the reversed blood flow from the ipsilateral vertebral artery is directed into the isolated subclavian artery and eventually pulmonary artery. This phenomenon has been shown in isolated left subclavian artery coexisting with Tetralogy of Fallot [26]. The left arm in such circumstances is perfused by muscular collaterals from the left external carotid artery flowing into the distal left subclavian artery. Alternatively, a left-sided aortic arch may result in a left- or right-sided steal by proximal atresia of the involved subclavian artery. A recently described incidental finding of a right-sided congenital subclavian steal from proximal right subclavian artery atresia by Dainton et al. [27] is a classic example (Figure 3).

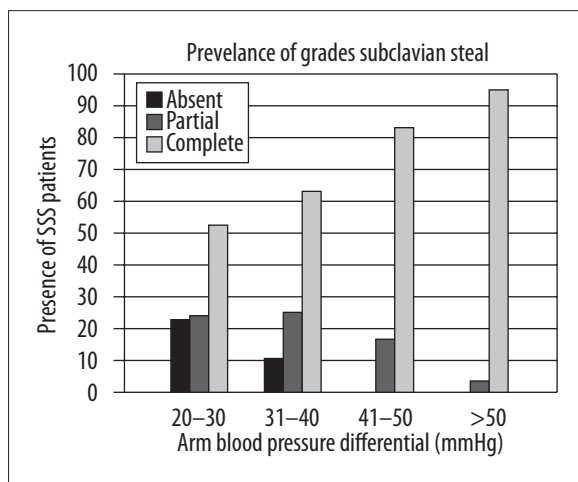


Figure 4. Prevalence of grades of subclavian steal with increasing arm BP differential. Grade 1: BP differential 20–30 mmHg; Grade 2: BP differential 31–40 mmHg; Grade 3: BP differential 41–50 mmHg, Grade 4: BP differential >50. (Reproduced and modified with permission from Labropoulos et al., 2010).

CLASSIFICATION

The subclavian steal phenomenon has been characterized either by the territory from which the blood is “stolen” [28] or the severity of hemodynamic disturbances in the vertebral artery [29]. Territories are classified as vertebral-vertebral, carotid-basilar, external carotid-basilar, or carotid-subclavian. A case has also been reported of a patient who had partial bilateral (carotid – carotid and carotid – vertebral) subclavian steal syndrome, with blood supply to both arms somewhat maintained by collateral vessels [30].

Severity is classified into three stages or grades:

Grade I (pre-subclavian steal): reduced antegrade vertebral flow,

Grade II (intermittent/partial/latent): alternating flow – antegrade flow in the diastolic phase and retrograde flow in the systolic phase,

Stage III (permanent/advanced): permanent retrograde vertebral flow.

A recent study by Labropoulos et al. [10] has shown that the prevalence of a complete steal increases with higher arm blood pressure differentials (PD) (Figure 4). They discovered that an arm PD >40 mm Hg was associated with significantly increased prevalence of partial and complete steal, with a greater proportion of the latter. All the patients under study who had no identified steal on ultrasound had a PD <40 mm Hg [10]. This corroborates an earlier finding by Tan and his colleagues [4] who reported a modest correlation between vertebral arterial waveforms and the blood pressure differentials in patients with subclavian steal syndrome.

PRESENTATION: SIGNS AND SYMPTOMS

SSS benign condition since the reversed blood flow in the ipsilateral vertebral artery often serves as an effective collateral

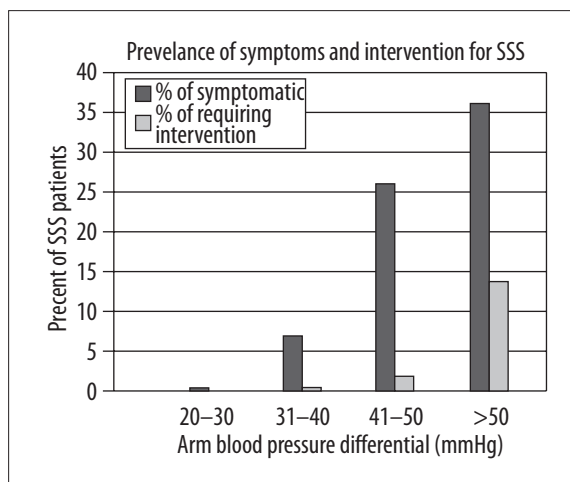


Figure 5. Prevalence of symptoms and interventions in patients with SSS with increasing arm Blood Pressure (BP) differential. (Reproduced and modified with permission from Labropoulos et al., 2010).

pathway for the affected arm [31]. Significant ischemia of the arm is therefore rare, even in patients who have complete occlusion of the proximal subclavian artery [16,32]. Some authors have suggested that the patients who develop symptoms from this phenomenon usually have additional vascular pathology involving either the intracranial or extra-cranial vessels [33]. However, while there is some logic to this assertion, cases of patients who had no significant stenosis in any other cervical or intracranial artery yet still suffered from chronic posterior circulation ischemia as a result of SSS has also been reported [34].

Recent studies have shown a linear correlation between increasing arm BP differential with the occurrence of symptoms [4,10], with symptoms reported to be more common in patients with higher blood pressure differentials. These studies have validated the use of arm BP differential as a predictor of the severity of the syndrome. While only 1.38% of their patients with a BP difference of 20 to 30 mm Hg were symptomatic, Labropoulos et al. [10] reported that this percentage rose to 38.5% in the group of patients with BP difference >50 mm Hg (Figure 5). Interestingly, patients who hemodynamically belong to grade II often have symptoms from the posterior circulation more than patients with permanent retrograde blood flow in the vertebral artery [35].

The ischemic symptoms are probably associated with inadequate collateral circulation, and arise from decreased perfusion of either the brain, affected arm, and in cases of CSSS, the heart [5,12]. The vertebrobasilar symptoms include paroxysmal vertigo, dizziness, diplopia, ataxia, dysarthria and syncopal attacks. Ischemia to the hand often manifests as arm weakness, claudication, paresthesias or coldness in the arm [11,12].

Case reports of hemispheric symptoms have also been reported by several authors [11,16]. However, Labropoulos et al. have refuted these findings as erroneous, arguing that they were confounded by commonly coexisting diseases of the anterior circulation, such as carotid stenosis [10]. They cited a study by Hennerici et al. [16] to support their claim.

Hennerici and his colleagues [16] initially reported a 36% incidence of neurologic symptoms due to SSS, only to drop to 5% after eliminating the symptoms due to the anterior circulation pathology.

The coronary-subclavian steal symptom usually manifests as a refractory unstable angina, often during coronary revascularization after the CABG surgery. Since the internal mammary artery is often anastomosed with the left coronary artery, and the blood flow in the IMA is dependent on an adequate arterial pressure in the subclavian artery, subclavian stenosis can lead to a reversal of flow through the graft from the coronary to the subclavian circulation, resulting in myocardial ischemia [36,37].

SCREENING AND DIAGNOSIS

Transient and provocative symptoms, if they occur, often characterize the history of subclavian steal syndrome. However, chronic symptoms have also been described. Recently, Sharma et al. reported the case of a 58-year-old man who had complained of progressive ataxia and aphasia for six months. When they evaluated him, he was found to suffer from chronic brain stem ischemia due to subclavian steal syndrome [34]. Similarly, Peera et al. [22] evaluated a 48-year-old woman with a chronic history of left arm claudication and syncope and found that she had subclavian steal syndrome from Takayasu arteritis.

An arm blood pressure difference greater than 20 mm Hg has been proven to be a sensitive threshold for the detection of the subclavian steal. The prevalence of the syndrome in patients fulfilling this criterion ranges from 78% to 88% [16], with Tan et al. [4] reporting a slightly lower percentage of 55%. In most cases, the affected arm will also have a weakened or absent radial and ulnar pulses. An audible bruit over the supraclavicular fossa can also be heard on auscultation. Unless the patient is symptomatic at the time of neurological examination, there are no neurological signs associated with the subclavian steal phenomenon.

The non-invasive Colour-coded Doppler or transcranial Doppler ultrasonography is now regarded by many authors as the standard bed-side screening tool for subclavian steal phenomenon [15]. It is not only useful in assessing the severity of the vertebral-steal hemodynamics, but can also show other lesions in the neck vessels. Transcranial Doppler may also be used to further characterize the flow changes in the posterior circulation [38,39].

The hyperemia – ischemia cuff test is diagnostic test often monitored with the ultrasound to uncover any occult steal. It is normally induced by inflating the arm blood pressure cuff to at least 20 mm Hg above the systolic blood pressure for a few minutes. A rapid deflation of the cuff will lead to increased blood flow in the arm, and if the patient has a hidden subclavian steal, there will be a reversal of blood flow in the ipsilateral vertebral artery. This retrograde flow can be observed using the ultrasound [40].

CT or MR angiography is the confirmatory tests for any suspected subclavian steal cases found on ultrasound exams. This is because not all retrograde vertebral flow seen on ultrasound examinations constitute true subclavian steal.

Some have been shown to stem from proximal vertebral artery stenosis or occlusion. These techniques can directly show the anatomical features of subclavian stenosis or occlusion, the presence of retrograde vertebral flow as well as any associated extracranial and intracranial stenoses [10,39].

MANAGEMENT

Only a small percentage of patients with subclavian steal phenomenon need any therapeutic intervention at all, with Labropoulos et al. [10] reporting just 1.4% of the 7881 patients (or 18.4% of their symptomatic cases). In the same study, they also showed that the blood pressure difference between the arms correlated with the need for intervention, since the majority of their patients who underwent surgical management had higher arm BP differentials and/or complete steal [10].

Thus, for patients with only isolated symptoms, conservative treatments alone are currently recommended, regardless of the degree of “steal” in the vertebral artery [10,41]. Such regimen primarily involves reducing the risk for subclavian arterial atherosclerosis and includes treating hypertension, diabetes mellitus and hyperlipidemia, in addition to smoking cessation. Such patients should be monitored periodically in out-patient clinics using ultrasound.

The open surgical options such as bypass grafting, or endovascular treatments involving angioplasty and stenting, are often reserved for serious clinical symptoms. They have been shown to be relatively safe procedures with considerable amounts of symptomatic relief [42,43].

Carotid – subclavian bypass surgery has been used successfully in patients who have isolated steno-occlusive subclavian disease. Patency rates have been reported as high as 95% at 10 years [44–46]. The now widely cited retrospective study by AbuRahma and colleagues [46] of the results of 51 carotid-subclavian bypass surgeries showed no mortality after almost 8 years of follow-up, with symptoms recurring in only four of the patients. More recently, Qi et al. [47] have reported a series of operations with a success rate of up to 98.11% (52 out of 53 cases). Only one complication of thrombogenesis occurred at an anastomotic site [47]. After an average of 24.5 months of follow-up, there was no mortality and the postoperative graft patency rate, confirmed by Doppler ultrasound, was 100%. All the vertebrobasilar and arm ischemic symptoms had also disappeared. This revascularization technique is therefore still regarded as a low-risk procedure for symptomatic patients whose donor carotid arteries lack significant atherosclerotic disease.

The development of endovascular therapy has fundamentally changed the management of subclavian steal syndrome patients. Similar clinical outcomes to open surgical methods can now be achieved with minimal risks under local anesthesia [48–50]. A retrospective study done by De Vries et al. [42], where they analyzed 110 patients treated with percutaneous transluminal angioplasty and followed them for almost 3 years, showed that patency was achieved in 93% of patients who had subclavian stenosis and in 65% who had occlusion [42]. More recently, Wang et al. [49] reported a technical success rate of 95.1% (58/61) with angioplasty and stenting procedure that they conducted over 10 years. At

12 month follow-up, the primary patency was 98%, a number which dropped to 82% at 5 years [49].

Our review found only few studies comparing these surgical approaches, with no long-term results published [51,52]. Linni et al. [51] compared prospective data which was retrospectively analyzed of 40 patients who underwent the stent-supported percutaneous transluminal angioplasty (sPTA) and 34 patients who had subclavian-to-carotid artery transposition (SCT). They reported that the primary sPTA failed in 48% of occlusions (30% of all sPTAs), while all of the SCTs were successful. As a result of this experience, they recommended that the primary sPTA should be used for SA stenosis and surgery reserved for the SA occlusions [51].

CONCLUSIONS

We have reviewed the subclavian steal phenomenon, a common but relatively benign condition. Once thought to be rare, the emergence of new imaging techniques and interventions has shown marked increase in both its diagnosis and management. On its own, it rarely poses any significant risk of brain damage and/or death. However, since it often co-exists with other atherosclerotic diseases, it may mask other serious vascular disorders and should be considered in the differential diagnosis of patients who present with symptoms such as transient ischemic attacks or cardiac angina.

Lastly, our review affirms that the surgical treatment of subclavian steal syndrome yields good prognosis, but the decision to intervene surgically should be based on the symptoms and clinical exam rather than imaging studies. This is in line with the recent literature findings which correlate the occurrence of symptoms in this syndrome with arm blood pressure differentials. In addition, while our review found different surgical approaches to managing this syndrome, angioplasty and stenting is the overwhelmingly favored surgical option for managing symptomatic subclavian steal due to its high technical success rates and lower risks. However, there is still no large, prospective, randomized, controlled trial to compare the long-term patency rates between endovascular and open surgical techniques.

REFERENCES:

- Contorni L: Il Circolo collaterali vertebro-vertebrali nella obliterazione dell'arteria subclavian all sua origine. *Minerva Chira*, 1960; 15: 268-71
- Reivich M, Holling HE, Roberts B et al: Reversal of blood flow through the vertebral artery and its effect on cerebral circulation. *N Engl J Med*, 1961; 265: 878-85
- Fisher CM: New vascular syndrome, "subclavian steal." *N Engl J Med*, 1961; 265: 912-13
- Tan TY, Schminke U, Lien LM, Tegeler CH: Subclavian steal syndrome: can the blood pressure difference between arms predict the severity of steal? *J Neuroimaging*, 2002; 12: 131-35
- Takach T, Reul GJ, Cooley DA et al: Myocardial Thievery: The Coronary-Subclavian Steal Syndrome. *Ann Thorac Surg*, 2006; 81: 386-92
- Heidrich H, Bayer O: Symptomatology of the subclavian steal syndrome. *Angiology*, 1969; 20: 406-13
- Herring M: The subclavian steal syndrome: a review. *Am Surg*, 1977; 43: 220-28
- Grossman BL, Brisman R, Wood EH: Ultrasound and the subclavian steal syndrome. *Radiology*, 1970; 94: 1-6
- Drutman J, Gyorke A, Davis WL, Turski PA: Evaluations of subclavian steal with two-dimensional phase-contrast and two-dimensional time-of-flight MR angiography. *Am J Neuroradiol*, 1994; 15: 1642-45
- Labropoulos N, Nandivada P, Bekelis K: Prevalence and Impact of the Subclavian Steal Syndrome. *Ann Surg*, 2010; 252: 166-70
- Smith JM, Koury HI, Hafner CD, Welling RE: Subclavian steal syndrome. A review of 59 consecutive cases. *J Cardiovasc Surg (Torino)*, 1994; 35: 11-14
- Taylor CL, Selman WR, Rutcherson RA: Steal affecting the central nervous system. *Neurosurgery*, 2002; 50: 679-89
- Cuisset T, Sarma J, Hamilos M et al: Coronary-subclavian steal syndrome: an usual cause of refractory unstable angina. *Int J Cardiol*, 2008; 127(3): e181-82
- Carrascal Y, Arroyo J, Fuertes JJ, Echevarría JR: Massive coronary subclavian steal syndrome. *Ann Thorac Surg*, 2010; 90(3): 1004-6
- Vecera J, Vojtisek P, Varvarovský I et al: Non-invasive diagnosis of coronary-subclavian steal: role of the Doppler ultrasound. *Eur J Echocardiogr*, 2010; 11(9): E34
- Hennerici M, Klemm C, Rautenberg W: The subclavian steal phenomenon: a common vascular disorder with rare neurologic deficits. *Neurology*, 1988; 38: 669-73
- Fields WS, Lemak NA: Joint study of extracranial arterial occlusion. VII. Subclavian steals - a review of 168 cases. *JAMA*, 1972; 222: 1139-43
- Bornstein NM, Norris JW: Subclavian steal: a harmless hemodynamic phenomenon? *Lancet*, 1986; 2: 303-5
- Nicholls SC, Koutlas TC, Strandness DE: Clinical significance of retrograde flow in the vertebral artery. *Ann Vasc Surg*, 1991; 5: 331-36
- Watts R, Al-Taiar A, Mooney J et al: The epidemiology of Takayasu arteritis in the UK. *Rheumatology*, 2009; 48: 1008-11
- Procter CD, Hollier LH: Takayasu's arteritis and temporal arteritis. *Ann Vasc Surg*, 1992; 6: 195-98
- Peera AM, LoCurto M, Elfond M: A case of Takayasu arteritis causing subclavian steal and presenting as syncope. *Journal of Emergency Medicine*, 2001; 40(2): 158-61
- Reeves M, Colen M, Sheridan BJ, Ward C: Isolated Innominate Artery as a Cause of Subclavian Steal and Cerebral Hemisphere Atrophy. *Pediatr Cardiol*, 2010; 31: 1083-85
- Luetmer PH, Miller GM: Right aortic arch with isolation of the left subclavian artery: Case report and review of the literature. *Mayo Clin Proc*, 1990; 65: 407-13
- Edwin F, Mamorare HM: Congenital pulmonary steal in subclavian artery isolation. *Ann Thorac Surg*, 2010; 90(5): 1744-45
- Carano N, Piazza P, Agnetti A, Squarcia U: Congenital pulmonary steal syndrome associated with tetralogy of Fallot, right aortic arch, and isolation of the left subclavian artery. *Pediatr Cardiol*, 1997; 18: 57-60
- Dainton CJ, Iglar K, Prabhudesai V: A case of right-sided congenital subclavian steal. *Can J Cardiol*, 2010; 26(1): e15-16
- Vollmar J, Elbayer M, Kolmar D et al: Cerebral circulatory insufficiency in occlusive processes of the subclavian artery ("subclavian steal effect"). *Dtsch Med Wochenschr*, 1965; 90: 8-14
- Branchereau A, Magnan PE, Espinoza H, Bartoli JM: Subclavian artery stenosis: hemodynamic aspects and surgical outcome. *J Cardiovasc Surg*, 1991; 32: 604-12
- Khurana V, Gambhir IS, Srivastava A, Kishore D: Dizziness and collapse? It's a steal! *Lancet*; 374(9699): 1472
- Bron C, Hirt L, Halabi G, Saucy F et al: Asymptomatic high flow subclavian steal in a patient with hemodialysis access. *J Vasc Access*, 2010; 11(1): 63-65
- Gosselin C, Walker PM: Subclavian steal syndrome: existence, clinical features, diagnosis and management. *Semin Vasc Surg*, 1996; 9: 93-97
- Webster MW, Downs L, Yonas H et al: The effect of arm exercise on regional cerebral blood flow in the subclavian steal syndrome. *Am J Surg*, 1994; 168: 91-93
- Sharma V, Chuah B, Teoh H et al: Chronic brainstem ischemia in subclavian steal syndrome. *J Clin Neurosci*, 2010; 17: 1339-41
- Thomassen L, Aarli YES: Subclavian steal phenomenon. Clinical and hemodynamic Aspects. *Acta Neurol Scand*, 1994; 90: 241-44
- Bilku RS, Khogali SS, Been M: Subclavian artery stenosis as a cause for recurrent angina after LIMA graft stenting. *Heart*, 2003; 89: 1429
- Kroll CR, Agarwal M, Stouffer GA: Angiographic evidence of coronary-subclavian steal syndrome. *Circulation*; 2002; 105: e184
- Kaneko A, Ohno R, Hattori K et al: Color-coded Doppler imaging of subclavian steal syndrome. *Intern Med*, 1998; 37: 259-64
- Lum CF, Ilse PF, Kawasaki B: Subclavian steal syndrome. *Optometry*, 2004; 75: 147-59

40. Kliewer MA, Hertzberg BS, Kim DH et al: Vertebral artery Doppler waveform changes indicating subclavian steal physiology. *AJR Am J Roentgenol*, 2000; 174: 815-19
41. Olsen K, Lund C: Subclavian steal syndrome. *Tidsskr Nor Laegeforen*, 2006; 126: 3259-62
42. De Vries JP, Jager LC, van den Berg JC: Durability of Percutaneous transluminal angioplasty for obstructive lesions of proximal subclavian artery: long term results. *Vasca J Surg*, 2005; 41: 19-23
43. Bates MC, Broc M, Lavigne PS, Stone P: Subclavian artery stenting: factors influencing long-term outcome. *Catheter Cardiovasc Intervet*, 2004; 61: 5-11
44. Uurto IT, Lautamatti V, Zeitlin R, Salenius JP: Long-term outcome of surgical revascularization of supra-aortic vessels. *World J Surg*, 2002; 26: 1503-6
45. Vitti MJ, Thompson BW, Read RC et al: Carotid-subclavian bypass: a twenty-two-year experience. *J Vasc Surg*, 1994; 20: 411-17
46. AbuRahma AF, Robinson PA, Jennings TG: Carotid-subclavian artery bypass grafting with PTFE grafts for symptomatic subclavian artery stenosis or occlusion: 20-year experience. *Vasca J Surg*, 2000; 32: 411-18
47. Qi L, Gu Y, Zhang J, Yu H et al: Surgical treatment of subclavian occlusion. *Zhongguo Xiu Fu Chong Jian Wai Ke Za Zhi*, 2010; 24(9): 1030-32
48. Palchik E, Bakken AM, Wolford HY et al: Subclavian artery revascularization: an outcome analysis based on mode of therapy and presenting symptoms. *Ann Vasc Surg*, 2008; 22: 70-78
49. Wang KQ, Wang ZG, Yang BZ et al: Long-term results of endovascular therapy for proximal subclavian arterial obstructive lesions. *Chin Med J (Engl)*, 2010; 123(1): 45-50
50. Galkin PV, Antonov GI, Mitroshin GE et al: Surgical correction of cerebral blood flow steal syndrome by aortic branches stenosis. *Khirurgiia (Mosk)*, 2009; 7: 15-21
51. Linni K, Ugurluoglu A, Mader N et al: Endovascular management versus surgery for proximal subclavian artery lesions. *Ann Vasc Surg*, 2008; 22(6): 769-67
52. Farina C, Mingoli A, Schultz RD et al: Percutaneous transluminal angioplasty versus surgery for subclavian artery occlusive disease. *Am J Surg*, 1989; 158: 511-14