

# Microforceps in the Diagnosis of Pancreatic Bronchogenic Cyst Under Endoscopic Ultrasound Guidance

Abdul Kouanda, MD<sup>1</sup>, Sarah Umetsu, MD, PhD<sup>2</sup>, and Sun-Chuan Dai, MD<sup>1</sup>

<sup>1</sup>Department of Gastroenterology, University of California, San Francisco, San Francisco, CA

<sup>2</sup>Department of Pathology, University of California, San Francisco, San Francisco, CA

## ABSTRACT

Bronchogenic cysts belong in the category of foregut duplication cysts, along with esophageal and neuroenteric duplication cysts. They are often found incidentally on cross-sectional imaging. Although they are benign, patients often undergo surgical resection because of diagnostic uncertainties. We report the first case of bronchogenic cyst diagnosed with the microforceps, after previous nondiagnostic fine-needle aspirations, thus allowing the patient to avoid surgery.

## INTRODUCTION

Bronchogenic cysts are foregut duplication cysts. These rare malformations occur because of errors in the development of the esophagus and the respiratory tract.<sup>1</sup> Most, 50%–70%, are found along the gastrointestinal tract, whereas 7%–15% are respiratory tract in origin.<sup>2</sup> They are commonly found in the mediastinum, but gastric diaphragmatic, retroperitoneal, and intra-abdominal bronchogenic cysts have all been described.<sup>3</sup> Endoscopic ultrasound (EUS) is often performed after the identification of suspected bronchogenic cysts for further characterization. On EUS, typical findings are anechoic or hypoechoic internal contents, multilayered cyst wall, and thick mucinous fluid on fine-needle aspiration (FNA).<sup>4</sup> The finding of detached ciliary tufts on cytology analysis is considered diagnostic.<sup>5</sup> Although cytological evaluation from EUS-FNA was highly diagnostic in a previous study of the fine-needle mediastinal bronchogenic cyst, in most cases, EUS-FNA is nondiagnostic, and as a result, most of these cases are diagnosed after surgical resection and pathologic review of the specimen.<sup>5–10</sup> To date, there have been 2 case reports of bronchogenic cysts associated with the pancreas diagnosed preoperatively using EUS-FNA: one with a 22-gauge needle and the other without the mention of needle type.<sup>11,12</sup> We report on the third case of pancreatic bronchogenic cysts diagnosed with EUS, mistaken for a pseudocyst for several years, and the first made diagnosis of any foregut duplication cyst using the microforceps.

## CASE REPORT

The patient is a 54-year-old woman with a medical history of Hashimoto's thyroiditis and psoriatic arthritis who presented for evaluation of a known and stable 3-cm pancreatic tail cyst that was suspected to be the cause of chronic abdominal pain. The cyst was discovered in 2008 by computed tomography, after receiving an endoscopic retrograde cholangiopancreatography with biliary sphincterotomy because of choledocholithiasis that was complicated by postendoscopic retrograde cholangiopancreatography pancreatitis. EUS-FNA of 6 mL of brown cyst fluid was suspicious for a pseudocyst or mucinous cyst. Carcinoembryonic antigen (CEA) level was of 213 ng/mL, and amylase level was 25,740 U/L. Pseudocyst was favored based on the overall clinical picture despite the slightly elevated CEA. Serial imaging was recommended, which documented relative stability but not the resolution of the suspected pseudocyst.

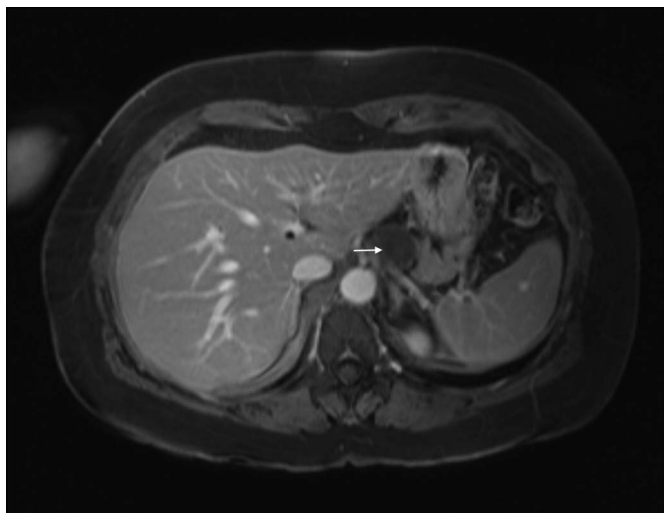
Over the next few years, the patient had recurrent right upper quadrant pain despite stable imaging. At the time of our evaluation in 2016, we ordered an abdominal magnetic resonance imaging which demonstrated the same cyst now measuring 2.5 × 2.9 × 2.6 cm

with T2 hyperintensity most likely representing a cyst with proteinaceous components (Figure 1). Subsequent EUS showed an anechoic cyst measuring  $3.3 \times 2.0$  cm with multiple hyperechoic foci representing debris and a possible single mural nodule or calcification noted in the cyst wall (Figure 2). FNA using the 19-gauge needle resulted in 0.5 mL of blood-tinged and gelatinous fluid which was sent for cytology. Owing to the scant amount of fluid collected, fluid CEA and amylase were not obtained. Given the previous nondiagnostic EUS-FNA, microforceps were used to biopsy the cyst wall in an effort to achieve some clarity as to whether the cyst required resection or was benign and therefore not requiring further surveillance imaging studies or procedures. Using the through-the-needle microforceps (US Endoscopy, Mentor, OH), 4 biopsies of the cyst wall were obtained (one pass of the microforceps for each bite).

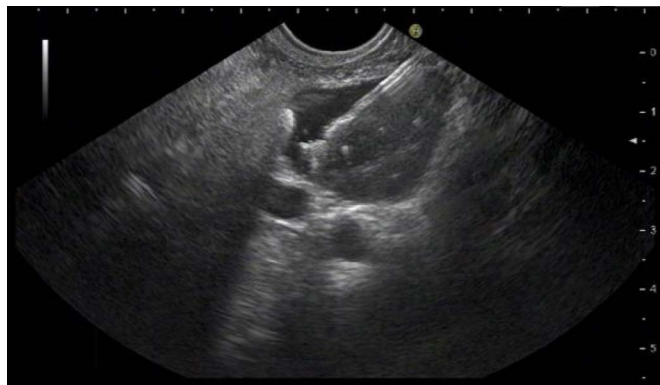The cytological sample was paucicellular with ciliated columnar epithelium, entertaining the possibility of a bronchogenic or ciliated foregut cyst. The microforceps biopsy specimen confirmed evidence of bronchogenic or ciliated foregut cyst characterized by fragments of ciliated columnar epithelium with subepithelial seromucinous glands (Figure 3). Given the benign nature of this lesion, surgical resection was not pursued, surveillance was not recommended, and the patient was reassured. In the subsequent 2 years that the patient has been in contact via our electronic medical record messaging system, she has not reported any persistent gastrointestinal symptoms and has been diagnosed by her rheumatologist with fibromyalgia.

## DISCUSSION

We describe, to our knowledge, the third case of a bronchogenic cyst associated with the pancreas diagnosed preoperatively with EUS and thus avoiding surgery. Bronchogenic cysts are generally considered as benign malformations most commonly found in the mediastinum, although the true cancer risk is unknown.<sup>12</sup> They are rare findings in the abdomen and



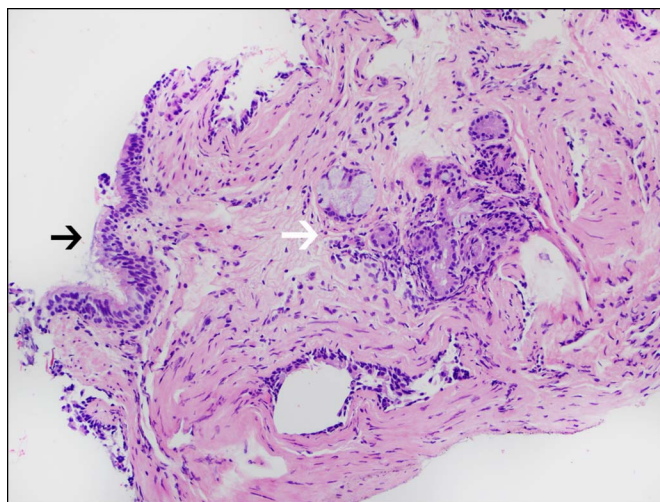
**Figure 1.** Magnetic resonance imaging showing a pancreatic cyst (white arrow) with proteinaceous components.



**Figure 2.** Endoscopic ultrasound showing an oval and anechoic cyst in association with the tail of the pancreas. Biopsies of the cyst wall were performed using the through-the-needle microforceps.

retroperitoneum. Novel, in this case, is the use of the through-the-needle microforceps for diagnosis. This is the first case of any foregut duplication cysts diagnosed using the microforceps.

The microforceps is a product of US Endoscopy designed for EUS procedures by passage through the 19-gauge FNA needle. It is 0.80 mm in diameter and has a jaw opening width of 4.3 mm.<sup>13</sup> In one multicenter study of 42 patients, the microforceps had a cyst tissue acquisition yield of 90% and was superior to FNA for providing a specific diagnosis (35.7% vs 4.8%,  $P = 0.001$ ).<sup>14</sup> As in this case, the microforceps has been reported to be useful in the diagnosis of a pancreatic cyst with a previous inconclusive FNA.<sup>15</sup> As described above, most cases of bronchogenic cysts are diagnosed postoperatively after surgical resection because of uncertainties in the diagnosis. Strong consideration should be given to the use of this tool for the diagnosis of pancreatic cysts before surgical excision in such cases. This is especially relevant in cases where the cysts are asymptomatic and would otherwise not be removed to alleviate symptoms of mass effect.



**Figure 3.** Cyst wall histology demonstrating fragments of ciliated respiratory epithelium (black arrow) with subepithelial seromucinous glands (white arrow) consistent with bronchogenic cyst.

There are very limited cases of cyst fluid analysis for bronchogenic cysts; 2 previous reports have shown them to harbor high amylase, as in our case; however, in another case report, there was no increase in amylase.<sup>16–18</sup> CEA in the cyst fluid was markedly elevated in one case report but only minimally elevated in this case.<sup>8</sup> Thus, as of now, these markers do not appear to be reliable in making the diagnosis of a bronchogenic cyst. Although there are limited data, the microforceps has demonstrated an excellent safety record with no major complications reported in a cohort of 48 patients.<sup>19</sup> However, there have been reported cases of self-limited local bleeding from the biopsy site and pancreatitis due to the passage of the needle through the pancreatic parenchyma.<sup>19</sup> In another series of 20 patients who underwent pancreatic cyst puncture using the microforceps, there were no adverse events reported.<sup>20</sup> In conclusion, bronchogenic cysts are notoriously difficult to diagnose nonsurgically, but the use of the microforceps may lead to more specific diagnosis and avoidance of surgery in otherwise asymptomatic patients.

## DISCLOSURES

Author contributions: A. Kouanda wrote the manuscript and is the article guarantor. S. Umetsu revised the manuscript for intellectual content. S-C Dai approved the final manuscript.

Financial disclosure: None to report.

Informed consent was obtained for this case report.

Received November 3, 2019; Accepted February 3, 2020

## REFERENCES

1. Nobuhara KK, Gorski YC, La Quaglia MP, Shamberger RC. Bronchogenic cysts and esophageal duplications: Common origins and treatment. *J Pediatr Surg*. 1997;32:1408–13.
2. Whitaker JA, Deffenbaugh LD, Cooke AR. Esophageal duplication cyst: Case report. *Am J Gastroenterol*. 1980;73:329–32.
3. Liang MK, Yee HT, Song JW, Marks JL. Subdiaphragmatic bronchogenic cysts: A comprehensive review of the literature. *Am Surg*. 2005;71:1034–41.
4. Liu R, Adler DG. Duplication cysts: Diagnosis, management, and the role of endoscopic ultrasound. *Endosc Ultrasound*. 2014;3:152–60.
5. Eloubeidi MA, Cohn M, Cerfolio RJ, et al. Endoscopic ultrasound-guided fine-needle aspiration in the diagnosis of foregut duplication cysts: The value of demonstrating detached ciliary tufts in cyst fluid. *Cancer*. 2004;102:253–8.
6. Shin SS, Choi YD, Jun CH. An incidental pancreatic mass in a young woman. *Gastroenterology*. 2017;153:e16–7.
7. Kim EY, Lee WJ, Jang KT. Retroperitoneal bronchogenic cyst mimicking a pancreatic cystic tumour. *Clin Radiol*. 2007;62:491–4.
8. Runge T, Blank A, Schäfer SC, Candinas D, Gloor B, Angst E. A retroperitoneal bronchogenic cyst mimicking a pancreatic or adrenal mass. *Case Rep Gastroenterol*. 2013;7:428–32.
9. Choi KK, Sung J, Kim J, et al. Intra-abdominal bronchogenic cyst: Report of five cases. *Korean J Hepatobiliary Pancreat Surg*. 2012;16:75–9.
10. Mirsadeghi A, Farrokhi F, Fazli-Shahri A, Gholipour B. Retroperitoneal bronchogenic cyst: A case report. *Med J Islam Repub Iran*. 2014;28:56.
11. Dua KS, Vijayapal AS, Kengis J, Shidham VB. Ciliated foregut cyst of the pancreas: Preoperative diagnosis using endoscopic ultrasound guided fine needle aspiration cytology—A case report with a review of the literature. *Cytojournal*. 2009;6:22.
12. Obando J, Merkle E, Bean SM. A retroperitoneal bronchogenic cyst. *Clin Gastroenterol Hepatol*. 2009;7:A24-e1.
13. Moray micro forceps. (<http://www.usendoscopy.com/products/moray-micro-forceps>).
14. Basar O, Yuksel O, Yang DJ, et al. Feasibility and safety of microforceps biopsy in the diagnosis of pancreatic cysts. *Gastrointest Endosc*. 2018;88:79–86.
15. Huelsen A, Cooper C, Saad N, Gupta S. Endoscopic ultrasound-guided, through-the-needle forceps biopsy in the assessment of an incidental large pancreatic cystic lesion with prior inconclusive fine-needle aspiration. *Endoscopy*. 2017;49:E109–10.
16. Hase N, Kashihara T, Ohki A, et al. A case of abdominal bronchogenic cyst which had interesting ultrasonographic finding, and contained fluid with an increase in amylase. *Nihon Shokakibyo Gakkai Zasshi*. 1996;93:594–8. [Japanese.]
17. Hasegawa T, Murayama F, Endo S, Sohara Y. Recurrent bronchogenic cyst 15 years after incomplete excision. *Interact Cardiovasc Thorac Surg*. 2003;2:685–7.
18. Andersson R, Lindell G, Cwikiel W, Dawiskiba S. Retroperitoneal bronchogenic cyst as a differential diagnosis of pancreatic mucinous cystic tumor. *Dig Surg*. 2003;20:55–7.
19. Zhang ML, Arpin RN, Brugge WR, Forcione DG, Basar O, Pitman MB. Moray micro forceps biopsy improves the diagnosis of specific pancreatic cysts. *Cancer Cytopathol*. 2018;126(6):414–20.
20. Mittal C, Obuch J, Wani S, et al. Diagnostic yield of micro forceps biopsies during endoscopic ultrasound evaluation of pancreatic cystic lesions: 69. *Am J Gastroenterol*. 2017;112:S31.

**Copyright:** © 2020 The Author(s). Published by Wolters Kluwer Health, Inc. on behalf of The American College of Gastroenterology. This is an open-access article distributed under the terms of the Creative Commons Attribution-Non Commercial-No Derivatives License 4.0 (CCBY-NC-ND), where it is permissible to download and share the work provided it is properly cited. The work cannot be changed in any way or used commercially without permission from the journal.