

# Transvenous coaxial coil occlusion of the levoatriocardinal vein

© Meng-Luen Lee<sup>\*1</sup>, © Ing-Sh Chiu<sup>\*\*</sup>, © Chiung-Ying Liao<sup>\*\*\*</sup>

<sup>\*</sup>Division of Pediatric Cardiology, Departments of Pediatrics, <sup>\*\*</sup>Surgery, <sup>\*\*\*</sup>Medical Imaging, Changhua Christian Hospital; Changhua-Taiwan

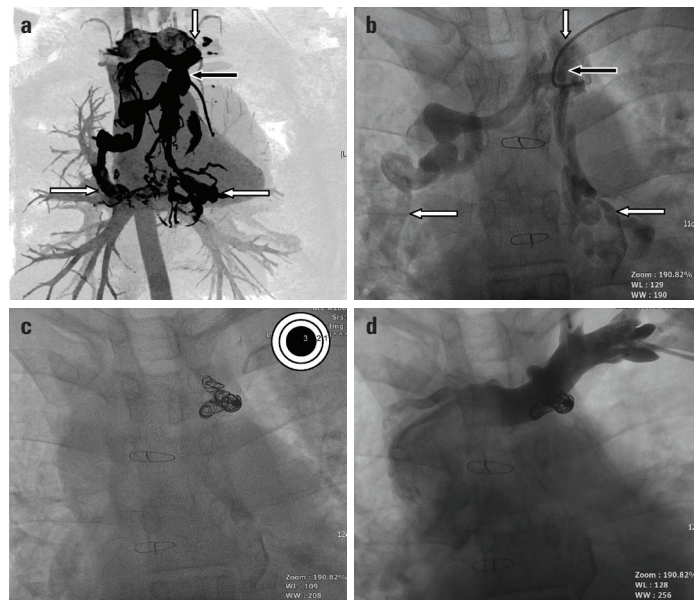
<sup>1</sup>Department of Pediatrics, School of Medicine, Kaohsiung Medical University; Kaohsiung-Taiwan

## Introduction

The term levoatriocardinal vein (LACV) was coined by Edwards and DuShane (1), describing a vascular connection between the left atrium and the left innominate vein (an embryologic derivative of the cardinal system). LACV usually serves as an egress for the pulmonary venous blood to decompress the left atrium in obstructive left heart lesions (2). We reported a 20-year-old man who presented with oxygen desaturation and chest tightness due to LACV, which was recanalized 17 years after the total correction of congenitally corrected transposition (CCT) of the great arteries, subpulmonary ventricular septal defect (VSD), and supravulvar pulmonary stenosis (SVPS). We have briefly discussed the pathogenesis, hemodynamic interference, clinical manifestations, and management of LACV after bidirectional Glenn shunt (BGS).

## Case Report

A 20-year-old adult male who underwent BGS and double-switch operation (hemi-Mustard and Rastelli procedures) for CCT, subpulmonary VSD, and SVPS at the age of 3 years complained of intermittent chest tightness for years. At the outpatient clinic, he did not have cyanosed lips and clubbed fingers. A grade 3/6 systolic ejection murmur was heard over the left upper sternal border. Cardiac enzymes, chest radiogram, electrocardiogram, and echocardiography were inconclusive to achieve a diagnosis. On admission, he was 178 cm in height and 85 kg in weight. The pulse rate was 70/min, respiratory rate 20/min, and blood pressure 120/74 mm Hg. The hemoglobin level was slightly elevated (16.1 g/dL). Computed tomography angiography (Fig. 1a) and conventional angiography (Fig. 1b) showed a systemic vein draining from the left brachiocephalic vein into bilateral upper pulmonary veins, indicating the presence of LACV, which measured 8.0–12.7 mm in diameters. By cardiac catheterization, oxygen saturations of the left ventricle and ascending aorta were both 92%. The systolic pressure of the right ventricle and main pulmonary artery was 32 mm Hg and 19 mm Hg, respectively. The left ventricular end-diastolic pressure was 4 mm Hg. The mean pressure of the left brachiocephalic vein and right atrium was 14 mm Hg and 12 mm Hg, respectively. The mean pressure of the main pulmonary



**Figure 1.** (a) Computed tomography angiography (expressed by maximum intensive projection) and (b) left subclavian venography showed a serpentine systemic venous channel draining from the left subclavian vein (vertical white arrow) into the bilateral upper pulmonary veins (horizontal white arrows), implying the presence of the levoatriocardinal vein (black arrow). (c) Transvenous coil occlusion was performed through the left brachial vein using a coaxial delivery system (illustrated as a triple concentric circle in the right upper corner). (d) After the transvenous coaxial coil occlusion, the follow-up left subclavian venography showed complete occlusion of the levoatriocardinal vein

artery was 14 mm Hg. There was a pressure gradient of nearly 10 mm Hg between the left brachiocephalic vein (14 mm Hg) and the left atrium (4 mm Hg). After informed consent was obtained, transvenous coil occlusion was performed using a coaxial delivery system (Fig. 1c), which is composed of a 5-Fr right coronary Judkins catheter serving as an outer supportive catheter (denoted by the Arabic numeral 1 in a triple circle inserted in the right upper corner in Fig. 1c), a 2.9-Fr microcatheter (Progreat, TERUMO, Cottontail Lane, Somerset, New Jersey, USA) serving as a middle advancing catheter (Arabic numeral 2 in Fig. 1c), and a 0.018-inch micro-coil inserted as a central detachable vascular plug (Arabic numeral 3 in Fig. 1c). Through this coaxial delivery system, five sets of Tornado Embolization Coil (Cook, Daniels Way, Bloomington, IN, USA) and one set of Complex Helical Fibered Platinum Coil-18 (Boston Scientific, La Garenne Colombes, Cedex, France) were steadily deployed more distally at the anticipated location. After occlusion, left subclavian venography showed complete occlusion of LACV (Fig. 1d). Oxygen saturation of the ascending aorta increased to 98%. During the 24-month follow-up, oxygen desaturation and chest tightness did not recur.

## Discussion

BGS was performed to serve as an interim and staged palliation or as a component of definitive biventricular repair (one

and a half ventricle repair) for the young Fontan candidates (3, 4). Hemodynamically, BGS may serve as a “run-off” channel draining venous blood flow from the higher pressure caval venous system (being connected with the main pulmonary artery) to the lower pressure systemic venous system and reopen the systemic veins with time (3, 4). The incidence of such systemic venous collaterals was 31%–33% (3, 4) in children after the construction of BGS. In contrast, the incidence of such systemic venous collaterals reached up to 58% in adults with single ventricle physiology after Fontan operation (5). Transcatheter occlusion is safe and effective in ameliorating cyanosis and/or oxygen desaturation due to systemic venous collaterals after BGS (3, 4). There are two forms of systemic venous collaterals: those draining from the superior vena cava to the inferior vena cava are usually smaller in calibers (with mild oxygen desaturation) and can be left alone until the final completion of Fontan operation, and those draining from the superior vena cava to the pulmonary vein/atrium require occlusion (3). Transcatheter occlusion was performed in our patient to prevent the complications of a right-to-left shunt of this recanalized LACV. Because of the serpentine course of LACV in our patient, with many hairpin turns and branches draining into the bilateral pulmonary veins, transvenous coil occlusion was performed using a coaxial delivery system (6), which comprised a strong guiding catheter (in the outer layer) to prevent the rebound of coil and advancing catheter, a flexible advancing catheter (in the middle layer) to approach the lesion steadily, and a fibered micro-coil (in the central core) to occlude the anticipated lesion.

## Conclusion

LACV can be recanalized or reopened by gradational dilatation or bougination due to transpulmonary pressure gradient being harvested by BGS with time. Transvenous coaxial coil occlusion is an effective procedure in obliterating LACV,

despite its serpentine course with many hairpin turns and branches draining into the pulmonary veins.

## References

1. Edwards JE, DuShane JW. Thoracic venous anomalies. *Arch Pathol* 1950; 49: 517-37.
2. Bernstein HS, Moore P, Stanger P, Silverman NH. The levoatriocardinal vein: morphology and echocardiographic identification of the pulmonary-systemic connection. *J Am Coll Cardiol* 1995; 26: 995-1001.
3. Magee AG, McCrindle BW, Mawson J, Benson LN, Williams WG, Freedom RM. Systemic venous collateral development after the bidirectional cavopulmonary anastomosis. Prevalence and predictors. *J Am Coll Cardiol* 1998; 32: 502-8.
4. McElhinney DB, Reddy VM, Hanley FL, Moore P. Systemic venous collateral channels causing desaturation after bidirectional cavopulmonary anastomosis: evaluation and management. *J Am Coll Cardiol* 1997; 30: 817-24.
5. Lluri G, Levi DS, Aboulhosn J. Systemic to pulmonary venous collaterals in adults with single ventricle physiology after cavopulmonary palliation. *Int J Cardiol* 2015; 189: 159-63.
6. Lee ML, Chen M. Diagnosis and management of congenital coronary arteriovenous fistula in the pediatric patients presenting congestive heart failure and myocardial ischemia. *Yonsei Med J* 2009; 50: 95-104.

**Address for Correspondence:** Meng-Luen Lee, MD,

Division of Pediatric Cardiology,

Departments of Pediatrics,

Changhua Christian Hospital;

No. 135 Nanshiao Street 50050

Changhua- *Taiwan*

Phone: 886-4-7238595, Ext: 1902

E-mail: ferdielee@yahoo.com

©Copyright 2018 by Turkish Society of Cardiology - Available online at [www.anatoljcardiol.com](http://www.anatoljcardiol.com)

DOI: 10.14744/AnatolJCardiol.2018.50951

