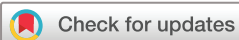

Histopathological profile of orbito-ocular cancers at a tertiary hospital in Northern Malawi: a retrospective cross-sectional study

Frank Watson Sinyiza ,¹ Master R O Chisale,² Alfred B Kayira,³ Chikondi Sharon Chimbatata,⁴ Paul Uchizi Kaseka,⁴ Pocha Kamudumuli,⁵ Tsung-Shu Joseph Wu,⁶ Balwani Chingatchifwe Mbakaya⁷

To cite: Sinyiza FW, Chisale MRO, Kayira AB, *et al*. Histopathological profile of orbito-ocular cancers at a tertiary hospital in Northern Malawi: a retrospective cross-sectional study. *BMJ Open Ophthalmology* 2022;**7**:e000977. doi:10.1136/bmjophth-2022-000977

Received 24 January 2022
Accepted 10 March 2022



© Author(s) (or their employer(s)) 2022. Re-use permitted under CC BY-NC. No commercial re-use. See rights and permissions. Published by BMJ.

¹Clinical Department, Mzuzu Central Hospital, Mzuzu, Malawi

²Biological Sciences, Mzuzu University, Mzuzu, Malawi

³Laboratory Department, Mzuzu Central Hospital, Mzuzu, Malawi

⁴Paediatric Department, Mzuzu Central Hospital, Mzuzu, Malawi

⁵Laboratory Department, University of Maryland and Global Initiative Corporation, Llongwe, Malawi

⁶Research Department, PingTung Christian Hospital, Ping Tung, Taiwan

⁷Department of Public Health, University of Livingstonia, Mzuzu, Malawi

Correspondence to

Dr Frank Watson Sinyiza;
frasinyiza@yahoo.com

ABSTRACT

Objective Orbito-ocular cancers are a common cause of morbidity and mortality in our population, yet these cancers have not been adequately described in Malawi. This study sought to describe the burden and histopathological profile of orbito-ocular cancers in Northern Malawi.

Methods and Analysis A retrospective review of pathology reports was done. Descriptive analyses were performed to summarise patients' demographic and clinical characteristics, and histopathological results. A binary logistic regression was used to explore the association between demographic variables, site of lesion and cancer.

Results 210 pathology reports of orbito-ocular biopsies were reviewed. 60.0% of patients were female. The majority (39.5%) of patients were in the 31 to 40 age group but overall mean age (\pm SD) was 34.81 ± 15.9 years. Cancer was diagnosed in 84 (40.0%) patients. Squamous cell carcinoma constituted the majority (82.1%) of cancers followed by retinoblastoma at 7.1%. Orbito-ocular cancers were associated with HIV infection (OR 5.9, 95% CI 2.0 to 17.2) and intraocular tumours were 8.3 times (OR 8.3, 95% CI 2.0 to 33.8) more likely to be malignant. However, squamous cell carcinoma was the only type of cancer found in patients with HIV infection and mostly affected the conjunctiva, constituting 94.4% of cancers affecting this site. Retinoblastoma on the other hand only affected children less than 10 years of age.

Conclusion Cancer constituted a substantial proportion of orbito-ocular lesions in our study population, with conjunctiva being the common site. This calls for improved capacity to prevent, diagnose and manage orbito-ocular cancers in Northern Malawi and similar settings.

BACKGROUND

Globally, it is estimated that at least 2.2 billion people have a vision impairment or blindness, of whom at least 1 billion have a vision impairment that could have been prevented or is yet to be addressed.¹ Visual impairment has an important economic cost implication and is associated with diminished quality of life.

Key messages

What is already known on this topic?

- ▶ Orbito-ocular cancers remain a major cause of mortality and morbidity worldwide but literature to comprehensively describe histopathological profile of these cancers in our population is lacking.
- ▶ Cancer of the eye has also been reported using data from national population-based cancer registry and not focusing on specifically on histopathological profile of orbito-ocular cancers.

What this study adds?

- ▶ Orbito-ocular cancers contribute a significant proportion of orbito-ocular lesions and squamous cell carcinoma was predominant in our study population.
- ▶ The study further revealed that HIV is an associated risk factor for orbito-ocular malignancy and intraocular lesions were 8.3 times more likely to be malignant.

How this study might affect research, practice or policy?

- ▶ The findings of this study call for policy-makers and other stakeholders to include orbito-ocular cancers among priority cancers in Malawi and devise appropriate strategies for prevention, early detection and management to reduce morbidity and mortality.

Orbito-ocular tumours cause significant morbidity and mortality in our population with varying incidence, site distribution and pathological profiles globally and regionally. In a retrospective study involving 115 cases conducted in Nepal demonstrated that tumours were predominantly malignant (58.25%, (n=67)) with bimodal distribution first, peak age less than 5 years and second peak 40–50 years and basal cell carcinoma was the most common histological findings.² This is in contrast to several studies conducted in West Africa and Taiwan where squamous cell carcinoma and melanoma respectively were the most common malignant tumours in

adults.^{3–5} Most of the common benign tumours reported in many studies are conjunctival papilloma, dermoid cysts, nevus, cystic lesions, haemangiomas.^{2,5} Studies have reported variation in common sites for orbito-ocular tumour however conjunctiva and eyelids are among the most common sites.^{2,6}

Histopathology remains a gold standard for diagnosing orbito-ocular lesions. In addition, histology reveals whether the lesion is malignant or not. Patients with orbito-ocular lesions are usually referred from secondary level of care to tertiary facilities for diagnosis and management. However, in Malawi, like in many low-income countries, histopathological services are limited contributing to delay in making definitive diagnosis and initiation of treatment. As such histopathological pattern of orbito-ocular lesions may help to guide in developing effective preventive, diagnostic and management strategy.

In Malawi particularly in northern region, there is paucity of data on orbito-ocular cancers which can best describe our situation and guide in developing effective preventive, diagnostic and management strategy. Therefore, this study was instituted in order to describe the burden and histopathological pattern of orbito-ocular cancers at Mzuzu Central Hospital (MCH) in Malawi.

MATERIALS AND METHODS

Design, setting and population

This was a record based retrospective cross-sectional study conducted at MCH, which is the only tertiary facility located in northern part of Malawi, catering for a population of about 2 289 780 million people.⁷ We carried out a retrospective review of 210 histopathological results of orbito-ocular specimens from July 2013 to June 2018. Relevant information such as sex, age, race, clinical and histological diagnosis were extracted from original biopsy reports. All patients' records with missing demographic, clinical and histopathological data and those with inconclusive results were excluded.

Specimen collection and processing

Tissue specimens were collected and preserved in 10% buffered formalin solution and then transported to Kamuzu Central Hospital/University of North Carolina (KCH/UNC) pathology laboratory in Lilongwe—Malawi. The KCH/UNC laboratory adheres to international quality assurance standards. [Figure 1](#) is a flow diagram showing the process involved in the processing and examining of the specimens to make histopathological diagnosis.

Data analysis

Data were entered in Microsoft excel 2016, validated and cleaned before importing into Stata, V.13.0 (Stata) for analysis. Descriptive analyses were performed to summarise patient's sociodemographic and clinical characteristics, and histological findings. A binary logistic regression was used to explain the relationship between

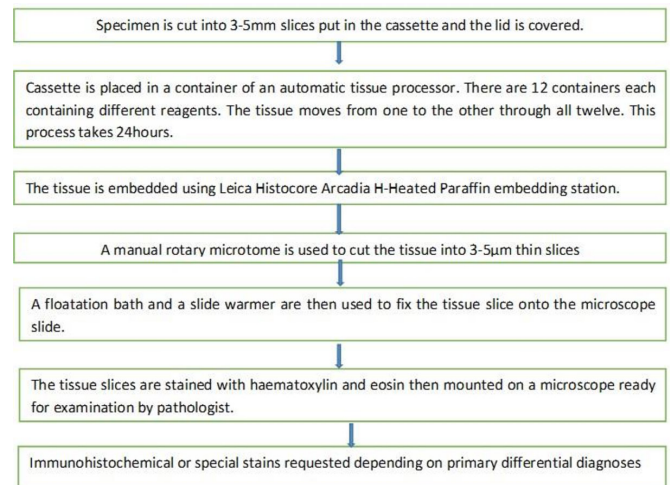


Figure 1 Processes involved in specimen processing at KCH/UNC laboratory. KCH/UNC, Kamuzu Central Hospital/University of North Carolina.

orbito-ocular cancers and demographic factors and site of lesion.

RESULTS

A total of 210 orbito-ocular biopsy specimens from 210 patients were analysed. One hundred and twenty six (60.0%) of these were female. The majority (39.5%) of patients were in the 31–40 age group but the overall mean (\pm SD) age was 34.8 ± 15.9 years. 17.6% of patients were HIV positive while the HIV status of 59.5% of patients was unknown or undocumented. The majority (63.8%) of biopsy specimens were taken from the conjunctiva followed by the eyelid/adnexa at a distant 13.3%. Cancer was diagnosed in 84 (40.0%) patients. Among the 84 cases of cancer, squamous cell carcinoma constituted the majority (82.1%) of malignant lesions, followed by retinoblastoma at 7.1% [table 1](#).

In a multivariable logistic regression analysis orbito-ocular cancers were significantly associated with HIV sero status and site of lesion. HIV positive patients were 5.9 times (OR 5.9, 95% CI 2.0 to 17.2) more likely to have cancer than their HIV negative counterparts while intra-ocular tumours were 8.3 times (OR 8.3, 95% CI 2.0 to 33.8) more likely to be malignant than tumours affecting the eyelid/adnexa. Although the association between orbito-ocular cancers and age was not statistically significant the trend seems to suggest that the incidence of cancer increases with increasing age [table 2](#).

Squamous cell carcinoma was the only type of cancer found in HIV positive patients while retinoblastoma was only found in children less than 10 years of age and constituted the majority (50%) of cancers diagnosed in this age group. Even though squamous cell carcinoma affected every other orbito-ocular site, it mostly affected the conjunctiva and was responsible for 94.4% of all malignant lesions affecting this site [table 3](#).

Table 1 Demographic characteristics of patients and histology findings of the biopsies analysed

Variable		Frequency (%)
Sex	Female	126 (60.0)
	Male	84 (40.0)
Age (years)	0–10	22 (10.5)
	11–20	9 (4.3)
	21–30	38 (18.1)
	31–40	64 (30.5)
	41–50	48 (22.9)
	51–60	18 (8.6)
	61–70	6 (2.9)
	>70	2 (1.0)
	Missing	3 (1.4)
HIV status	Negative	48 (22.9)
	Positive	37 (17.6)
	Unknown/undocumented	125 (59.5)
Site of biopsy	Eyelid/adnexa	28 (13.3)
	Conjunctiva	134 (63.8)
	Intraocular	25 (11.9)
	Unspecified	23 (10.9)
Histology findings	Cancer	84 (40.0)
	No cancer	126 (60.0)
Histological types of cancer (n=84)	Squamous cell carcinoma	69 (82.1)
	Retinoblastoma	6 (7.1)
	Kaposi sarcoma	2 (2.4)
	Small B cell lymphoma	1 (1.2)
	Other invasive carcinomas	6 (7.1)

Mean age—34.81±15.9 years, range: 4 months to 91 years.

DISCUSSION

We conducted a retrospective review of pathology reports of orbito-ocular biopsies. The incidence of orbito-ocular cancers was 40%. In studies done elsewhere the incidence of orbito-ocular cancers varies from 31.1%⁸ to 79.7%,⁹ which is a considerably high burden. Despite this high burden, orbito-ocular cancers are not among the priority cancers in our setting. In Malawi, cancer control efforts are focused on Cervical cancer, breast cancer, oesophageal cancer, Kaposi sarcoma and Non-Hodgkin's lymphoma.¹⁰ This call for policy-makers to include orbito-ocular cancer among priority cancers, create awareness and provide tailored control and prevention measures. These interventions would help to detect orbito-ocular cancers in their early stages, when treatment is less complex, more affordable and generally more effective resulting in high cure rates or increased survival with good quality of life.

We found that the most common malignancy seen in orbito-ocular biopsy specimens was squamous cell carcinoma (82.1%), followed by retinoblastoma (7.1%).

This result is similar to what has been reported by other studies in Nigeria,^{4 6 11} implying that squamous cell carcinoma is the most common type of malignancy affecting orbito-ocular tissues. However, data of cancer registry among Chinese, the common malignancies were retinoblastoma (35.3%), melanoma (17.9%) and lymphoma (13.8%).³ There is strong epidemiological evidence that solar ultraviolet radiation is a risk factor for squamous cell carcinoma of conjunctiva.^{12–14} Therefore, predominance of squamous cell carcinoma in our study may be attributed to overexposure to Africa's excessive sunlight. We recommend that people should be advised to wear sun protectors such as ultraviolet protection sunglasses or sun protection hats when outdoors in strong sunlight. Further, global efforts to mitigate climate change have to be reinforced so as to prevent continued depletion of the UV-protective ozone layer which may have serious implications on orbito-ocular cancers.

Lymphomas were rare in our study which is in keeping with other studies where lymphomas including Burkitt's lymphoma were uncommon, contributing about 8.1% (3/37) of orbital and eye lid tumours.⁴ Likewise ocular melanoma, for instance, is the second most common type of melanoma after cutaneous melanoma and most common primary intraocular tumour in adults.¹⁵ Malignant uveal melanoma is also commonly reported among Caucasians and in our study, which involved black Africans, did not find any of these, affirming previous findings that malignant melanoma is rare in Africans as compared with Caucasians.^{4 15–17}

About two-thirds (54/84) of cancers were found to be on the conjunctiva. This may be due to the fact that the majority (63.8% (134/210)) of specimens analysed were conjunctival biopsies. This is consistent with findings from other studies which reported up to 45.3% (4) and 45.7%¹⁸ of orbito-ocular specimens were from conjunctiva. This suggests that orbito-ocular tumours affect the conjunctiva more than any other orbito-ocular tissues. However, intraocular tumours were more likely to be malignant than tumours affecting other orbito-ocular sites. A multivariable logistic regression showed that intraocular tumours were 8.3 times more likely to be malignant than tumours affecting the eyelid/adnexa or conjunctiva. Other studies have reported similar results where all intraocular tumours (100% (26/26)) turned to be malignant.² Therefore, patients presenting with intraocular lesions should be investigated thoroughly to rule out malignancy.

From this study, 67.6% (25/37) of HIV-infected patients had malignant lesions compared with 22.9% (11/48) of those who were HIV negative. A logistic regression analysis demonstrated that HIV positive patients were 5.9 times more likely to have orbito-ocular cancer than HIV negative counterparts. This implies that HIV is an associated risk factor for orbito-ocular malignancy. Our finding is consistent with findings of other studies which have attributed the rising incidence of orbito-ocular tumours, especially conjunctival squamous cell carcinoma, to high

Table 2 Association between orbito-ocular cancers and demographic variables and site of lesion

Variable		Cancer (%)	No cancer (%)	Unadjusted OR (95% CI)*	Adjusted OR (95% CI)†
Sex	Female	45 (35.7)	81 (64.3)	–	–
	Male	39 (46.4)	45 (53.6)	1.6 (0.8 to 2.7)	1.5 (0.7 to 2.8)
Age (years)	0–10 (reference)	10 (45.5)	12 (54.5)	–	–
	11–20	1 (11.1)	8 (88.9)	0.2 (0.0 to 1.4)	0.2 (0.0 to 2.2)
	21–30	10 (26.3)	28 (73.7)	0.4 (0.1 to 1.3)	0.7 (0.2 to 2.7)
	31–40	29 (45.3)	35 (54.7)	1.0 (0.4 to 2.6)	1.5 (0.4 to 5.3)
	41–50	27 (56.3)	21 (43.7)	1.5 (0.6 to 4.3)	1.9 (0.5 to 6.7)
	51–60	4 (22.2)	14 (77.8)	0.3 (0.1 to 1.4)	0.3 (0.1 to 1.6)
	61–70	1 (16.7)	5 (83.3)	0.2 (0.0 to 2.4)	0.7 (0.1 to 7.8)
	>70	1 (50.0)	1 (50.0)	1.2 (0.1 to 21.7)	1.1 (0.0 to 39.9)
HIV status	Negative (reference)	11 (22.9)	37 (78.1)	–	–
	Positive	25 (67.6)	12 (32.4)	7.0 (2.7 to 18.4)	5.9 (2.0 to 17.2)
	Unknown	48 (38.4)	77 (61.6)	2.1 (0.9 to 4.5)	1.9 (0.8 to 4.6)
Site	Eye lid/adnexa (reference)	6 (21.4)	22 (78.6)	–	–
	Conjunctiva	54 (40.3)	80 (59.7)	2.5 (0.9 to 6.5)	1.9 (0.6 to 5.4)
	Intraocular	18 (72.0)	7 (28.0)	9.4 (2.7 to 33.1)	8.3 (2.0 to 33.8)
	Not specified	6 (26.1)	17 (73.9)	1.3 (0.4 to 4.7)	0.7 (0.2 to 2.9)

*Univariable binary logistic regression.

†Multivariable binary logistic regression, adjusting for all other variables in the table.

rate of HIV infection.^{19 20} It is therefore imperative that patients presenting with orbito-ocular lesions should be screened for HIV as part of routine care for proper management and timely initiation of antiretroviral

therapy (ART). On the other hand, controlling HIV would reduce the incidence of orbito-ocular cancers.

Although the association between orbito-ocular cancers and age was not statistically significant the trend

Table 3 Stratified analysis of type of cancer by demographic characteristics and site of lesion

Demographic variables		Type of cancer					Total (%)
		Squamous cell carcinoma (%)	Retinoblastoma (%)	Kaposi sarcoma (%)	Small B cell lymphoma (%)	Other invasive carcinomas (%)	
Sex	Female	36 (80.0)	3 (6.7)	1 (2.2)	1 (2.2)	4 (8.9)	45 (100)
	Male	33 (84.6)	3 (7.7)	1 (2.6)	0 (0.0)	2 (5.1)	39 (100)
Age (years)	0–10	4 (40.0)	5 (50.0)	1 (10.0)	0 (0.0)	0 (0.0)	10 (100)
	11–20	0 (0.0)	0 (0.0)	0 (0.0)	0 (0.0)	1 (100)	1 (100)
	21–30	9 (90.0)	0 (0.0)	0 (0.0)	0 (0.0)	1 (10.0)	10 (100)
	31–40	25 (86.2)	0 (0.0)	1 (3.5)	0 (0.0)	3 (10.3)	29 (100)
	41–50	26 (96.3)	0 (0.0)	0 (0.0)	0 (0.0)	1 (3.7)	27 (100)
	51–60	3 (75.0)	0 (0.0)	0 (0.0)	1 (25.0)	0 (0.0)	4 (100)
	61–70	1 (100)	0 (0.0)	0 (0.0)	0 (0.0)	0 (0.0)	1 (100)
	>70	1 (100)	0 (0.0)	0 (0.0)	0 (0.0)	0 (0.0)	1 (100)
HIV status	Negative	9 (81.8)	1 (9.1)	0 (0.0)	1 (9.1)	0 (0.0)	11 (100)
	Positive	25 (100)	0 (0.0)	0 (0.0)	0 (0.0)	0 (0.0)	25 (100)
	Unknown	35 (72.9)	5 (10.4)	2 (4.2)	0 (0.0)	6 (12.5)	48 (100)
Site of lesion	Eye lid/adnexa	4 (66.7)	0 (0.0)	1 (16.7)	1 (16.7)	0 (0.0)	6 (100)
	Conjunctiva	51 (94.4)	0 (0.0)	1 (1.9)	0 (0.0)	2 (3.7)	54 (100)
	Intraocular	10 (55.6)	5 (27.8)	0 (0.0)	0 (0.0)	3 (16.7)	18 (100)
	Not specified	4 (66.7)	1 (16.7)	0 (0.0)	0 (0.0)	1 (16.7)	6 (100)

seems to suggest that the incidence of cancer increases with increasing age. Perhaps the statistical significance could not be demonstrated because orbito-ocular cancers seemed to follow a bimodal distribution, with the first peak in the first decade of life and the second and third peaks in the fourth and fifth decades of life, respectively. Studies elsewhere have demonstrated bimodal distribution of malignant tumours—first decade and fifth decade.^{2,21} The association between sex and cancer was also not statistically significant this is in keeping with other studies conducted elsewhere which shows that there is no significant difference in the sex distribution of cancers.²² Although other studies have reported that men are at greater risk of ocular cancer compared with women.^{4,9} This increased risk is attributed to the amount of time spent in direct sunlight. Due to their nature of jobs and lifestyle men spend more time in direct sunlight outdoors and exposed to harmful effects of ultraviolet radiation.¹²

We observed that squamous cell carcinoma was the only type of cancer found in HIV positive patients and mostly affected the conjunctiva. It accounted for 94.4% of all cancers affecting the conjunctiva. This is in keeping with studies conducted elsewhere which showed that Squamous cell carcinoma is a common cancer affecting conjunctiva and HIV is an established risk factor for squamous cell carcinoma.^{12–14, 23} Clinicians should therefore put their suspicion on squamous cell carcinoma whenever they see a patient presenting with a conjunctival lesion and must try to immediately establish their HIV status so that those who turn out to be HIV positive can be promptly initiated on ART.

Retinoblastoma was the most common malignancy in children and constituted 50% of all cancers affecting children less than 10 years of age. This is in tandem with other studies which have demonstrated that worldwide retinoblastoma is the most common primary intraocular tumour in children.^{4, 24} Studies have shown that delayed presentation of patients with retinoblastoma due to lack of awareness and inaccessibility to proper medical facility at primary and secondary levels of healthcare were major impediments in achieving high cure rate.²⁵ Therefore, improving awareness among health workers about clinical features such as leukocoria and strabismus with prompt referral may reduce morbidity and mortality, and lead to improved outcome.

Although our study did not find any adult case of retinoblastoma, cases of adult onset retinoblastoma have been reported elsewhere.^{8, 26} Therefore, clinicians must still be suspicious of retinoblastoma if an adult patient presents with a white mass lesion of unknown aetiology.

Much as some studies have demonstrated Kaposi sarcoma is a common malignant lesion in patients with advanced HIV disease, our findings are similar to other studies which found that Kaposi sarcoma was rare.^{4, 17} This may be due to limited laboratory capacity therefore clinicians rely on clinical diagnosis. Likewise prompt initiation of ART in our set up which is of paramount

importance in preventing advanced HIV disease and management of Kaposi sarcoma hence we did not find any case Kaposi Sarcoma among HIV infected patients in our study.

CONCLUSION

Cancer constituted a substantial proportion of orbito-ocular lesions in our study population, with squamous cell carcinoma being the most common malignancy in adults and retinoblastoma in children. We, therefore, call on policy-makers and other stakeholders to include orbito-ocular cancers among priority cancers in Malawi and devise appropriate strategies for prevention, early detection and management to reduce morbidity and mortality.

Limitations

This was a record based retrospective cross-sectional study, as such some clinical data which would have helped us to arrive at more meaningful conclusions were missing.

Acknowledgements We thank management and staff of Mzuzu Central Hospital for allowing us to use medical records, Pingtung Christian Hospital through Luke International Norway (LIN) for financial support, Dr Manduwa Saka and Mr Rashid Kaseka for their role in data collection.

Contributors All the authors contributed adequately towards study conception, study design, data collection and analysis and manuscript preparation. Their career background played important roles. All authors read and approved the manuscript. FWS is responsible for the overall content as the guarantor.

Funding Pingtung Christian Hospital, Taiwan through Luke International Norway (LIN), Malawi, Grant Number: PS-IR-108001.

Competing interests None declared.

Patient consent for publication Not applicable.

Ethics approval Ethical approval to conduct the study was sought from National Health Sciences Research Committee (NHSRC) approval number 19/05/2316 and clearance was also obtained from Mzuzu Central Hospital authorities. All particulars that would link the information obtained to the identity of the patient such as name and surname were deliberately not captured to ensure privacy and confidentiality.

Provenance and peer review Not commissioned; externally peer reviewed.

Data availability statement Data are available on reasonable request. All data relevant to the study are included in the article. Data can be requested from the corresponding author using the following contacts: frasinyinza@yahoo.com

Open access This is an open access article distributed in accordance with the Creative Commons Attribution Non Commercial (CC BY-NC 4.0) license, which permits others to distribute, remix, adapt, build upon this work non-commercially, and license their derivative works on different terms, provided the original work is properly cited, appropriate credit is given, any changes made indicated, and the use is non-commercial. See: <http://creativecommons.org/licenses/by-nc/4.0/>.

ORCID iD

Frank Watson Sinyiza <http://orcid.org/0000-0002-5009-4012>

REFERENCES

- 1 World Health Organisation. Blindness and vision impairment. key facts. Available: <https://www.who.int/blindness> [Accessed 23 Nov 2021].
- 2 Lavaju P, Arya SK, Sinha A, *et al*. Pattern of ocular tumors in the eastern region of Nepal. *Nepal J Ophthalmol* 2009;1:9–12.
- 3 Cheng C-Y, Hsu W-M. Incidence of eye cancer in Taiwan: an 18-year review. *Eye* 2004;18:152–8.
- 4 Aghogho Akpe B, Ernest Omoti A, Temitope Iyasele E. Histopathology of ocular tumor specimens in Benin City, Nigeria. *J Ophthalmic Vis Res* 2009;4:232–7.



- 5 Odunfa AO, Odunfa AO, Ayeni AO. Orbito-ocular lesions in Sagamu, Nigeria. *J Bio Innov* 2017;6:159–64.
- 6 Silas O, Ajetunmobi O, Enwereuzo C. A descriptive study of patterns of conjunctival lesions in Jos, Nigeria: a 10-year retrospective study. *Ann Trop Pathol* 2017;8:39–41.
- 7 National Statistical Office. Malawi population and census, 2018. Available: <https://malawi.unfpa.org> [Accessed 15 Nov 2021].
- 8 Gupta Y, Gahine R, Hussain N, et al. Clinico-Pathological spectrum of ophthalmic lesions: an experience in tertiary care hospital of central India. *J Clin Diagn Res* 2017;11:9–13.
- 9 Umar A, Ochicha O, Iliyasu Y. A pathologic review of ophthalmic tumors in Kano, Northern Nigeria. *Nigerian Journal of Basic and Clinical Sciences* 2012;9:23–6.
- 10 Government of the republic of Malawi, Ministry of Health and Population. National cancer control strategic plan 2019–2029.
- 11 Onwubuya IM, Owoyele TM, Olaofe OO. *Morphological spectrum of Orbito-ocular diseases in a tertiary health centre in Keffi, North central Nigeria*. Hindawi Publishing Corporation Advances in Medicine, 2015: 1–5.
- 12 Newton R, Ziegler J, Ateenyi-Agaba C, et al. The epidemiology of conjunctival squamous cell carcinoma in Uganda. *Br J Cancer* 2002;87:301–8.
- 13 McKelvie PA, Daniell M, McNab A, et al. Squamous cell carcinoma of the conjunctiva: a series of 26 cases. *Br J Ophthalmol* 2002;86:168–73.
- 14 Tulvatana W, Bhattacharjee H, Sansopha L, et al. Risk factors for conjunctival squamous cell neoplasia: a matched case-control study. *Br J Ophthalmol* 2003;87:396–8.
- 15 Jovanovic P, Mihajlovic M, Djordjevic-Jocic J, et al. Ocular melanoma: an overview of the current status. *Int J Clin Exp Pathol* 2013;6:1230–44.
- 16 Bekibele CO, Oluwasola AO. A clinicopathological study of orbito-ocular diseases in Ibadan between 1991–1999. *Afr J Med Med Sci* 2003;32:197–202.
- 17 Ajaiyeoba IA, Pindiga HU, Akang EE. Tumours of the eye and orbit in Ibadan. *East Afr Med J* 1992;69:487–9.
- 18 Charles N, James E. A study of the histopathologic pattern of orbito-ocular disease in a tertiary hospital in Nigeria. *Sahel Medical Journal* 2014;17:60–4.
- 19 Nagaiah G, Stotler C, Orem J, et al. Ocular surface squamous neoplasia in patients with HIV infection in sub-Saharan Africa. *Curr Opin Oncol* 2010;22:437–42.
- 20 Nkomazana O, Tshitswana D. Ocular complications of HIV infection in sub-Saharan Africa. *Curr HIV/AIDS Rep* 2008;5:120–5.
- 21 Habib SG, Lawan A, Victoria P. Clinicopathologic presentation of malignant orbito-ocular tumors in Kano, Nigeria: a prospective multicenter study. *Ann Afr Med* 2019;18:86–91.
- 22 Mohammed A, Ahmed SA, Ahmedu NE. Orbito-Ocular malignant tumours in Zaria, Nigeria: a 10-year review. *Annals of African Medicine* 2006;5:129–31.
- 23 Karcioğlu ZA, Wagoner MD. Demographics, etiology, and behavior of conjunctival squamous cell carcinoma in the 21st century. *Ophthalmology* 2009;116:2045–6.
- 24 Eagle RC. The pathology of ocular cancer. *Eye* 2013;27:128–36.
- 25 Chawla B, Hasan F, Azad R, et al. Clinical presentation and survival of retinoblastoma in Indian children. *Br J Ophthalmol* 2016;100:172–8.
- 26 Singh SK, Das D, Bhattacharjee H, et al. A rare case of adult onset retinoblastoma. *Oman J Ophthalmol* 2011;4:25–7.