

An unusual presentation of metastatic bone disease in a subject with Paget's disease of bone

Shrinath Shetty¹, Sahana Shetty¹, Annie Jennifer Prabhu², Nitin Kapoor¹, Julie Hepzibah³, Thomas Vizhalil Paul¹

Departments of ¹Endocrinology, Diabetes and Metabolism, ²General Pathology and ³Nuclear Medicine, Christian Medical College, Vellore, Tamil Nadu, India

ABSTRACT

Solid organ malignancies involving breast, prostate, and lung frequently metastasize to the skeleton. However, the occurrence of Paget's disease and metastatic bone disease in the same patient is uncommon. We report a case of a 63-year-old man who presented with back pain and a lump in the right breast. He was earlier diagnosed to have Paget's disease of bone based on characteristic skeletal radiological features, ^{99m}Tc methylene diphosphonate bone scan and elevated alkaline phosphatase, and treated with bisphosphonates, and his disease was in remission. Further evaluation revealed an underlying skeletal metastatic disease secondary to a breast malignancy. He underwent radical mastectomy with axillary node clearance, radiotherapy, and chemotherapy. In addition, he also received parenteral bisphosphonates for his skeletal metastatic bone disease.

Keywords: ^{99m}Tc methylene diphosphonate bone scan, breast cancer, low back pain, Paget's disease

Introduction

Paget's disease of the bone (PDB) is a metabolic bone disease which usually presents after fourth decade and affects bone remodeling, which is characterized by excessive bone resorption followed by increased bone formation.^[1] PDB could involve single bone (monostotic) or multiple bones which is called polyostotic Paget's disease. Altered bone remodeling leads to a disorganized mosaic bone (woven bone), which is structurally weaker and susceptible to fracture.^[2] The diagnosis of Paget's disease require a high index of suspicion and conditions which could cause sclerosis of the bone like metastasis from solid tumors like breast, prostate and lung need to be excluded.^[3] The bisphosphonate therapy remains a main line of therapy with which many subjects will experience remission.^[1] However, when there is recurrence of symptom profile, a re-evaluation to rule out other causes such as metastases has to be done.

Address for correspondence: Dr. Thomas Vizhalil Paul, Department of Endocrinology, Diabetes and Metabolism, Christian Medical College, Vellore - 632 004, Tamil Nadu, India. E-mail: thomasvpaul@yahoo.com

Case Report

A 59-year-old gentleman presented in March 2008 with mechanical back pain of 6 months duration. There was no history of trauma, fracture, or other systemic symptoms. There was a similar history in an elder sibling (sister) who was diagnosed to have Paget's disease.

On examination, there was macrocephaly with a head circumference of 62 cm and there were no deformities. Rest of the examination was unremarkable. Skeletal survey revealed diffuse sclerotic and lytic lesions of pelvis and skull [Figure 1].

His hemogram and renal parameters were normal. His evaluation for myeloma and prostate malignancy was negative. His biochemical investigations at baseline and after 3 years of treatment with bisphosphonates (parenteral zoledronic acid) are shown in Table 1.

This is an open access article distributed under the terms of the Creative Commons Attribution-NonCommercial-ShareAlike 3.0 License, which allows others to remix, tweak, and build upon the work non-commercially, as long as the author is credited and the new creations are licensed under the identical terms.

For reprints contact: reprints@medknow.com

How to cite this article: Shetty S, Shetty S, Prabhu AJ, Kapoor N, Hepzibah J, Paul TV. An unusual presentation of metastatic bone disease in a subject with Paget's disease of bone. J Family Med Prim Care 2016;5:488-90.

Access this article online

Quick Response Code:



Website:
www.jfmpc.com

DOI:
10.4103/2249-4863.192326

A ^{99m}Tc methylene diphosphonate (MDP) bone scan showed an abnormal tracer uptake in the skull, lower lumbosacral vertebrae, bilateral pelvic bones, and upper half of femur on both sides, suggestive of polyostotic Paget's disease [Figure 2a].

The patient was treated with parenteral bisphosphonates (zoledronic acid) yearly with which he symptomatically improved. His alkaline phosphatase on follow-up after 3 years was 123 U/L [Table 1]. In addition, a repeat ^{99m}Tc MDP bone scan showed marked regression of Paget's disease [Figure 2b].

However, after 4 years of initial diagnosis, he presented again with mechanical back pain of 1 month duration. His examination revealed a mass in the right breast, which measured 3 cm × 3 cm, was irregular shaped, and hard in consistency. There were no palpable axillary lymph nodes and rest of the physical examination was within normal limits. A ^{99m}Tc MDP bone scan was done at this presentation, which showed multiple

metastatic lesions involving the lumbar vertebra, skull, and pelvic bone [Figure 2c].

He underwent a modified radical mastectomy, which confirmed the diagnosis of carcinoma of the breast, histopathology of which is shown in Figure 3. The tumor cells were negative for estrogen/progesterone receptors on immunohistochemistry. The patient was subsequently treated with palliative chemotherapy with docetaxel, adriamycin, and cyclophosphamide regimen. He was also given local radiotherapy and was restarted on parenteral bisphosphonates in view of metastatic bone disease.

Discussion

PDB is a metabolic bone disease affecting bone remodeling, characterized by a high osteoclastic activity followed by compensatory increased osteoblastic activity. However, the new bone formation is in a disorganized mosaic fashion comprising woven and lamellar bone. This results in an expanded, less compact, more vascular fragile bone susceptible to fracture.^[1] Paget's disease can occur in families, where it may

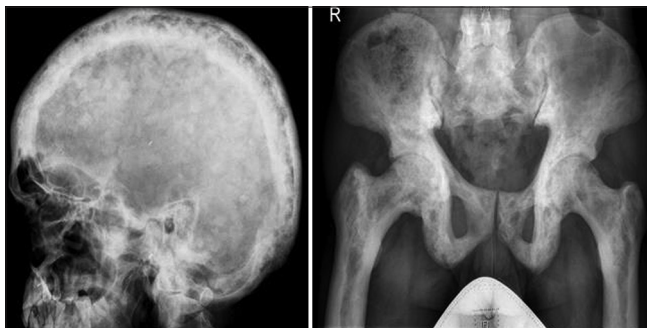

Figure 1: X-ray showing the sclerotic bony involvement of skull and pelvis in Paget's disease

Table 1: Biochemical parameters of a 59-year-old man who presented with back pain and diagnosed to have Paget's disease before and 3 years after treatment with zoledronic acid

Biochemical parameters	Before treatment	After treatment	Units	Normal range
Serum alkaline phosphatase	1003	123	U/L	40-125
Albumin corrected calcium	9.3	9.1	mg/dl	8.3-10.4
Creatinine	0.79	0.80	mg/dl	0.7-1.4
25 hydroxy Vitamin D	32	-	ng/ml	30-75

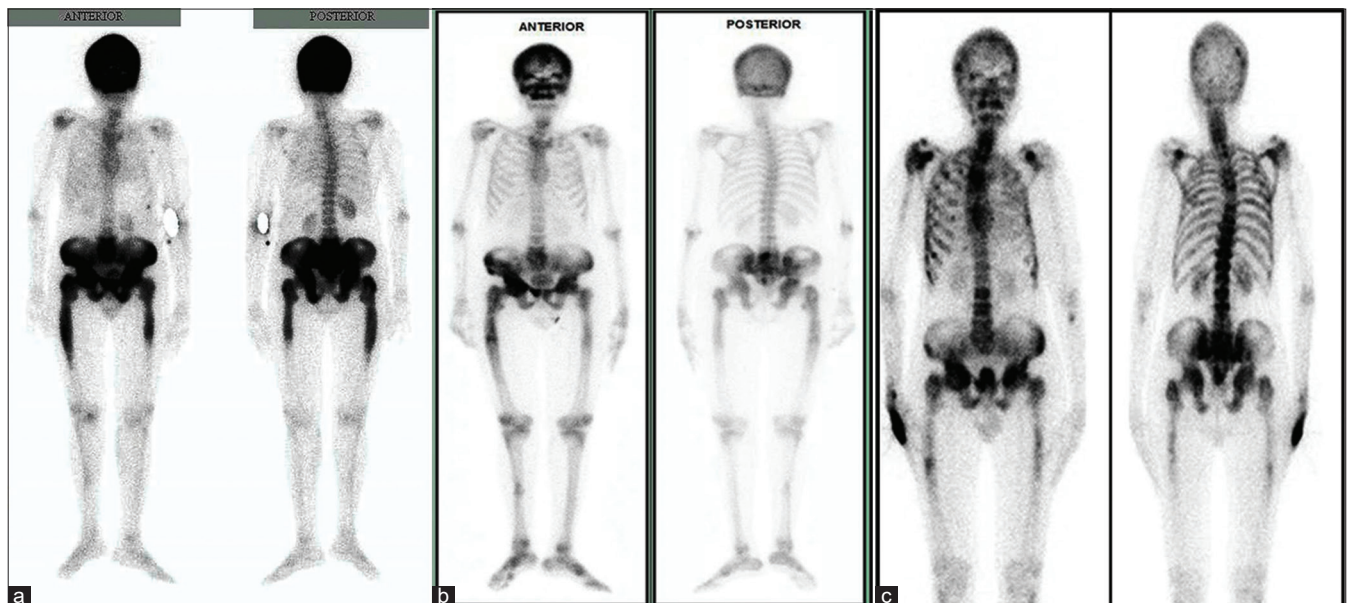


Figure 2: (a) ^{99m}Tc methylene diphosphonate bone scan showing intense sclerotic tracer uptake in the skull, lower lumbosacral vertebrae, bilateral pelvic bones, and upper half of femur on both sides, suggestive of polyostotic Paget's disease. (b) ^{99m}Tc methylene diphosphonate bone scan displaying a marked reduction in the previously intense tracer uptake, suggestive of regression of the Paget's disease. (c) ^{99m}Tc methylene diphosphonate bone scan shows asymmetrical spotty uptake in the lumbar vertebra, skull, and pelvic bones suggestive of bony metastasis

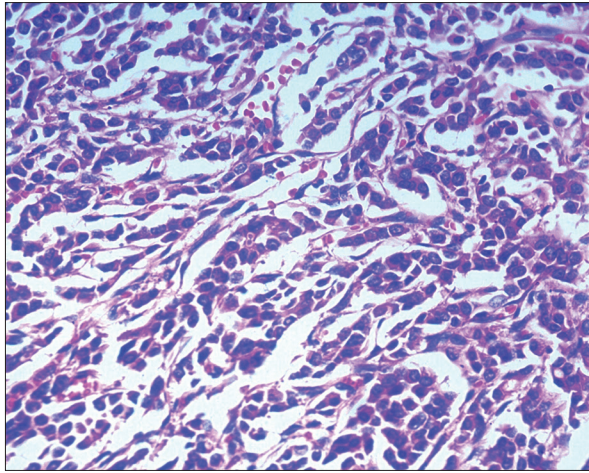


Figure 3: Histopathology of the breast showing cords and tubules of invasive tumor cells

have an autosomal dominant pattern of inheritance as also seen in the case presented. A positive family history may be seen in 15–30% of these patients.^[4]

Although bone pain is the most common presenting symptom, some patients may be asymptomatic at presentation where the disease is detected incidentally due to a raised serum alkaline phosphatase. Such patients may also present with pathological fractures or with hearing difficulties. Others may present as deformities, high output heart failure, arthritis, and headache.^[5]

Paget disease has a strong predilection for the skull, thoracolumbar spine, pelvis, and long bones of the lower extremities. Laboratory manifestations are suggestive of increased bone turnover and markers of bone turnover are often elevated with active disease. The treatment of choice is bisphosphonates, oral or intravenous, which inhibits the osteoclastic activity.^[1] Paget's disease, has a <1% risk of transformation into osteosarcoma of the bone.^[6] However, patients with Paget's disease presenting subsequently with bony metastasis is rarely reported.^[7]

In our patient, skeletal metastasis secondary to carcinoma breast was the cause of recent onset low back pain following remission of Paget's disease. Among the previously published cases, the primary sites of malignancy in patients with Paget's disease were the breast, lung, and prostate.^[7-9]

Mechanical back pain due to bony metastasis may be falsely attributed to Paget's disease, unless a high index of suspicion is kept.^[8] A ^{99m}Tc MDP bone scan may be useful in differentiating the etiology of low back pain, when diagnosis is questionable. In Paget's disease, the tracer uptake is intense, symmetrical, and well demarcated. In contrast, metastatic disease may present with asymmetrical and spotty uptake. This case highlights the importance considering differential diagnosis in patients who present with mechanical back pain, even in patients with metabolic bone disease such as Paget's disease.^[10]

These findings are useful in guiding the treating physician in choosing the appropriate treatment in these doubtful cases. However, if there is an associated malignancy presenting at the same time, it may be difficult to distinguish Paget's disease from a metastasis, and then a bone biopsy may be essential for establishment of the diagnosis.

Conclusion

Back pain in middle-aged and elderly people needs evaluation to rule out rare causes such as Paget's disease and myeloma. In the background of diseases such as PDB, persistence or relapse of pain may warrant further work up to diagnose the conditions such as bony metastases from solid organs such as prostate, lung, and breast.

Acknowledgment

We acknowledge the contribution of Prof. Aravindan Nair in the surgical management of this patient.

Financial support and sponsorship

Nil.

Conflicts of interest

There are no conflicts of interest.

References

1. Kanis JA. Pathophysiology and Treatment of Paget's Disease of Bone. 2nd ed. London: Martin Dunitz Ltd.; 1998.
2. Shetty S, Kapoor N, Prabhu AJ, Paul TV. Paget's disease: A unique case snippet. *BMJ Case Rep* 2014;2014. pii: Bcr2013202955.
3. Rybak LD, Rosenthal DI. Radiological imaging for the diagnosis of bone metastases. *Q J Nucl Med* 2001;45:53-64.
4. Leach RJ, Singer FR, Roodman GD. The genetics of Paget's disease of the bone. *J Clin Endocrinol Metab* 2001;86:24-8.
5. Cundy T, Reid IR. Paget's disease of bone. *Clin Biochem* 2012;45:43-8.
6. Wick MR, Siegal GP, Unni KK, McLeod RA, Greditzer HG 3rd. Sarcomas of bone complicating osteitis deformans (Paget's disease): Fifty years' experience. *Am J Surg Pathol* 1981;5:47-59.
7. Ilincic B, Crnobrnja V, Mijovic R, Zeravica R, Jakovljevic A, Kadic V. Polyostotic Paget's disease of bone: Diagnostic dilemma in detection of bone metastases from prostate cancer. *Med Pregl* 2012;65:337-40.
8. Roberts JA. Paget's disease and metastatic carcinoma. A case report. *J Bone Joint Surg Br* 1986;68:22-3.
9. Kelly T, Suva LJ, Huang Y, Macleod V, Miao HQ, Walker RC, *et al.* Expression of heparanase by primary breast tumors promotes bone resorption in the absence of detectable bone metastases. *Cancer Res* 2005;65:5778-84.
10. Sonoda LI, Balan KK. Co-existent Paget's disease of the bone, prostate carcinoma skeletal metastases and fracture on skeletal scintigraphy-lessons to be learned. *Mol Imaging Radionucl Ther* 2013;22:63-5.