

# Impacts of postoperative changes of segmental mobility on neurological improvement after laminoplasty for cervical ossification of the posterior longitudinal ligament

Atsunori Ohnishi, MD<sup>a,\*</sup>, Hironobu Sakaura, MD, PhD<sup>b</sup>, Yamagishi Akira, MD<sup>c</sup>, Tetsuo Ohwada, MD<sup>c</sup>

## Abstract

Several studies have demonstrated that the dynamic factor at the mobile segment affects the severity of myelopathy in patients with cervical ossification of the posterior longitudinal ligament (C-OPLL), and posterior decompression supplemented with posterior instrumented fusion at the mobile segment provides good neurological improvement. However, there have been few reports of changes in range of motion at the mobile segment (segmental ROM) after laminoplasty (LP). The aim of this study was thus to retrospectively investigate changes in segmental ROM after LP and the impacts of these changes on neurological improvement in patients with C-OPLL.

A total of 51 consecutive patients who underwent LP for C-OPLL since May 2010 and were followed for at least 2 years after surgery were included in this study. Neurological status was assessed using the Japanese Orthopaedic Association (JOA) score before surgery and at 2-year follow-up. Segmental ROM at the responsible level for myelopathy was measured preoperatively and at 2-year follow-up using lateral flexion-extension radiographs of the cervical spine.

The mean JOA score improved significantly from 10.7 points preoperatively to 13.5 points at 2 years after surgery (mean recovery rate, 45.0%). The mean segmental ROM decreased significantly from 6.5 degrees before surgery to 3.2 degrees at 2 years after surgery. In the good clinical outcome group (recovery rate of the JOA score  $\geq 50\%$ ;  $n=22$ ), the mean segmental ROM decreased significantly from 5.8 degrees preoperatively to 3.0 degrees postoperatively. It also decreased significantly from 7.1 degrees to 3.4 degrees in the poor clinical outcome group (recovery rate of the JOA score  $< 50\%$ ;  $n=29$ ).

This study showed that segmental ROM was stabilized after LP in most patients with C-OPLL. Neither preoperative nor postoperative segmental ROM showed significant differences between the good and poor clinical outcome groups and neither a postoperative increase nor decrease of segmental ROM significantly affected the recovery rate of the JOA score.

**Abbreviations:** C-OPLL = cervical ossification of the posterior longitudinal ligament, JOA = Japanese Orthopaedic Association, LP = laminoplasty, ROM = range of motion.

**Keywords:** cervical ossification of the longitudinal ligament, laminoplasty, mobile segment, range of motion

Editor: Hyeun Sung Kim.

The authors have no funding and conflicts of interests to disclose.

The datasets generated during and/or analyzed during the current study are available from the corresponding author on reasonable request.

<sup>a</sup> Department of Orthopaedic Surgery, Osaka National Hospital, Osaka, Japan,

<sup>b</sup> Department of Orthopaedic Surgery, Japan Community Healthcare Organization, Osaka Hospital, Osaka, Japan, <sup>c</sup> Department of Orthopaedic Surgery, Kansai Rosai Hospital, Amagasaki, Hyogo Prefecture, Japan.

\* Correspondence: Atsunori Ohnishi, Department of Orthopaedic Surgery, Osaka National Hospital, 2-1-14 Hoenzaka, Chuo-ku, Osaka, 540-0006, Japan (e-mail: atsunori0915@yahoo.co.jp).

Copyright © 2021 the Author(s). Published by Wolters Kluwer Health, Inc. This is an open access article distributed under the terms of the Creative Commons Attribution-Non Commercial License 4.0 (CCBY-NC), where it is permissible to download, share, remix, transform, and build upon the work provided it is properly cited. The work cannot be used commercially without permission from the journal.

How to cite this article: Ohnishi A, Sakaura H, Akira Y, Ohwada T. Impacts of postoperative changes of segmental mobility on neurological improvement after laminoplasty for cervical ossification of the posterior longitudinal ligament. *Medicine* 2021;100:31(e26807).

Received: 1 April 2021 / Received in final form: 14 June 2021 / Accepted: 13 July 2021

<http://dx.doi.org/10.1097/MD.00000000000026807>

## 1. Introduction

Cervical ossification of the posterior longitudinal ligament (C-OPLL) is a common disease leading to myelopathy, especially in East Asian countries.<sup>[1]</sup> Although laminoplasty (LP) is widely used and provides good surgical outcomes for most patients with progressive myelopathy due to C-OPLL,<sup>[2]</sup> some patients have poor clinical outcomes. Several studies have demonstrated that the dynamic factor at the mobile segment affects the severity of myelopathy in patients with C-OPLL,<sup>[3,4]</sup> and posterior decompression supplemented with posterior instrumented fusion at the mobile segment provides good neurological improvement.<sup>[5]</sup> However, there have been few reports of changes in range of motion at the mobile segment (segmental ROM) after LP. The aim of this study was thus to retrospectively investigate changes in segmental ROM after LP and the impacts of these changes on neurological improvement in patients with C-OPLL.

## 2. Materials and methods

### 2.1. Patients

All patients with C-OPLL at our institute have been treated using LP, with the exception of those with cervical kyphosis  $\geq 15$

degrees and a single-level anterior lesion without a narrow spinal canal. This retrospective study included 51 consecutive patients (41 males and 10 females) who underwent LP for C-OPLL since May 2010 and were followed for at least 2 years after surgery. Their mean age at the time of surgery was 67.9 years (range, 40–89 years). Two surgeons performed only bilateral open-door LP in 30 patients. Four other surgeons performed only unilateral open-door LP in 21 patients. For the first 2 weeks after surgery, all patients wore a soft collar. The protocol of this study was approved by the institutional review board of the hospital, and written, informed consent was obtained from all participants.

## 2.2. Surgical methods

Under general anesthesia, the patients were placed in the prone position. After exposure of the posterior elements, the spinous processes were resected at the base. In bilateral open-door LP, the laminae were cut in half using a high-speed drill. Bone gutters at the medial margin of the facet were created bilaterally to serve as hinges. The remaining halves of the laminae were elevated, and autologous bone grafts and/or hydroxyapatite spacers were installed (Fig. 1). In unilateral open-door LP, bone gutters at the medial margin of the facet were created bilaterally, and the drilling of the gutter on the left side was completed. The laminae were elevated, and hydroxyapatite spacers were installed (Fig. 2).

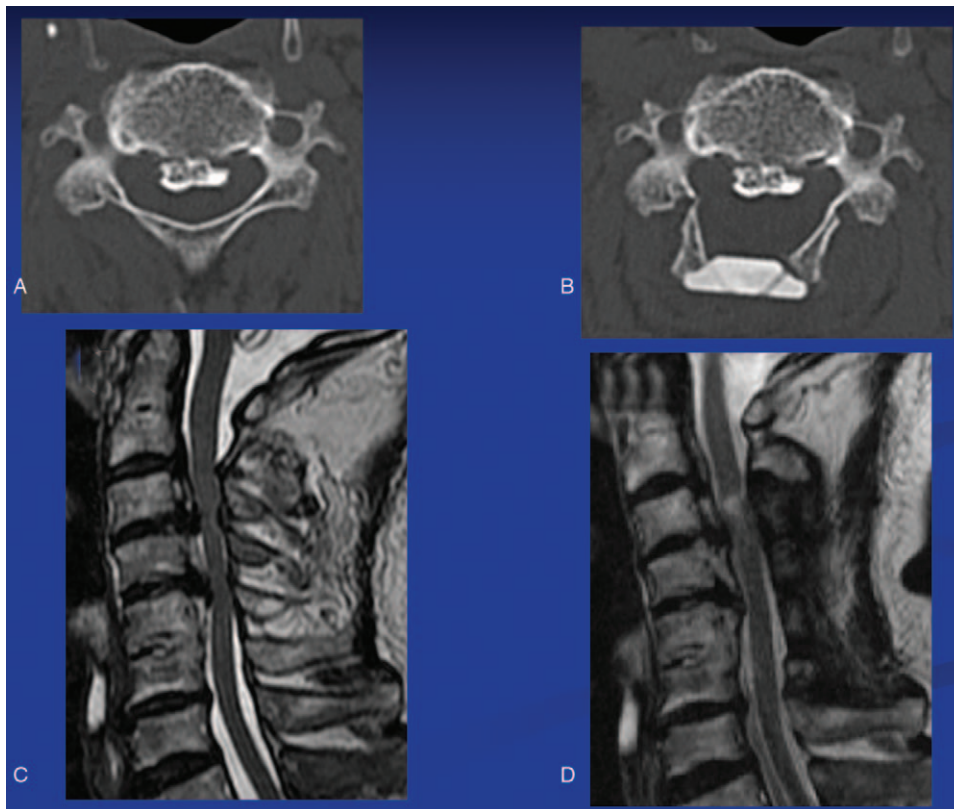
## 2.3. Clinical and radiological evaluations

Neurological status was assessed using the Japanese Orthopaedic Association (JOA) score before surgery and at 2-year follow-up. The recovery rate of the JOA score was calculated by the following formula: The recovery rate of the JOA score (%) = (Postoperative JOA score - Preoperative JOA score) / (17 - Preoperative JOA score) × 100. History of diabetes mellitus, operation time, estimated intraoperative blood loss, and surgery-related complications were also examined.

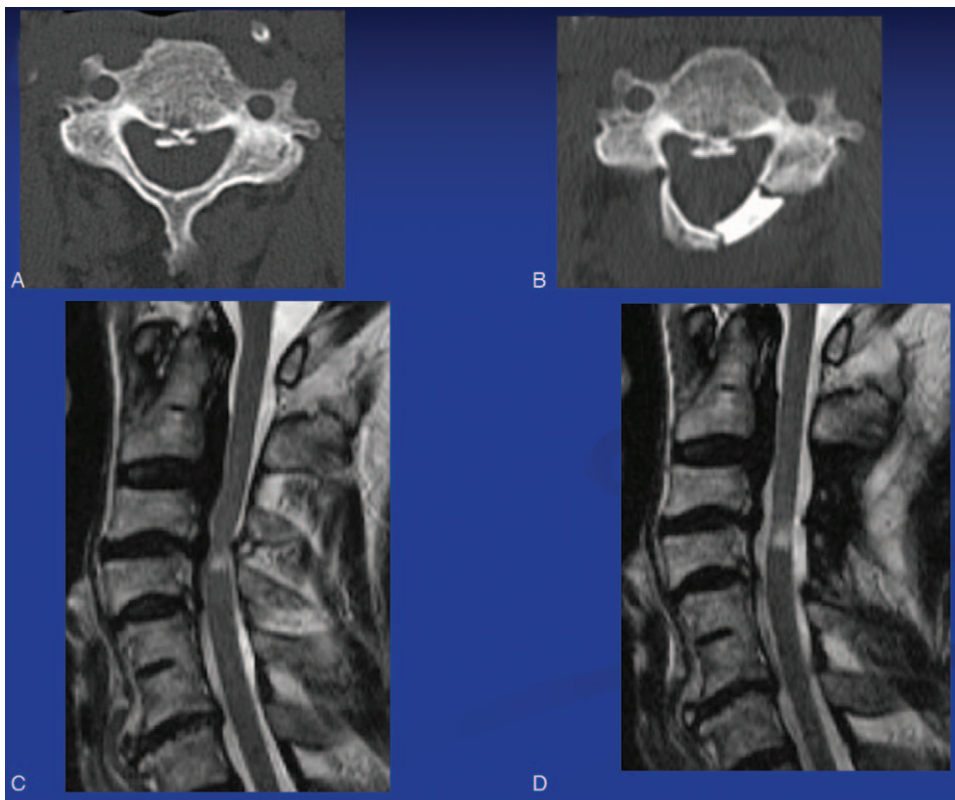
Segmental ROM at the responsible level for myelopathy and C2–7 ROM were measured preoperatively and at 2-year follow-up using lateral flexion-extension radiographs of the cervical spine, as the angle formed by 2 lines drawn parallel to the posterior margin of the vertebral bodies (Fig. 3). The responsible level for myelopathy was comprehensively determined by clinical examinations and the level of the T2 high-intensity lesion on magnetic resonance imaging. Neurological status was assessed by one of the authors, and radiological measurements were performed by the first author.

## 2.4. Statistical analysis

The paired *t*-test, Wilcoxon signed-rank test, the unpaired *t*-test, and the Mann–Whitney U-test were used for statistical analysis with StatMate IV (ATMS Co., Ltd., Tokyo, Japan), as appropriate. Values of  $P < .05$  were considered significant.



**Figure 1.** Computed tomography (CT) and magnetic resonance imaging (MRI) of bilateral open-door laminoplasty. (A) Preoperative CT. (B) CT image after surgery. (C) Preoperative (D) MRI, MRI 4 months after surgery.

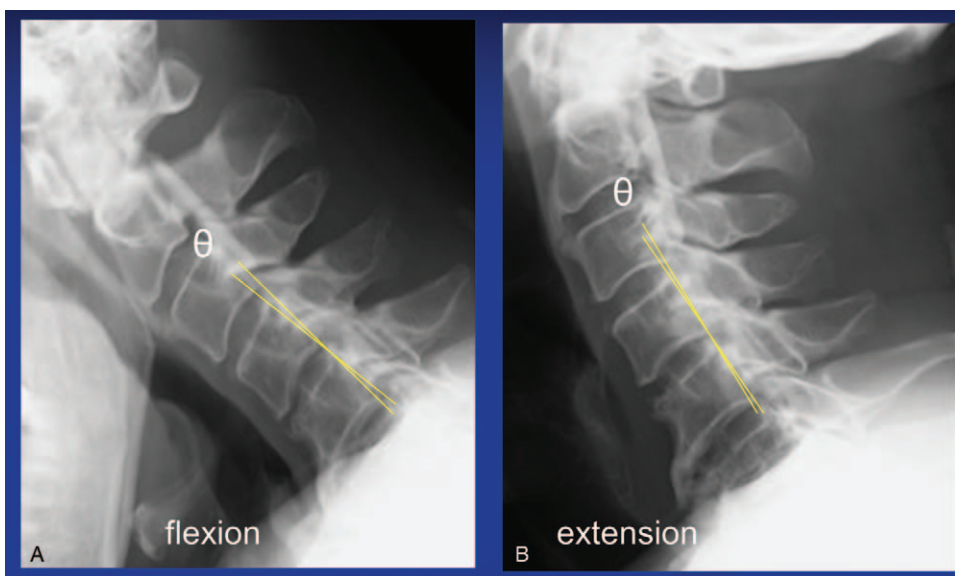


**Figure 2.** Computed tomography (CT) and magnetic resonance imaging (MRI) of unilateral open-door laminoplasty. (A) Preoperative CT. (B) CT image after surgery. (C) Preoperative MRI. (D) MRI 1 year after surgery.

**3. Results**

The level of decompression was C3-C4 in 1 patient, C3-C5 in 1 patient, C3-C6 in 13 patients, C3-C7 in 30 patients, C3-T1 in 2 patients, C3-T2 in 2 patients, and C4-C7 in 2 patients. The

overall mean JOA score improved significantly from 10.7 points before surgery to 13.5 points at 2 years after surgery (mean recovery rate of the JOA score, 45.0%). None of the patients showed neurological deterioration after surgery. The mean



**Figure 3.** Range of motion measured as the change in angle in the flexion and extension positions (A) (B).

**Table 1**  
**Comparison between good and poor clinical outcome groups.**

Variable	Good outcome (n=22)	Poor outcome (n=29)	P value
Mean age at the time of surgery	64.8±11.6	70.2±9.9	.080
Male	26	15	.12
Diabetes mellitus rate	6/22 (27.3%)	7/29 (24.1%)	.80
Operation time	120±29.8	117±28.5	.35
Estimated blood loss	88±78	131±154.	.10
Mean preop JOA score	10.6±2.6	10.7±1.6	.77
Mean postop JOA score	14.9±1.7	12.4±1.4	<.001
Mean recovery rate (%)	70.4±19.2	25.7±15.1	<.001
Mean preop C2–7 ROM	23.5±11.0	25.0±11.2	.64
Mean postop C2–7 ROM	19.1±10.2	16.1±11.5	.33
Mean preop segmental ROM	5.8±4.4	7.1±4.5	.30
Mean postop segmental ROM	3.0±3.1*	3.4±3.3*	.59

Mean±standard deviation, JOA = Japanese Orthopaedic Association, ROM = range of motion.

\*Significantly lower than before surgery (Paired t-test,  $P < .001$ ).

operation time and estimated blood loss were  $118 \pm 29$  minutes and  $112 \pm 128$  mL, respectively. No intraoperative complications occurred. C5 palsy occurred in 1 patient 2 days after surgery, but recovered fully within 1 week.

The mean segmental ROM decreased significantly from 6.5 degrees before surgery to 3.2 degrees at 2 years after surgery, and the mean C2–7 ROM also decreased significantly from 24.4 degrees to 17.4 degrees. Table 1 summarizes the clinical and radiological features of patients in the good clinical outcome group (recovery rate of the JOA score  $\geq 50\%$ ;  $n=22$ ) and the poor clinical outcome group (recovery rate of the JOA score  $< 50\%$ ;  $n=29$ ). In the good clinical outcome group, the mean segmental ROM decreased significantly from 5.8 degrees preoperatively to 3.0 degrees postoperatively. It also decreased significantly from 7.1 degrees to 3.4 degrees in the poor clinical outcome group. Neither preoperative nor postoperative segmental ROM showed significant differences between the 2 groups. On the other hand, the mean recovery rate was 57.4% in the postoperative increase of segmental ROM group ( $n=9$ ) and 42.3% in the postoperative decrease group ( $n=42$ ); the difference was not significant (Table 2).

#### 4. Discussion

In the present study, segmental ROM decreased significantly after LP. To the best of our knowledge, only 1 report in the English literature examined preoperative and postoperative segmental ROM after LP in patients with C-OPLL.<sup>[3]</sup> The authors showed

that segmental ROM at the responsible level for myelopathy decreased from 9.0 degrees before surgery to 5.5 degrees after surgery. Regarding cervical ROM, it is well-known that C2–7 ROM decreases after LP. Hyun et al reported that the mean C2–7 ROM decreased significantly by 31.6% at 2 years after LP compared with the baseline, and they suggested that laminar autofusion was one of the reasons for the loss of ROM.<sup>[6]</sup> Fujimori et al mentioned that the loss of ROM was caused mainly by a decrease in the extension angle and speculated that the restriction of extension had occurred partly as a result of impingement of the opened lamina.<sup>[7]</sup> Other studies also reported that C2–7 ROM could have decreased resulting from unexpected fusion of facet joints and scarring of the cervical extension muscles.<sup>[8,9]</sup> Because of these reasons, segmental ROM, as well as C2–7 ROM, may be decreased after LP.

The indication for posterior instrumented fusion in patients with C-OPLL remains controversial. Several studies showed that the dynamic factor contributed to the development of myelopathy in patients with C-OPLL. A biomechanical analysis demonstrated that, under static compression, the stress distribution increased with the ROM at the responsible level.<sup>[10]</sup> Miyazaki et al showed that preoperative segmental ROM was negatively correlated with the JOA score recovery rate after LP.<sup>[3]</sup> Chen et al reported that the preoperative JOA score was lower with segmental instability than without segmental instability, and lateral mass screw fixation at unstable levels provided better clinical outcomes than LP alone.<sup>[4,5]</sup>

**Table 2**  
**Comparison between postoperative increase and decrease of segmental ROM.**

Variable	Postoperative increase of segmental ROM (n=9)	Postoperative decrease of segmental ROM (n=42)	P value
Mean age at the time of surgery	66.9±10.3	68.1±11.1	.77
Male	7	34	.81
Mean preop JOA score	9.7±2.4	10.9±1.9	.14
Mean postop JOA score	13.9±2.0	13.4±2.0	.48
Mean recovery rate (%)	57.4±26.4	42.3±27.9	.16
Mean preop C2–7 ROM	16.2±8.0	26.1±10.8	.0065
Mean postop C2–7 ROM	16.9±12.9	17.5±10.7	.89
Mean preop segmental ROM	2.1±2.9	7.5±4.2	.00061
Mean postop segmental ROM	4.8±4.3	2.9±2.9	.24

Mean±standard deviation, ROM = range of motion, JOA = Japanese Orthopaedic Association.



In the present study, the overall mean JOA score was significantly improved postoperatively. Segmental ROM decreased significantly both in the good clinical outcome group and the poor clinical outcome group, and neither preoperative nor postoperative segmental ROM showed significant differences between the 2 groups. In addition, neither a postoperative increase nor decrease of segmental ROM significantly affected the recovery rate. Because segmental ROM decreased in most patients after LP without posterior fixation, and postoperative segmental ROM was not related to neurological outcomes, supplementary posterior instrumented fusion at the mobile segment may not be necessary.

The limitations of the present study include the relatively small number of patients. Recently, the K-line, which is a line between the midpoints of the spinal canal at C2 and C7, is widely used for determining the surgical strategy for C-OPLL. The K-line is defined as (-) when the peak OPLL exceeds the K-line, and K-line (-) is considered a factor related to a poor surgical outcome.<sup>[11,12]</sup> However, only 13 patients were classified as K-line (-) in the present study. In addition, there was no posterior fixation group in this study. Another limitation was the short duration of the postoperative follow-up. Furthermore, neck pain scores were not evaluated. A further long-term follow-up study with a larger sample size is needed.

## 5. Conclusions

Segmental ROM decreased significantly after LP. Neither preoperative nor postoperative segmental ROM showed significant differences between the good clinical outcome group and the poor clinical outcome group. In addition, neither a postoperative increase nor decrease of segmental ROM significantly affected the recovery rate. Supplementary posterior instrumented fusion at the mobile segment may not be necessary in patients with C-OPLL.

## Author contributions

**Conceptualization:** Hironobu Sakaura.

**Data curation:** Atsunori Ohnishi.

**Formal analysis:** Atsunori Ohnishi.

**Supervision:** Hironobu Sakaura, Yamagishi Akira, Tetsuo Ohwada.

**Writing – original draft:** Atsunori Ohnishi.

**Writing – review & editing:** Hironobu Sakaura.

## References

- [1] Matsunaga S, Sakou T. Ossification of the posterior longitudinal ligament of the cervical spine: etiology and natural history. *Spine* 2012;37:E309–14.
- [2] Chiba K, Ogawa Y, Ishii K, et al. Long-term results of expansive open-door laminoplasty for cervical myelopathy—average 14-year follow-up study. *Spine* 2006;31:2998–3005.
- [3] Miyazaki M, Ishihara T, Notani N, Kanezaki S, Abe T, Tsumura H. Relationship of preoperative intramedullary MRI signal intensity and dynamic factors with surgical outcomes of laminoplasty for cervical ossification of the posterior longitudinal ligament. *Clin Neurol Neurosurg* 2018;174:117–22.
- [4] Chen Y, Chen D, Wang X, et al. Significance of segmental instability in cervical ossification of the posterior longitudinal ligament and treated by a posterior hybrid technique. *Arch Orthop Trauma Surg* 2013;133:171–7.
- [5] Chen Y, Wang X, Chen D, Miao J, Liao X, Yu F. Posterior hybrid technique for ossification of the posterior longitudinal ligament associated with segmental instability in the cervical spine. *J Spinal Disord Tech* 2014;27:240–4.
- [6] Hyun SJ, Riew KD, Rhim SC. Range of motion loss after cervical laminoplasty: a prospective study with minimum 5-year follow-up data. *Spine J* 2013;13:384–90.
- [7] Fujimori T, Le H, Ziewacz JE, Chou D, Mummaneni PV. Is there a difference in range of motion, neck pain, and outcomes in patients with ossification of posterior longitudinal ligament versus those with cervical spondylosis, treated with plated laminoplasty? *Neurosurg Focus* 2013;35:E9.
- [8] Iizuka H, Nakagawa Y, Shimegi A, et al. Clinical results after cervical laminoplasty: differences due to the duration of wearing a cervical collar. *J Spinal Disord Tech* 2005;18:489–91.
- [9] Seichi A, Takeshita K, Ohishi I, et al. Long-term results of double-door laminoplasty for cervical stenotic myelopathy. *Spine* 2001;26:479–87.
- [10] Nishida N, Kanchiku T, Kato Y, et al. Cervical ossification of the posterior longitudinal ligament: biomechanical analysis of the influence of static and dynamic factors. *J Spinal Cord Med* 2015; 38:593–8.
- [11] Fujiyoshi T, Yamazaki M, Kawabe J, et al. A new concept for making decisions regarding the surgical approach for cervical ossification of the posterior longitudinal ligament: the K-line. *Spine* 2008;33:E990–3.
- [12] Saito J, Maki S, Kamiya K, et al. Outcome of posterior decompression with instrumented fusion surgery for K-line (-) cervical ossification of the longitudinal ligament. *J Clin Neurosci* 2016;32:57–60.