

# Speech intelligibility, nasal resonance, and swallowing ability of maxillectomy patients with customized obturator: A non randomized controlled study

Rohan Grover, Sunit Kumar Jurel, Bhaskar Agarwal, Jitendra Rao, Saumya Kapoor, Niraj Mishra, Balendra Pratap Singh

Department of Prosthodontics, Crown and Bridge, Faculty of Dental Sciences, King George's Medical University, Lucknow, Uttar Pradesh, India

## Abstract

**Aim:** To compare speech intelligibility (SI), nasal resonance, and swallowing ability in maxillectomy patients with a customized obturator to the conventional obturator.

**Settings and Design:** Non-randomized controlled study.

**Materials and Methods:** Forty-eight maxillectomy patients were recruited and assessment of SI, nasal resonance, and swallowing ability was done at three situations: without obturator, with conventional obturator, and with customized obturator. Recordings of unrehearsed conversation, counting from number 1–20 and four sets of Chapel Hill Multilingual Intelligibility Test in the Hindi language were used to assess SI and nasal resonance. SI was evaluated by untrained listeners and graded according to a 6-point scale. Nasal resonance was evaluated by speech pathologists on a 7-point scale of severity. Swallowing ability was evaluated by water drinking test.

**Statistical Analysis Used:** One-way ANOVA, Post hoc Bonferroni and Chi square test.

**Results:** SI and nasal resonance showed a statistically significant difference between any two groups ( $P < 0.001$ ). Water drinking time was significantly different between without obturator and with customized obturator ( $P < 0.001$ ), but the difference was not statistically significant between without obturator and with obturator ( $P < 0.004$ ).

**Conclusion:** SI, nasal resonance, and swallowing ability improved with customized obturator in comparison to the conventional obturator.

**Keywords:** Clinical trial, deglutition, drinking, oral cancer, prosthesis, speech intelligibility

**Address for correspondence:** Dr. Balendra Pratap Singh, Department of Prosthodontics, Crown and Bridge, Faculty of Dental Sciences, King George's Medical University, Lucknow, Uttar Pradesh, India.

E-mail: balendra02@yahoo.com

**Submitted:** 17-Mar-2021, **Revised:** 30-May-2021, **Accepted:** 24-Jun-2021, **Published:** 10-Aug-2021

Access this article online	
Quick Response Code:	Website: www.j-ips.org
	DOI: 10.4103/jips.jips_98_21

This is an open access journal, and articles are distributed under the terms of the Creative Commons Attribution-NonCommercial-ShareAlike 4.0 License, which allows others to remix, tweak, and build upon the work non-commercially, as long as appropriate credit is given and the new creations are licensed under the identical terms.

**For reprints contact:** WKHLRPMedknow\_reprints@wolterskluwer.com

**How to cite this article:** Grover R, Jurel SK, Agarwal B, Rao J, Kapoor S, Mishra N, *et al.* Speech intelligibility, nasal resonance, and swallowing ability of maxillectomy patients with customized obturator: A non randomized controlled study. J Indian Prosthodont Soc 2021;21:249-55.

## INTRODUCTION

Carcinomas involving the maxilla could be a primary tumor or they could invade from adjacent structures.<sup>[1]</sup> In most cases, because of late-onset of symptoms or late diagnosis, management involves hemi-maxillectomy. The resultant defect affects the speech, mastication, facial aesthetics, and psychological health of the patient.<sup>[2]</sup> Rehabilitation of such patients can be done either prosthetically or surgically.

Obturator is a maxillofacial prosthesis that reinstates the integrity of the hard palate and separates the oral cavity from the nasal cavity, maxillary sinus, and orbit<sup>[3]</sup> thereby restoring the compromised oronasal functions. Many studies report an improvement in the quality of life after the use of an obturator.<sup>[3-6]</sup> However, few problems that are often associated with obturator prostheses are hypernasality, deficits in speech, food, and liquids escaping through the nasal cavity, impaired swallowing, and mastication.<sup>[3,7]</sup> It has been observed that among the majority of patients the obturator is not able to restore the speech and swallowing function to the presurgical level.

A modification that improves a patient's swallowing and phonetics is the customization of the palatal surface of a prosthesis with a palatogram.<sup>[8]</sup> A palatogram is a graphic representation of the area of the palate contacted by the tongue during specified activity, usually speech (GPT 9).<sup>[9]</sup>

This study was planned to assess the effect of customized definitive obturator with a palatogram on speech intelligibility (SI), nasal resonance, and swallowing ability in maxillectomy patients. We hypothesized that customizing the palatal contours of the obturator would help in improving the tongue palate contact allowing the tongue to establish contact with the palate in a more habitual and customary position.

## MATERIALS AND METHODS

This study was conducted from April 2014 to October 2018 at a tertiary care medical University in the northern part of India. Ethical approval was taken from the Institutional ethical committee (3698/ethics/R. Cell-14). All patients were asked to sign informed consent as per the Declaration of Helsinki. The sample size for this controlled before-and-after study was calculated to be 48, using 5% as anticipated proportion in the population, level of significance at .05, and absolute precision of 8% in formula  $n = \frac{z^2_{1-\alpha/2} p (1 - p)}{d^2}$ . Patients were recruited in the study before maxillectomy surgery.

Inclusion criteria were:

1. Male and female patients between 18 and 70 years of age
2. Patients scheduled to undergo the maxillectomy surgery
3. Dentate or partially dentate patients
4. Ability to follow the command given during the study

Exclusion criteria were

1. Patients unable to wear obturator postsurgery
2. Recurrence or active malignancy
3. Restricted mouth opening i.e., <15 mm.<sup>[7]</sup>

Seventy-four patients were recruited but twenty-six were excluded due to various reasons before giving definitive obturator [Figure 1]. The remaining forty-eight patients who were fit to wear stable definitive maxillary obturator prosthesis were followed and included 17 females and 31 males. Surgeons were asked to line the reflected cheek flap with split-thickness skin graft after maxillectomy as it improves tolerance and retention of the obturator. It was also advised to keep the bony resection trans-alveolar. Different phases of obturator were given from surgical to interim with soft liner and finally definitive obturator. Definitive obturator was fabricated with open bulb design<sup>[10]</sup> and followed basic prosthodontics principles of removable dental prosthesis in cobalt-chromium alloy. All clinical steps were done by two Prosthodontists having

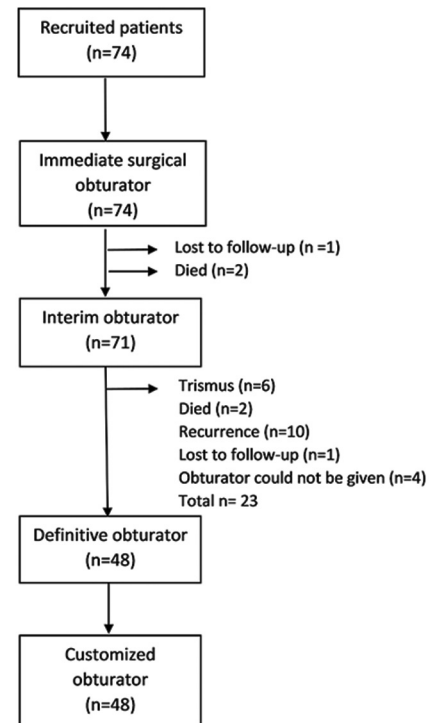


Figure 1: Study flow chart

more than 6 years of experience. When patients were free from postinsertion problems of definitive obturator for at least 3 months, outcomes were assessed. SI, nasal resonance, and swallowing ability were assessed in patients at three situations: without obturator, with conventional definitive obturator, and with customized obturator.

Speech stimuli of patients were recorded with and without definitive obturator, in a noiseless room using a head-mounted omnidirectional microphone (SM 10A, Shure, IL, USA), with the distance of 12 cm between the patient mouth and microphone. Speech recordings included unrehearsed conversation for 30 sec. and arithmetic counting from number 1 to 20, both in the native language and four sets of words from Chapel Hill Multilingual Intelligibility Test (CHMIT) in the Hindi language.<sup>[11]</sup> Recorded samples were randomly edited using personal computer-based analysis audacity software (Open-source software, GNU Public License). The assessment was made by three untrained listeners and three speech-language pathologists experienced in the field of rehabilitation of patients with head and neck cancer for evaluation of SI and nasal resonance.

SI depends on the correct identification of words immediately after listening to the recording. It was evaluated by listeners by grading the recording according to 6-point scale from 1 to 6, score “1” exhibited normal, and “6” exhibited severely impaired speech.<sup>[11]</sup> Nasal resonance was evaluated only by speech pathologists based on 7-point scale of severity given by Darley *et al.*<sup>[12]</sup> where 1 and 7 denote normal to very severe deviation from normal, respectively.

Water drinking test<sup>[13,14]</sup> was performed twice by each patient (with-and-without obturator) to assess swallowing ability. Patient was advised to drink 30 ml of water in a single swallow. The profile of the patient while drinking was categorized in grading as illustrated in Table 1 and the time required for drinking that is from the moment when water was poured into the mouth to when the larynx returned to original position, was recorded with a stopwatch. The behavior and episode during water drinking test were also observed and characterized as illustrated in Table 2. This allowed both quantitative and qualitative assessment of the swallowing ability.

The next phase of the study involved the fabrication of customized obturator with tissue conditioner Tissue conditioner mixed with bio-grade red-colored indicating material (Okklean; DFS Diamon, Germany) was coated on palatal surface, and the patient was instructed to say

“so-so” with mouth widely open.<sup>[16]</sup> Obtained palatogram was compared with palatogram given by normal individual for alphabet “S” [Figure 2]. If the anterior region of the palate was under contoured, it was depicted by uninterrupted, continuous area between the posterior wet region [Figure 3]. Whereas over contoured palate exhibited a wholly wet anterior palatal region [Figure 4]. The region requiring correction was marked with a pencil and the acrylic portion was roughened with a tungsten carbide bur (Waldent Carbide Burs WL-1, India) while cobalt-chromium surface was sandblasted to aid bonding of acrylic to surface. When the marked region was thicker than 2 mm then it was thinned to approximately 2 mm while the surface <2 mm was roughened.

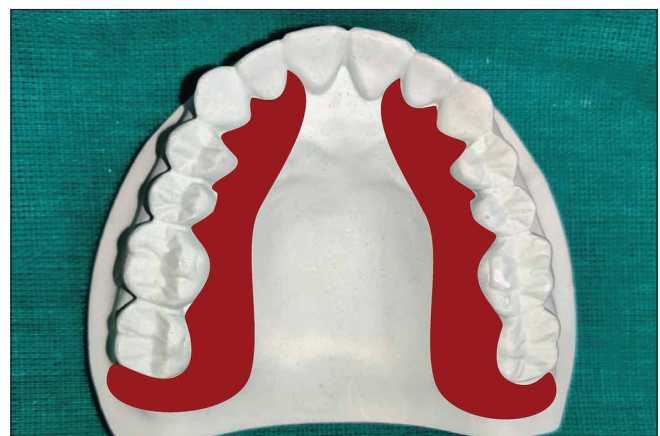Tissue-conditioning material (Super-soft, G. C. America Inc., USA) was prepared to a thick, viscous consistency by adding 25% more powder than instructed by the manufacturer and spread only on the marked area.<sup>[8]</sup>

**Table 1: Categories of the profile of patients according to water drinking test<sup>[15]</sup>**

Profile grading	Characteristic
Normal	In a single swallow and within 5 s water is drunk without cough
Suspected disability	In single or multiple swallow water is drunk without cough but in more than 5 s
Disability	Water is drunk but always accompanied by a cough

**Table 2: Categorization of behavior and episode during water drinking test<sup>[15]</sup>**

Behaviour	Episode
Natural drinking: Able to drink water without a problem	Drooling: Drooling of water from the mouth
Sucking: Sucking water (sip and/or suck in)	Nasal leakage: Leaking of water into the nose
Holding: Holding water in the mouth	
Compulsory drinking: Drinking water compulsorily with unnatural head posture	
Careful drinking: Drinking water carefully	



**Figure 2: “S” Sound palatogram**

Obturator was placed in the patient's mouth and asked to read speech stimuli such as spontaneous conversation, counting, and four sets of words from the CHMIT in the Hindi language, for 5 min but at an increased speaking rate than normal. After initial polymerization of tissue conditioner obturator was removed from patient's mouth and depth of tissue conditioner was assessed with help of periodontal probe (GDC, Punjab, India) which served as guide for accurate palatal contouring. Obturator with tissue conditioning material was then invested in denture processing flask (Denture Flask Varsity Pattern, National Dental Supply Company, Delhi, India) with the area of tissue conditioner was left uncovered in the first pour. After the plaster had completely set, two halves of flasks were separated, and tissue conditioning material was removed. The exposed metal surface which required correction was sandblasted and two coats of metal primer (GC Metal Primer-II, GC America, Inc., Alsip, IL) were applied to ensure chemical bonding of acrylic resin with cobalt-chromium alloy. Autopolymerising repair resin (DPI-RR Cold Cure, DPI, India) was mixed and placed on obturator to replace the tissue conditioner followed by a bench set.<sup>17</sup> After complete polymerization of resin, the obturator was retrieved, finishing and polishing were done. This customized obturator was worn by the patient and speech was recorded and assessed for the third experimental situation.

All speech recordings of three different experimental conditions were presented to listeners in a random manner so that listeners were not aware of recordings being presented. The tests for measuring swallowing ability were also repeated with customized obturator as described previously. Continuous variables were compared by one-way analysis of variance and the significance of mean difference within and between the groups was done by

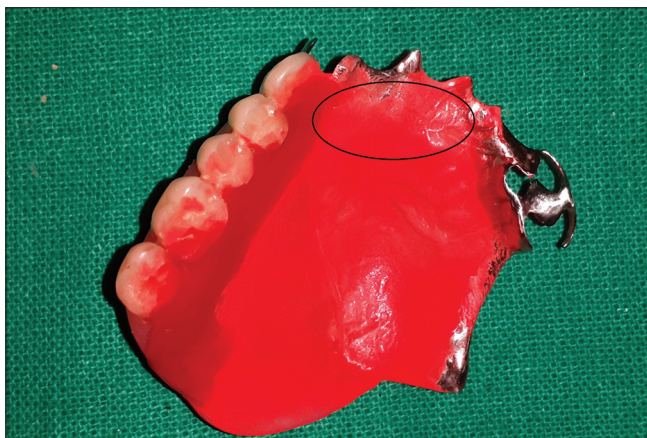
Bonferroni's *post hoc* multiple comparison tests. Categorical variables were compared by Chi-square test.  $P < 0.05$  was considered statistically significant. All analyses were performed on Statistical Packages for the Social Sciences (SPSS) (IBM Corp. Released 2012. IBM SPSS Statistics for Windows, Version 21.0. Armonk, NY: IBM Corp.).

**RESULTS**

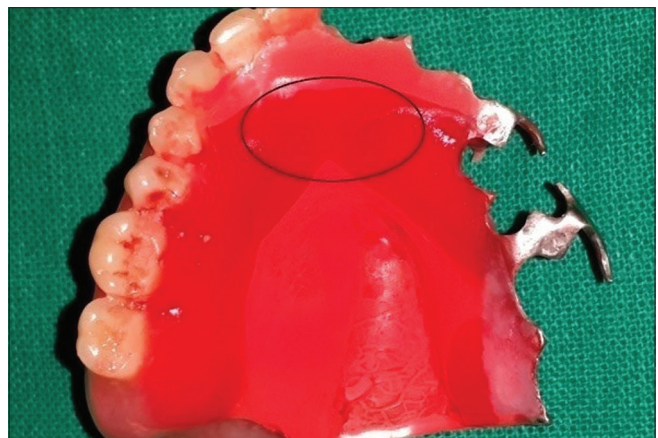
Prevalence of Aramany class II defects was highest (50%) followed by Class I (27.08%). Majority of patients were in the age group 31–40 years (35.45%) and male (64.58%) [Table 3]. Among all recruited patients, most cases (60.41%) were suffering from carcinomas and 25% cases were suffering from tumors, remaining 14.58% had undergone

**Table 3: Sociodemographic, clinical and treatment characteristics of patients**

	Number of patients, n (%)
Age group (years)	
20-30	4 (8.3)
31-40	17 (35.41)
41-50	9 (18.74)
51-60	13 (27.08)
61-70	5 (10.41)
Gender	
Male	31 (64.58)
Female	17 (35.41)
Types of diseases	
Carcinoma	29 (60.41)
Tumor	12 (25)
Infection	7 (14.58)
Radiotherapy status	
Yes	22 (45.83)
No	26 (54.16)
Aramany's classification	
Class I	13 (27.08)
Class II	24 (50.0)
Class III	0
Class IV	4 (8.3)
Class V	2 (4.16)
Class VI	5 (10.41)



**Figure 3:** Region depicting inadequate contact of the anterior palate with the tongue



**Figure 4:** Palatogram showing overcontoured areas of the palate which requires thinning for proper phonetics

maxillectomy due to infections. Among 48 patients included in the present study, 22 patients (45.83%) underwent radiotherapy while 26 patients (54.16%) did not require radiotherapy post maxillary resection.

**Speech intelligibility**

Comparison of SI scores between three groups (measured by untrained and trained listeners-combined) showed a significant difference between any two groups: without obturator and with obturator ( $P < 0.001$ ); without obturator and with customized obturator ( $P < 0.001$ ) and with obturator and with customized obturator ( $P < 0.01$ ) [Table 4].

**Nasal resonance**

Comparison of Nasal Resonance scores among three groups showed significantly different scores between any two groups ( $P < 0.001$ ) [Table 4].

**Water drinking test**

Patients’ profiles during water-drinking test in three groups showed statistically significant improvement between any two group ( $P < .001$ ) [Table 5]. The customized obturator showed a significant reduction in mean drinking time compared to mean drinking time without obturator ( $P < 0.001$ ), but the difference in mean drinking time was not statistically significant between without obturator and with obturator ( $P < 0.004$ ) [Table 4].

Without prosthesis, 41 of 48 patients (85.41%) exhibited “Abnormal” behavior while only seven patients showed

“Normal” drinking behavior. Behavior while water drinking improved significantly ( $P < 0.003$ ) when the prosthesis was in place as eighteen patients (37.5%) showed normal drinking behavior with conventional obturator while thirty patients (62.5%) showed normal drinking behavior with customized obturator [Table 5]. Drooling (22.9%), holding (18.75%), and compulsory drinking (18.75%) were the most common episodes observed when patients were not wearing obturator [Table 5]. With conventional obturator, abnormal episodes reduced significantly ( $P < 0.001$ ) and it was observed that careful drinking (41.66%) and natural drinking (37.5%) were the most commonly occurring episodes while majority patients (62.5%) exhibited natural drinking behavior with the customized obturator.

**DISCUSSION**

Speech is produced by the configuration of various oral structures like teeth, lips, tongue and palate, pharynx, and larynx. When the tongue cannot articulate with the palate due to surgical resection it leads to distortion of sounds. The absence of proper tongue palate contact causes air to escape through the nasal cavity which leads to increased nasalance and misarticulation in the speech, making it unintelligible.

SI assessment in this study revealed the least intelligibility when patients were not wearing obturator. This can be attributed to oronasal communication which alters

**Table 4: Comparison of speech intelligibility scores, nasal resonance scores and water drinking time among three groups (combined score measured by untrained and trained listeners)**

Parameter	Mean±SD			P	Bonferroni's multiple comparison test		
	Without obturator (n=48)	With obturator (n=48)	With customized obturator (n=48)		Without obturator versus with obturator	Without obturator versus with customized obturator	With obturator versus with customized obturator
Speech intelligibility score	4.6±0.3	3.0±0.3	2.7±0.3	<0.001	<0.001	<0.001	<0.01
Nasal resonance	5.3±0.7	2.6±0.8	1.8±0.3	<0.0001	<0.001	<0.001	<0.001
Water drinking time	10.3±4.8	6.7±3.3	5.2±1.5	<0.0001	<0.004	<0.0001	0.468

SD: Standard deviation

**Table 5: Patients’ profile, patient’s behavior, and episodes during the water drinking test in three groups**

Parameter	Profile	Without obturator (n=48), n (%)	With obturator (n=48), n (%)	With coustomized obturator (n=48), n (%)	Pearson $\chi^2$	P
Water drinking test	Normal	4 (8.3)	24 (50)	30 (62.5)	19.27	<0.001
	Suspected disability	31 (64.58)	22 (45.83)	18 (37.5)		
	Disability	13 (27.08)	2 (4.16)	0 (0.0)		
Patient’s behavior during water drinking test	Normal drinking	7 (14.58)	18 (37.5)	30 (62.5)	11.719	<0.003
	Abnormal drinking	41 (85.41)	30 (62.5)	18 (37.5)		
Episodes during the water drinking test	Natural drinking	7 (14.58)	18 (37.5)	30 (62.5)	32.583	<0.001
	Sucking	2 (4.16)	2 (4.16)	0		
	Holding	9 (18.75)	0	2 (4.16)		
	Compulsory drinking	9 (18.75)	6 (12.52)	2 (4.16)		
	Careful drinking	4 (8.3)	20 (41.66)	14 (29.16)		
	Drooling	11 (22.91)	2 (4.16)	0		
	Nasal leakage	6 (12.5)	0	0		

oro-nasal resonance balance, and tongue palatal contacts, thereby reducing SI.<sup>[18]</sup> Factors that can also be attributed to poor intelligibility are velopharyngeal incompetency, size of oronasal communications, and inclusion of soft palate.<sup>[19]</sup> Improvement in SI after wearing both conventional and customized obturator is due to restoration of palatal continuity by obturator, allowing tongue-palate contacts and improving patient's speech.<sup>[20-22]</sup> Customized obturator provided maximum improvement in SI score indicating that customized palatal contours provide more precise tongue palate contact resulting in an overall improvement in SI and nasal resonance.

Nasalance of voice is affected by the coherence of various intra-oral structures known as articulators. If the integrity of these articulators is affected, it influences the resonance of voice.<sup>[7]</sup> After maxillectomy, hypernasality of voice occurs due to escape of air through defect. Prosthetic rehabilitation reduces it to as near to normal levels as possible.<sup>[10]</sup> High values of hypernasality were observed with decrease in SI while a significant reduction in hypernasality was noticed with clear speech (i.e., after use of prosthesis). Implying significant correlation between hypernasality and SI<sup>[12]</sup> because of which there was difficulty in the understanding speech of patients with high values of hypernasality. Comparison of nasal resonance scores in this study was done by trained listeners and it showed a significant difference in three experimental situations.

Kumar *et al.*<sup>[10]</sup> studied articulation and nasalance in patients who after maxillectomy were wearing hollow bulb obturator. They reported articulatory errors, most common being substitution and distortion in dental, dento-alveolar, affricates, and fricatives. The tongue has a customized position with palate to produce sounds, and due to resection of palate, this contact couldn't be established properly. The obturator restored palatal continuity, leading to reduction in distortion and substitution but not complete elimination implying that articulation is dependent on the tongue, hard palate, and their coordination.<sup>[10]</sup> This was in accordance with our study as customized palatal contours provided for more precise tongue palate contact resulting in the overall improvement in SI and nasal resonance. Parameters such as vocal quality, pitch, rhythm, and inflection might have influenced the assessment of hypernasality by listeners. Bohle *et al.*<sup>[23]</sup> and Plank *et al.*<sup>[18]</sup> had reported these parameters of articulation posing difficulty for listeners in differentiating speech resonance parameters from communication variables.

It was also observed that in patients wearing customized obturator, mean drinking time was reduced significantly to

as near to normal, signifying a quantitative improvement in swallowing ability. This was in agreement with Matsuyama *et al.*<sup>[13]</sup> and Jain *et al.*<sup>[8]</sup> who have reported improvement in swallowing ability and speech after customization of the palatal surface by palatogram in denture and in obturator patients, respectively. In this study, drooling, holding and compulsory drinking were the most common episodes observed when the patient was not wearing obturator. With conventional obturator abnormal episodes reduced, and it was observed that careful drinking and natural drinking were the most commonly occurring episodes. Physical closure of oro-nasal communication might have directly affected this improvement of drinking behavior. After wearing customized obturator, majority patients (62.5%) had natural drinking patterns or showed careful drinking (29.10%). This signified a qualitative improvement in the swallowing ability of maxillectomy patients. The study exhibited quantitative and qualitative improvement in the swallowing ability of maxillectomy patients. This improvement in swallowing ability when wearing a customized obturator might contribute to the improved overall function of maxillectomy patients.

Limitations of the study are not evaluating the effect of factors like the extent of surgical defect, radiotherapy, and other adjuvant treatment on outcomes of prosthetic rehabilitation. Swallowing rehabilitation has been evaluated via video-fluorography in head and neck cancer patients.<sup>[24]</sup> However, video-fluorographic evaluation requires a special device and is extremely difficult to carry out chair-side and in regular clinical settings. Therefore, water drinking test was originally developed for dysphagia paralytica in cerebrovascular disease and was also applied in estimating improvement in swallowing ability of maxillectomy patients by Matsuyama *et al.*<sup>[13]</sup> was used in this study.

## CONCLUSION

Within limitations, the present study showed improvement in SI, decreased nasal resonance, and improved swallowing function in patients wearing customized obturators. These improvements can be attributed to palatogram patterns being drawn from these patients and customizing palatal contours of the obturator for each patient.

## Acknowledgment

The authors thank Prof. Vijay Kumar, Department of Surgical Oncology, KGMU, Lucknow for treatment and follow-up related to surgical procedures.

## Financial support and sponsorship

Nil.

**Conflicts of interest**

There are no conflicts of interest.

**REFERENCES**

- Masuda M, Kida Y, Ohtani T. Oral rehabilitation by prosthetic restoration after maxillectomy for malignant tumors. *Int J Oral Surg* 1979;8:356-62.
- Said MM, Otomaru T, Aimaijiang Y, Li N, Taniguchi H. Association between masticatory function and oral health-related quality of life in partial maxillectomy patients. *Int J Prosthodont* 2016;29:561-4.
- Dos Santos DM, de Caxias FP, Bitencourt SB, Turcio KH, Pesqueira AA, Goiato MC. Oral rehabilitation of patients after maxillectomy. A systematic review. *Br J Oral Maxillofac Surg* 2018;56:256-66.
- Srinivasan M, Padmanabhan TV. Rehabilitation of an acquired maxillary defect. *J Indian Prosthodont Soc* 2005;5:155-7.
- Dholam KP, Quazi GA, Bachher GK. Rehabilitation and assessment of speech and mastication in bilateral total maxillectomy patient. *J Indian Prosthodont Soc* 2006;6:206-8.
- Nanda A, Koli D, Sharma S, Suryavanshi S, Verma M. Alleviating speech and deglutition: Role of a prosthodontist in multidisciplinary management of velopharyngeal insufficiency. *J Indian Prosthodont Soc* 2015;15:281-3.
- Mahanna GK, Beukelman DR, Marshall JA, Gaebler CA, Sullivan M. Obturator prostheses after cancer surgery: An approach to speech outcome assessment. *J Prosthet Dent* 1998;79:310-6.
- Jain AR, Venkat Prasad MK, Ariga P. Palatogram revisited. *Contemp Clin Dent* 2014;5:138-41.
- The Glossary of Prosthodontic Terms: Ninth Edition. *J Prosthet Dent* 2017;117:e1-105.
- Kumar P, Jain V, Thakar A. Speech rehabilitation of maxillectomy patients with hollow bulb obturator. *Indian J Palliat Care* 2012;18:207-12.
- de Carvalho-Teles V, Pegoraro-Krook MI, Lauris JR. Speech evaluation with and without palatal obturator in patients submitted to maxillectomy. *J Appl Oral Sci* 2006;14:421-6.
- Darley FL, Aronson AE, Brown JR. Differential diagnostic patterns of dysarthria. *J Speech Hear Res* 1969;12:246-69.
- Matsuyama M, Tsukiyama Y, Koyano K. Objective clinical assessment of change in swallowing ability of maxillectomy patients when wearing obturator prostheses. *Int J Prosthodont* 2005;18:475-9.
- Osawa A, Maeshima S, Tanahashi N. Water-Swallowing Test: Screening for aspiration in stroke patients. *Cerebrovasc Dis* 2013;35:276-81.
- Vero N, Mishra N, Singh BP, Singh K, Jurel SK, Kumar V. Assessment of swallowing and masticatory performance in obturator wearers: A clinical study. *J Adv Prosthodont* 2015;7:8-14.
- Kong HJ, Hansen CA. Customizing palatal contours of a denture to improve speech intelligibility. *J Prosthet Dent* 2008;99:243-8.
- Majid AA, Weinberg B, Chalian VA. Speech intelligibility following prosthetic obturation of surgically acquired maxillary defects. *J Prosthet Dent* 1974;32:87-96.
- Plank DM, Weinberg B, Chalian VA. Evaluation of speech following prosthetic obturation of surgically acquired maxillary defects. *J Prosthet Dent* 1981;45:626-38.
- Yoshida H, Michi K, Ohsawa T. Prosthetic treatment for speech disorders due to surgically acquired maxillary defects. *J Oral Rehabil* 1990;17:565-71.
- Umino S, Masuda G, Ono S, Fujita K. Speech intelligibility following maxillectomy with and without a prosthesis: An analysis of 54 cases. *J Oral Rehabil* 1998;25:153-8.
- Arigbede AO, Dosumu OO, Shaba OP, Esan TA. Evaluation of speech in patients with partial surgically acquired defects: Pre and post prosthetic obturation. *J Contemp Dent Pract* 2006;7:89-96.
- Tobey EA, Lincks J. Acoustic analyses of speech changes after maxillectomy and prosthodontic management. *J Prosthet Dent* 1989;62:449-55.
- Bohle G 3<sup>rd</sup>, Rieger J, Huryn J, Verbel D, Hwang F, Zlotolow I. Efficacy of speech aid prostheses for acquired defects of the soft palate and velopharyngeal inadequacy – clinical assessments and cephalometric analysis: A memorial Sloan-Kettering study. *Head Neck* 2005;27:195-207.
- Cohen EE, LaMonte SJ, Erb NL, Beckman KL, Sadeghi N, Hutcheson KA, *et al.* American Cancer Society head and neck cancer survivorship care guideline. *CA Cancer J Clin* 2016;66:203-39.

**“Quick Response Code” link for full text articles**

The journal issue has a unique new feature for reaching to the journal's website without typing a single letter. Each article on its first page has a “Quick Response Code”. Using any mobile or other hand-held device with camera and GPRS/other internet source, one can reach to the full text of that particular article on the journal's website. Start a QR-code reading software (see list of free applications from <http://tinyurl.com/yzlh2tc>) and point the camera to the QR-code printed in the journal. It will automatically take you to the HTML full text of that article. One can also use a desktop or laptop with web camera for similar functionality. See <http://tinyurl.com/2bw7fn3> or <http://tinyurl.com/3ysr3me> for the free applications.