

Available online at www.sciencedirect.com

journal homepage: www.elsevier.com/locate/radcr

Case report

Cervical longitudinally extensive myelitis after vaccination with inactivated virus-based COVID-19 vaccine [☆]

Mahsa Sepahvand, MD, Narges Yazdi, MD, Mohammad Rohani, MD, Maziar Emamikhah, MD*

Department of Neurology, Rasool Akram Hospital, School of Medicine, Iran University of Medical Sciences, Tehran, Iran

ARTICLE INFO

Article history:

Received 15 October 2021

Revised 21 October 2021

Accepted 24 October 2021

Keywords:

LTEM

COVID-19

Vaccination

Myelitis

Parainfectious

ABSTRACT

Myelitis, including longitudinally extensive transverse myelitis (LTEM), is reported in more than forty patients after coronavirus disease 2019 (COVID-19). Among COVID-19 vaccines, only Oxford-AstraZeneca COVID-19 vaccine (AZD1222) has been associated with few cases of myelitis (1 LTEM). We report the first case of myelitis/LTEM after BBIBP-CorV/Sinopharm vaccine, interestingly presented as a hemicord syndrome. A 71-year-old male presented with left-side diplegia, right-side hemihyposthesia with facial sparing and impaired position sensation in left foot after vaccination with BBIBP-CorV. MRI revealed a longitudinal signal in left cervical hemicord. This is the first reported myelitis and LTEM with COVID-19 vaccines other than AZD1222.

© 2021 The Authors. Published by Elsevier Inc. on behalf of University of Washington.

This is an open access article under the CC BY-NC-ND license

(<http://creativecommons.org/licenses/by-nc-nd/4.0/>)

Introduction

As growing number of people are being vaccinated for COVID-19, more complications regarding these yet-unknown vaccines are emerging. Bell's palsy, Guillain-Barré syndrome, stroke and transverse myelitis are among the most frequently reported neurological complications [1]. A few cases of myelitis have been reported after Oxford-AstraZeneca COVID-19 vaccine (AZD1222), which is a viral vector vaccine [2,3]. Only one of these cases has been a longitudinally extensive myeli-

tis (LTEM) [3]. We present the first case of LTEM after first dose injection of an inactivated virus-based vaccine, BBIBP-CorV.

Case presentation

A 71 years old male presented with left hemiparesis. His weakness developed 5 days after first-dose vaccination with BBIBP-CorV (also known as the Sinopharm COVID-19 vaccine, developed by the Beijing Institute of Biological Products,

[☆] Competing Interests: The authors have declared that no competing interests exist.

* Corresponding author. M. Emamikhah.

E-mail address: maziar.emamikhah@yahoo.com (M. Emamikhah).

<https://doi.org/10.1016/j.radcr.2021.10.053>

1930-0433/© 2021 The Authors. Published by Elsevier Inc. on behalf of University of Washington. This is an open access article under the CC BY-NC-ND license (<http://creativecommons.org/licenses/by-nc-nd/4.0/>)

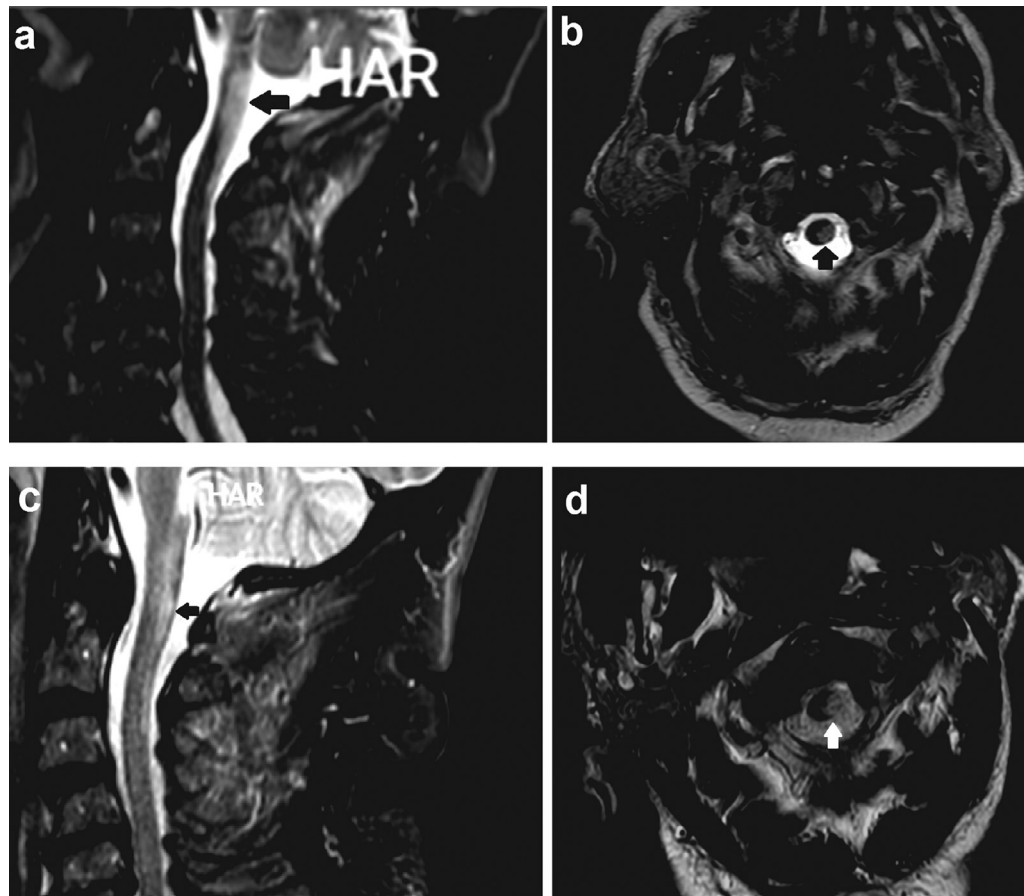


Fig. 1 – Cervical spinal cord T2-weighted MRI, disclosed a longitudinally extensive T2-hyperintense lesion in sagittal view (black arrow in A) without GAD enhancement (not shown here) from cervico-medullary junction to C3 level mostly on the left side of the cord in axial view (black arrow in B). Follow-up imaging after 2 weeks showed partial resolution of cervical spinal lesion in sagittal (black arrow in C) and axial (white arrow in D) views.

Beijing, China), an inactivated virus based vaccine [4], and deteriorated during first day after symptoms onset. He also complained about paresthesia in both hands since 2 days prior to admission. Urinary retention was noticed during the first day at hospital. His past medical history was noticeable for diabetes mellitus, hypertension and Ischemic Heart Disease.

His neurological examination revealed decreased muscle force in left extremities (3/5). His sensory examination disclosed hypoesthesia in right side of the trunk and right extremities. Impaired position and vibration senses as well as Babinski sign were the findings in the left lower limb.

Cervical spinal cord MRI, revealed a longitudinally extensive T2-hyperintense lesion without GAD enhancement from cervico-medullary junction to C3 level predominantly on the left side of the cord (Figs. 1A and B). Brain MRI was unremarkable.

Routine biochemistry and hematology laboratory data along with Serum vitamin B12 and Folate levels, Erythrocyte Sedimentation Rate and C - reactive protein were in normal ranges. Cerebrospinal fluid (CSF) examination revealed normal protein level and glucose without white or red blood

cell. There were no oligoclonal bands. Serum cell-based anti-aquaporin-4 and antimyelin oligodendrocyte (MOG) antibodies were negative. Serologic markers for systemic vasculitis and viral panel as well as CSF HSV PCR showed no abnormalities. SARS-COV-2 RNA PCR nasal swab was negative on 2 different samples, 1 week apart.

Intravenous methylprednisolon 1 gram daily for 6 days was initiated with the impression of postvaccination LETM.

Significant improvement in muscle forces and proprioceptive sensation was evident after 10 days of treatment with corticosteroids. Repeated imaging after 2 weeks showed partial resolution of cervical spinal lesion (Figs. 1C and D).

Discussion

LETM defined as high signal intensity in T2/FLAIR weighted sagittal spinal MRI extending across 3 or more vertebral segments [5] is a catastrophic disabling condition encountered in association with different inflammatory, infection-related

and neoplastic etiologies [5–7]. The most frequently reported etiology associated with LTEM has been neuromyelitis optica (NMO), followed by multiple sclerosis and other inflammatory conditions including parainfectious myelitis which is reported to encompass up to 12% of transverse myelitis and 2% of LTEM patients and typically presents as an acute to subacute myelopathy evolving over few hours or days [6,7]. Some infections have also been mentioned to be the triggering factor for development of LTEM in NMO patients [5]. A closely associated condition to parainfectious myelitis is the postvaccination myelopathy, either isolated or in the setting of acute disseminated encephalomyelitis which may present during the first month after vaccination in 73% of cases [7,8]. This condition is previously reported with H1N1 and yellow fever vaccines [5]. Many cases of COVID-19-related acute myelitis have been reported since the emergence of COVID-19 pandemics, 70% of which have been LTEM [2,8–10]. Occurrence of acute myelitis is reported in a few patients after AZD1222 vaccine and is estimated to occur at an incidence rate of 0.5/million [2,11,12]. To our knowledge, myelitis (including LTEM) after COVID-19 vaccines other than AZD1222 is not reported. Here, we presented the emergence of LTEM with a hemicord syndrome presentation, in a patient 5 days after he had received BBIBP-CorV/Sinopharm vaccine. We investigated and ruled out other possible differential diagnosis including NMO, MOG-associated LTEM, infectious myelitis, collagen vascular disorders, multiple sclerosis and acute disseminated encephalomyelitis [5–7]. The negative COVID-19 PCR testing in CSF is not excluding for inflammatory complications of SARS-CoV2 infection according to the present data in the literature [8]. Dramatic improvement of symptoms and imaging findings after treatment with corticosteroids is supportive for the diagnosis of postvaccination inflammatory LTEM. We should emphasize that this report does not prove the etiological role of the vaccine and the possibility of co-occurrence cannot be ruled out. Moreover, aside from the very benefits of the vaccination, the readers are warned to consider a very higher prevalence of myelitis with the COVID-19 itself compared to the COVID-19 vaccines.

In summary, we emphasize again that the clinicians should be aware of the possibility of development of LTEM after different COVID-19 vaccines. Early diagnosis and prompt treatment is crucial to minimize the sequels of this potentially treatable disabling condition. But the very benefits of vaccines should be considered compared to very rare chance of developing serious complications such as LTEM to prevent unnecessary vaccine phobia.

Patient consent

Informed consent was obtained from the patient.

REFERENCES

- [1] Goss AL, Samudralwar RD, Das RR, Nath A. ANA investigates: neurological complications of COVID-19 vaccines. *Ann Neurol* 2021;89(5):856–7.
- [2] Román GC, Gracia F, Torres A, Palacios A, Gracia K, Harris D. Acute Transverse Myelitis (ATM): clinical review of 43 patients with COVID-19-associated ATM and 3 post-vaccination ATM serious adverse events with the ChAdOx1 nCoV-19 vaccine (AZD1222). *Front Immunol* 2021;12(879).
- [3] Pagenkopf C, Südmeyer M. A case of longitudinally extensive transverse myelitis following vaccination against Covid-19. *J Neuroimmunol* 2021;358:577606.
- [4] Xia S, Zhang Y, Wang Y, Wang H, Yang Y, Gao GF, et al. Safety and immunogenicity of an inactivated SARS-CoV-2 vaccine, BBIBP-CorV: a randomised, double-blind, placebo-controlled, phase 1/2 trial. *Lancet Infect Dis* 2021;21(1):39–51.
- [5] Kitley J, Leite M, George J, Palace J. The differential diagnosis of longitudinally extensive transverse myelitis. *Mult Scler J* 2012;18(3):271–85.
- [6] Pekcevik Y, Mitchell CH, Mealy MA, Orman G, Lee IH, Newsome SD, et al. Differentiating neuromyelitis optica from other causes of longitudinally extensive transverse myelitis on spinal magnetic resonance imaging. *Mult Scler J* 2016;22(3):302–11.
- [7] Mirbagheri S, Sorte DE, Zamora C, Mossa-Basha M, Newsome S, Izbudak I. Evaluation and management of longitudinally extensive transverse myelitis: a guide for radiologists. *Clin Radiol* 2016;71(10):960–71.
- [8] Canavero I, Ravaglia S, Valentino F, Micieli G. Guillain Barré syndrome and myelitis associated with SARS-CoV-2 infection. *Neurosci Lett* 2021;759:136040. doi:10.1016/j.neulet.2021.136040.
- [9] Fumery T, Baudar C, Ossemann M, London F. Longitudinally extensive transverse myelitis following acute COVID-19 infection. *Mult Scler Relat Disord* 2021;48:102723.
- [10] Baghbanian SM, Namazi F. Post COVID-19 longitudinally extensive transverse myelitis (LETM)—a case report. *Acta Neurol Belg* 2021;1875–6. doi:10.1007/s13760-020-01497-x.
- [11] Fitzsimmons W., Nance C.S. Sudden onset of myelitis after COVID-19 vaccination: an under-recognized severe rare adverse event. Available at SSRN 3841558. 2021.
- [12] Malhotra HS, Gupta P, Prabhu V, Garg RK, Dandu H, Agarwal V. COVID-19 vaccination-associated myelitis. *QJM: An International Journal of Medicine* 2021;114(8):591–3. doi:10.1093/qjmed/hcab069.