

# Giant cell myocarditis after first dose of BNT162b2 – a case report

Valentin G. Hirsch<sup>1</sup>, Sven Schallhorn<sup>1</sup>, Carolin Zwadlo<sup>1</sup>, Johanna Diekmann<sup>2</sup>, Florian Länger<sup>3</sup>, Danny David Jonigk<sup>3</sup>, Tibor Kempf<sup>1</sup>, Heinz-Peter Schultheiss<sup>4</sup>, and Johann Bauersachs<sup>1\*</sup>

<sup>1</sup>Department of Cardiology and Angiology, Hannover Medical School, Hannover, Germany; <sup>2</sup>Department of Nuclear Medicine, Hannover Medical School, Hannover, Germany; <sup>3</sup>Institute of Pathology, Hannover Medical School, Hannover, Germany; and <sup>4</sup>Institute of Cardiac Diagnostics and Therapy, IKDT GmbH, Berlin, Germany

Received 3 February 2022; revised 27 May 2022; accepted 19 June 2022; online publish-ahead-of-print 11 July 2022

Herein we report the case of a young man, admitted to the Department of Cardiology and Angiology at Hannover Medical School with shortness of breath and elevated troponin. Few weeks earlier the patient received the first dose of BioNTech's mRNA vaccine (Comirnaty, BNT162b2). After diagnostic work-up revealed giant cell myocarditis, the patient received immunosuppressive therapy. In the present context of myocarditis after mRNA vaccination we discuss this rare aetiology and the patient's treatment strategy in the light of current recommendations.

## Keywords

SARS-CoV-2 vaccine • Giant cell myocarditis • Cardiac magnetic resonance imaging • Endomyocardial biopsy

## Introduction

During the current COVID-19 pandemic, new mRNA vaccines were developed by Moderna and Pfizer/BioNTech and are already widely used. Studies of efficacy and safety showed no significant adverse events or increased prevalence of myocarditis for these vaccines.<sup>1–3</sup> While surveillance continues, an increasing number of reports of myocarditis after mRNA vaccines are published. After 177 million doses of BNT162b2 have been administered in Europe and 296 million in the US until August 2021, the European Medicines Agency's safety committee reports 145 and the Centers for Disease Control and Prevention 323 cases of myocarditis.<sup>4,5</sup> Recent studies revealed 1.76–2.13 cases of myocarditis/100 000 persons (10.69–13.73 in 16–29 years old).<sup>6,7</sup> Here we report and discuss a case of rare giant cell myocarditis (GCM) after the first vaccination dose of BNT162b2. The patient provided written informed consent.

## Case report

### Initial presentation

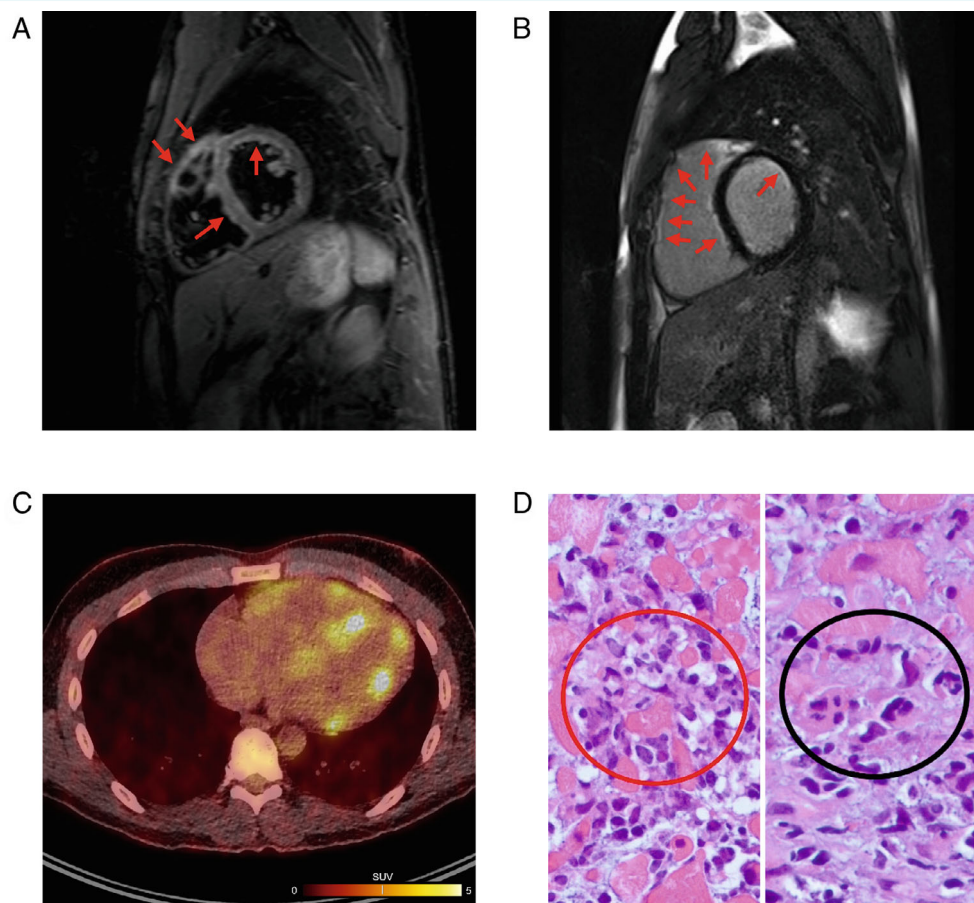
A 32-year-old man (Caucasian) was admitted to the hospital with reduced exercise capacity and shortness of breath (New York

Heart Association class II) after presenting to his general practitioner the same day, who detected elevated levels of troponin T. Symptoms arose approximately 4 weeks earlier and gradually increased over time (graphical timeline shown in online supplementary *Figure S1*). Around the onset of symptoms, he received the first dose of BNT162b2, without experiencing fever, headache, or myalgia. Further, he denied having an episode of upper respiratory tract infection during the last 3 months and used to participate in sports activities multiple times per week.

### Investigations

At the time of admission, the patient's electrocardiogram (ECG) showed a sinus rhythm with a right bundle branch block and without signs of ischaemia (ECG at admission and follow-up, see online supplementary *Figure S2*). A chest X-ray revealed a mildly enlarged heart without further cardiopulmonary abnormalities. The clinical examination remained without pathological findings. Laboratory testing revealed an elevated cardiac troponin T (576 ng/L, reference <14 ng/L), N-terminal pro-B-type natriuretic peptide (NT-proBNP 2483 ng/L, reference <86 ng/L), C-reactive protein (CRP, 89.4 mg/L, reference <5 mg/L) and leucocytosis (11 100/μL, reference 2900–10 200/μL). All other parameters showed normal

\*Corresponding author. Department of Cardiology and Angiology, Hannover Medical School, Carl-Neuberg-Straße 1, 30625 Hannover, Germany. Tel: +49 511 5323841, Email: bauersachs.johann@mh-hannover.de



**Figure 1** Magnetic resonance imaging, positron emission tomography-computed tomography (PET/CT) and endomyocardial biopsy histology. (A) T2-weighted dark-blood imaging of the short axis showing high signal intensity in the subendocardium of the left ventricle as well as right ventricle, a sign of myocardial oedema (arrows). (B) Inversion-recovery images of short-axis view with extensive late gadolinium enhancement (arrows). (C) Fusion PET/CT with biventricular metabolic enhancement. (D) Haematoxylin-eosin staining of endomyocardial biopsy with lymphocytic infiltration (red circle) and myogenic giant cells (black circle) between cardiomyocytes (magnification 1:200).

values. An autoimmune disorder was excluded by widespread testing. Routine PCR testing for SARS-CoV-2, as well as search for other acute viral respiratory infections, remained negative.

Initial transthoracic echocardiography showed a non-dilated left ventricle (end-diastolic diameter [parasternal long-axis view] 5.0 cm, end-diastolic volume [3D Heart model] 181.0 ml) with slightly reduced left ventricular ejection fraction (LVEF 48%, global longitudinal strain  $-20\%$ ) with apical/septal hypokinesia. The right ventricle was dilated and showed reduced function (right ventricular ejection fraction [RVEF] 47%). Valvular or pericardial abnormalities were excluded (sequence of four-chamber view at admission and follow-up, see online supplementary material). Cardiac magnetic resonance imaging (CMR) 3 days after admission confirmed biventricular dysfunction, in particular of the right ventricle (RVEF 28%; LVEF 43%). The anterior and lateral walls of the right ventricle were akinetic as well as the right ventricular outflow tract. Tissue characterization showed subendocardial oedema predominantly in the anterior wall of the left ventricle and in the interventricular septum, as well as in the anterior and lateral wall of the right

ventricle. Late gadolinium enhancement (LGE) presented almost circular subendocardial in the left ventricle and partially transmural in the right ventricle (Figure 1A,B).

An additionally performed positron emission tomography-computed tomography (PET/CT) confirmed an inflammatory-driven metabolic enhancement of both ventricles with mediastinal lymphadenopathy and reactive activated bone marrow (Figure 1C). A no-carb diet was given 24 h prior to PET/CT in order to suppress the physiologic glucose uptake of cardiomyocytes.

The patient underwent coronary angiography, which ruled out coronary artery disease. Further, right heart catheterization excluded pulmonary hypertension and showed normal cardiac index. With high suspicion of myocarditis, at day 6 of admission, endomyocardial biopsies (EMBs) were obtained from the left ventricle. They showed a dense lymphocytic infiltration, including eosinophilic granulocytes, myocyte necrosis and myogenic giant cells without signs of granuloma, so the diagnosis of GCM was made (Figure 1D; larger Field of the biopsy and CD3 staining, see online supplementary Figure S3).

## Initial therapy and short-term course

After diagnosis, the patient immediately received high-dose prednisolone 1000 mg/day for three consecutive days, followed by 1 mg/kg body weight/day. Within a few days NT-proBNP, cardiac troponin T, and CRP significantly decreased. In electrocardiographic telemonitoring one non-sustained, asymptomatic ventricular tachycardia was recorded. The patient continuously showed only mild symptoms and was euvoalaemic. After virus activation in myocardial biopsies was ruled out, we extended the immunosuppressive medication with azathioprine 150 mg/day. Because of the relatively mild clinical heart failure symptoms and only mildly reduced heart function, we did not prescribe additional therapy with cyclosporine. The patient was discharged with a wearable defibrillator (WCD, Zoll). On short-term follow-up high-sensitivity troponin T and CRP dropped further to normal range while NT-proBNP remained elevated at a lower level (602 ng/L).

## Long-term course

Ten weeks later the patient presented with epigastric pain and nausea. Clinical and laboratory evaluation revealed cholestatic hepatitis. As cholestatic hepatitis is a known adverse effect of azathioprine, immunosuppression was changed to mycophenolic acid (1000 mg twice daily) and the patient was discharged after recovery.

Four months after initial diagnosis, CMR and EMB were repeated. CMR showed slightly improved ventricular function (LVEF 50%, RVEF 40%). Subendocardial LGE was unchanged, yet myocardial oedema or hints for active inflammation were no longer traceable. Control EMB revealed immunohistologic decline of inflammation without histological proof of persisting giant cells. Gene expression profile was consistent with persisting GCM. We continued immunosuppression with mycophenolic acid as well as prednisolone tapering and planned readmission in 6 months for reassessment.

## Discussion

Giant cell myocarditis is a rare subtype of myocarditis with a high risk for rapid progressive heart failure, leading frequently to heart transplantation or death.<sup>8</sup> Patients most often present with ventricular arrhythmias and cardiac conduction abnormalities.<sup>9</sup> Diagnosing GCM can be challenging, as it is a rapidly progressive disease and in the early course clinical presentation can be unspecific and subtle. While CMR is the gold standard in the diagnosis of myocarditis, LGE profile can be variable in GCM. Often the EMB is the only method allowing the identification of the underlying aetiology of cardiac inflammation.<sup>10,11</sup> Like in our case, EMB histology was necessary to make the correct and complete diagnosis of GCM and treat the patient accordingly.<sup>12</sup> Gene expression profiling, a diagnostic tool which seems suitable to indicate giant cells even if not histologically detectable by analysis of genes coding for cytokines or chemokines, cellular receptor and proteins involved in mitochondrial energy metabolism, was in addition used to support the diagnosis of GCM and differentiate from cardiac sarcoidosis.<sup>13</sup>

Although our patient had only one asymptomatic non-sustained ventricular tachycardia, described no history of syncope, palpitation, and had only slightly reduced LVEF, we supplied the patient with a WCD as the 5-year incidence of life-threatening ventricular arrhythmias is described with 55% in GCM patients.<sup>14</sup> About 20% of GCM patients have shown underlying autoimmune disease.<sup>8,15</sup> In this case, no hint for any autoimmune disorder was identified, yet the patient's father suffered from a not nearer described myositis without cardiac involvement. We suggest keeping in mind that in myocarditis patients with relevant impaired cardiac function, as well as ventricular arrhythmias or rapid disease progression, additionally to CMR taking EMBs should be considered to correctly diagnose underlying aetiology.

In previously described cases of myocarditis after mRNA vaccination, patients presented within 14 days after the second dose and were most likely young men. Among the 145 European patients with myocarditis, five who died, were described as advanced in years with underlying comorbidities.<sup>4</sup> In Israel one patient died from fulminant myocarditis.<sup>6</sup> In the US 95% of the patients were hospitalized, yet no one died.<sup>5</sup> Overall only in very few cases EMBs were taken, showing no pathological findings in two patients<sup>16,17</sup> and lymphocytic infiltration without giant cells in three patients.<sup>6,7</sup>

In contrast to vaccine-related myocarditis, the SARS-CoV-2 infection is frequently accompanied by acute cardiac damage.<sup>18</sup> Discussed factors are disturbed angiotensin-converting enzyme 2 signalling, systemic inflammatory damage, cardiometabolic effects, arrhythmias, and ischaemia.<sup>19,20</sup> Here we can only describe a temporal relationship of vaccination and the occurrence of GCM, but no verifiable causal relation. Yet, this case is in line with one recently published case report showing GCM after second vaccination dose of BNT162b2 and another report of fulminant heart failure with heart transplantation after heterologous vaccination of ChAdOx1 nCoV-19 and BNT162b2.<sup>21,22</sup>

Eventually, we encouraged the patient to receive the following vaccination doses with BNT162b2, which were tolerated under ongoing immunosuppressive therapy without any notable adverse events or heart failure aggravation.

## Supplementary Information

Additional supporting information may be found online in the Supporting Information section at the end of the article.

## Acknowledgement

Open Access funding enabled and organized by Projekt DEAL.

**Conflict of interest:** none declared.

## References

1. Baden LR, el Sahly HM, Essink B, Kotloff K, Frey S, Novak R, et al.; COVE Study Group. Efficacy and safety of the mRNA-1273 SARS-CoV-2 vaccine. *N Engl J Med.* 2021;**384**:403–16.
2. Polack FP, Thomas SJ, Kitchin N, Absalon J, Gurtman A, Lockhart S, et al.; C4591001 Clinical Trial Group. Safety and efficacy of the BNT162b2 mRNA Covid-19 vaccine. *N Engl J Med.* 2020;**383**:2603–15.
3. Walsh EE, Frenck RW Jr, Falsey AR, Kitchin N, Absalon J, Gurtman A, et al. Safety and immunogenicity of two RNA-based Covid-19 vaccine candidates. *N Engl J Med.* 2020;**383**:2439–50.

4. European Medicines Agency. Comirnaty and Spikevax: possible link to very rare cases of myocarditis and pericarditis. 9 July 2021. <https://www.ema.europa.eu/en/news/comirnaty-spikevax-possible-link-very-rare-cases-myocarditis-pericarditis> (30 June 2022).
5. Gargano JW, Wallace M, Hadler SC, Langley G, Su JR, Oster ME, et al. Use of mRNA COVID-19 vaccine after reports of myocarditis among vaccine recipients: update from the Advisory Committee on Immunization Practices – United States, June 2021. *MMWR Morb Mortal Wkly Rep.* 2021;**70**:977–82.
6. Mevorach D, Anis E, Cedar N, Bromberg M, Haas EJ, Nadir E, et al. Myocarditis after BNT162b2 mRNA vaccine against Covid-19 in Israel. *N Engl J Med.* 2021;**385**:2140–9.
7. Witberg G, Barda N, Hoss S, Richter I, Wiessman M, Aviv Y, et al. Myocarditis after Covid-19 vaccination in a large health care organization. *N Engl J Med.* 2021;**385**:2132–9.
8. Cooper LT Jr, Berry GJ, Shabetai R. Idiopathic giant-cell myocarditis – natural history and treatment. Multicenter Giant Cell Myocarditis Study Group Investigators. *N Engl J Med.* 1997;**336**:1860–6.
9. Cooper LT Jr. Myocarditis. *N Engl J Med.* 2009;**360**:1526–38.
10. Yang S, Chen X, Li J, Sun Y, Song J, Wang H, et al. Late gadolinium enhancement characteristics in giant cell myocarditis. *ESC Heart Fail.* 2021;**8**:2320–7.
11. Tschope C, Ammirati E, Bozkurt B, ALP C, Cooper LT, Felix SB, et al. Myocarditis and inflammatory cardiomyopathy: current evidence and future directions. *Nat Rev Cardiol.* 2021;**18**:169–93.
12. Escher F, Pietsch H, Aleshcheva G, Wenzel P, Fruhwald F, Stumpf C, et al. Evaluation of myocardial gene expression profiling for superior diagnosis of idiopathic giant-cell myocarditis and clinical feasibility in a large cohort of patients with acute cardiac decompensation. *J Clin Med.* 2020;**9**:2689.
13. Lassner D, Kuhl U, Siegismund CS, Rohde M, Elez куртaj S, Escher F, et al. Improved diagnosis of idiopathic giant cell myocarditis and cardiac sarcoidosis by myocardial gene expression profiling. *Eur Heart J.* 2014;**35**:2186–95.
14. Ekstrom K, Lehtonen J, Kandolin R, Räisänen-Sokolowski A, Salmenkivi K, Kupari M. Incidence, risk factors, and outcome of life-threatening ventricular arrhythmias in giant cell myocarditis. *Circ Arrhythm Electrophysiol.* 2016;**9**:e004559.
15. Rosenstein ED, Zucker MJ, Kramer N. Giant cell myocarditis: most fatal of autoimmune diseases. *Semin Arthritis Rheum.* 2000;**30**:1–16.
16. Larson KF, Ammirati E, Adler ED, Cooper LT Jr, Hong KN, Saponara G, et al. Myocarditis after BNT162b2 and mRNA-1273 vaccination. *Circulation.* 2021;**144**:506–8.
17. Rosner CM, Genovese L, Tehrani BN, Atkins M, Bakhshi H, Chaudhri S, et al. Myocarditis temporally associated with COVID-19 vaccination. *Circulation.* 2021;**144**:502–5.
18. Libby P. The heart in COVID-19: primary target or secondary bystander? *JACC Basic Transl Sci.* 2020;**5**:537–42.
19. Siddiqi HK, Libby P, Ridker PM. COVID-19 – a vascular disease. *Trends Cardiovasc Med.* 2021;**31**:1–5.
20. Schultheiss HP, Baumeier C, Pietsch H, Bock CT, Poller W, Escher F. Cardiovascular consequences of viral infections: from COVID to other viral diseases. *Cardiovasc Res.* 2021;**117**:2610–23.
21. Sung K, McCain J, King KR, Hong K, Aisagbonhi O, Adler ED, et al. Biopsy-proven giant cell myocarditis following the COVID-19 vaccine. *Circ Heart Fail.* 2022;**15**:e009321.
22. Kang DH, Na JY, Yang JH, Moon SH, Kim SH, Jung JJ, et al. Fulminant giant cell myocarditis following heterologous vaccination of ChAdOx1 nCoV-19 and Pfizer-BioNTech COVID-19. *Medicina (Kaunas).* 2022;**58**:449.